HAND-BOOK
OF
ANATOMY
YOUNG

QM28 Y8
1917
cop. 1

Columbia University
in the City of New York
College of Physicians and Surgeons

Reference Library

HANDBOOK

OF

ANATOMY

BEING A

COMPLETE COMPEND OF ANATOMY

INCLUDING THE ANATOMY OF THE VISCERA, A CHAPTER ON DENTAL ANATOMY, NUMEROUS TABLES, AND INCORPORATING THE NEWER NOMENCLATURE ADOPTED BY THE GERMAN ANATOMICAL SOCIETY, GENERALLY DESIGNATED THE BASLE NOMENCLATURE, OR BNA.

BY

JAMES K. YOUNG, M.D., F.A.C.S.

Professor of Orthopædic Surgery, Philadelphia Polyclinic; Associate Professor of Orthopædic Surgery, University of Pennsylvania; Orthopædic Surgeon to the Philadelphia General Hospital; Fellow of the College of Physicians, of Philadelphia; Fellow of the Philadelphia Academy of Surgery; Fellow of the American Orthopædic Association; Member of the American Medical Association, etc., etc.

FIFTH EDITION, REVISED AND ENLARGED

WITH 154 ENGRAVINGS, SOME IN COLORS

PHILADELPHIA

F. A. DAVIS COMPANY, PUBLISHERS

ENGLISH DEPOT

STANLEY PHILLIPS, LONDON

1918

COPYRIGHT, 1889
COPYRIGHT, 1905
COPYRIGHT, 1909
COPYRIGHT, 1913
COPYRIGHT, 1917
BY
F. A. DAVIS COMPANY

Copyright, Great Britain. All Rights Reserved

Philadelphia, Pa., U. S. A.
Press of F. A. Davis Company
1914-1916 Cherry Street

PREFACE TO FIFTH EDITION.

The demand for a new edition of the author's Handbook of Anatomy has afforded him an opportunity to revise certain portions of the volume, made necessary by recent advances in anatomical studies since the publication of the fourth edition.

In order to enhance still further any value that the work may possess, there have been some eliminations, many alterations and a large number of additions. These changes, together with the replacement of the older cuts in the chapter on Osteology by clearer and far superior illustrations, that comprised an osteological atlas in former editions, necessitated a recasting of the entire book.

A special chapter devoted to Dental Anatomy, comprising the Anatomy of the Face, Teeth and Jaws, properly illustrated, has been prepared by Joseph L. Appleton, Jr., B.S., D.D.S., of The Thomas W. Evans Museum and Institute of Dentistry, University of Pennsylvania.

In order to make the work thoroughly accurate and modern, it was deemed advisable to incorporate throughout the volume the Basle nomenclature or BNA as formulated and adopted by the German Anatomical Society. Each anatomical name has been critically examined and its BNA equivalent added. This is, perhaps, the only medium-sized anatomical work that fully includes the newer terminology.

This arduous labor has been successfully prosecuted by Dr. Samuel Lewald, medical and historical writer, without whose valuable assistance this portion of the work could not have been accomplished.

The author trusts that these numerous changes will meet with the approval of professors and teachers in the leading medical and dental colleges, and that it may appeal to the student body in general, for whom this labor has been undertaken.

J. K. Y.

222 So. Sixteenth Street.

PREFACE TO FOURTH EDITION.

Although for over twenty years the book has been in constant use by large numbers of students and approved by professors and teachers in leading medical colleges and in Nurses' Training Schools generally, comparatively few errors or omissions of importance have been discovered; but in the present edition these have all been noted and corrected. The appreciative thanks of the author are extended to Dr. A. C. Pole, of Baltimore, for several pertinent suggestions in the preparation of this edition.

J. K. Y.

PREFACE TO THIRD EDITION.

In the preparation of this new edition, the author has taken advantage of the opportunity to correct the few clerical errors which must necessarily be found in a comprehensive though condensed work upon Anatomy, and to make such changes as have become necessary through the advances of the science since the publication of the last edition.

In the section upon the Nervous System the greatest changes will be found, the first part having been rewritten.

In the description of the Muscular System, the regional grouping has been retained, because it is more practical for the student.

Attention is directed to the original colored plates of the Arterial System which offer the most complete classification of all the arteries in the smallest space, and also to the original diagrams of the sensory tracts from spinal cord to brain, and the motor tracts from brain to spinal cord.

The author desires to express his gratitude to the student body of America for their continued confidence in this early literary effort of his, and express the hope that the present edition may be as well received as the others.

J. K. Y.

PREFACE TO SECOND EDITION.

The demand for a new edition has afforded an opportunity to thoroughly revise the text and illustrations, and to add such changes of description and nomenclature as have been introduced into modern methods of teaching.

Whenever it seemed necessary or advisable sections have been entirely rewritten, but the same attention to conciseness and accuracy has been observed as in the former edition.

The size of the pages has been considerably enlarged and increased in number, and the illustrations increased from 76 to 171. Many improved cuts replace those used in the former edition and full-page engraved plates have been inserted in the text where they will be most serviceable.

In its preparation, the last editions of both Morris and Gray have been freely consulted, so that it can be used with either of these standard works.

As in the former edition, although prepared particularly for students, sufficient descriptive matter has been added to render it valuable to the busy practitioner, particularly in the sections upon the Viscera, Special Senses, Vascular System, the Nervous System, and Surgical Anatomy.

Special attention has been given to the anatomy of the brain and nervous system, which will be found to compare favorably with the descriptions in larger works.

The author has been much gratified to observe the tenacity with which students and physicians have retained the work for reference.

The author would acknowledge his obligation to Dr. Richard F. Gerlach, who has distinguished himself by his careful and accurate work upon Deaver's "Surgical Anatomy," for valuable assistance upon the revision.

J. K. Y.

PREFACE TO FIRST EDITION.

The object of this little book is, as its title indicates, to furnish a concise though *complete synopsis* of human anatomy for the use of students of medicine and others.

Appreciating, from a personal contact with students, the limited time at their disposal and the unlimited amount of medical material to be digested, the author has endeavored, by well-selected wood-cuts, typographical arrangement, and numerous tables, to facilitate the acquisition of a subject as difficult as it is essential, and elegance of diction has therefore been sacrificed to conciseness and accuracy.

In its preparation the last edition of Gray's "Anatomy" [edited by Keen], as the work most largely employed, has been selected as the *standard*, but Leidy, Quain, Allen, Holden, Henle, Schaffer, Klein, Brown Aids, and others, have been freely used, and on the special subjects Lusk, Spiegelberg, Savage, Schroeder, Budin, Treve's "Surgical Applied Anatomy," and the "American System of Dentistry" have been consulted. Although prepared particularly for students, sufficient descriptive matter has been added to render it valuable to the busy practitioner, particularly the sections on the Viscera, Special Senses, Vascular System, and Surgical Anatomy. The aim throughout has been to make it as thoroughly complete and accurate as possible, and at the same time readily accessible for reference or study.

The writer would acknowledge his obligations to Messrs. S. Z. Durborow and C. W. Holly, medical students at the University, for assistance in the correction of proof.

J. K. Y.

CONTENTS.

PAGE

INTRODUCTORY 1
OSTEOLOGY 3
The Frontal Bone 8
Parietals 10
The Occipital Bone 12
Temporals 15
The Sphenoid 20
The Ethmoid 24
The Lachrymal 26
The Malar 27
The Superior Maxilla 29
Palate Bones 32
The Inferior Turbinated Bones 34
The Vomer 35
The Inferior Maxilla 35
The Sutures and Fontanelles 39
Fossæ of Skull 40
The Orbits 42
Foramina at the Base of the Skull 46
The Sternum 52
The Ribs 52
The Spine 56
The Upper Extremity 63
The Arm 70
The Forearm 72
The Hand 76
The Lower Extremity 81
The Thigh 86
The Patella 89
The Leg 90
The Foot 93
Table of Ossification 99
ARTICULATIONS AND LIGAMENTS 104
The Thorax 109
The Pelvis 112

PAGE

The Muscular System 128
Muscles of the Head 129
Muscles of the Neck 133
Vertebral Region 136
Muscles of the Back 138
Muscles of the Abdomen 143
Muscles of the Upper Extremity 147
Muscles of the Forearm 149
Muscles of the Hand 153
Muscles of the Lower Extremity 155
Muscles of the Leg 160
Muscles of the Foot 163
The Fascias 165
The Heart and Vascular System 170
The Circulation of the Blood 176
The Arterial System 178
Table of the Arterial System 202
The Venous System 209
The Lymphatic System 218
The Alimentary Apparatus 223
The Teeth 224
The Pharynx 230
The Œsophagus 231
The Abdomen 232
The Peritoneum 235
The Stomach 238
The Small Intestine 240
The Large Intestine 242
The Pancreas 245
The Liver 246
The Ductless Glands 250
Vocal and Respiratory Apparatus 254
The Larynx 254
The Trachea and Bronchi 259
The Lungs 261
The Pleuræ 264
The Mediastinum 264
The Genito-Urinary Apparatus 266
The Kidneys 266
The Bladder 270
Male Organs 273
Female Organs 283
The Mammary Gland 292

PAGE

THE NERVOUS SYSTEM 294
The Brain 298
The Cranial Nerves 323
The Spinal Cord 332
The Spinal Nerves 332
Table of Spinal Nerves 343
The Sympathetic Nervous System 350
ORGANS OF SPECIAL SENSE 355
The Nose 355
The Eye 356
Appendages of the Eye 372
The Ear 375
The Tongue 388
The Skin and Appendages 389
SURGICAL ANATOMY 391
Triangles of the Neck 391
Triangle in Front of Elbow-joint 394
Scarpa's Triangle 394
Axilla 395
Anatomy of Hernia 396
Ischio-rectal Region and Perineum 402
Anatomy of Lateral Lithotomy 407
DENTAL ANATOMY 409

INDEX 423

ILLUSTRATIONS.

FIG.		PAGE
1.	Frontal bone, outer surface	7
2.	Frontal bone, inner surface	9
3.	Parietal bone, outer surface	10
4.	Parietal bone, inner surface	11
5.	Occipital bone, outer surface	12
6.	Occipital bone, inner surface	13
7.	Left temporal bone, outer surface	15
8.	Left temporal bone, inner surface	16
9.	Left temporal bone, inferior surface of the petrous portion	17
10.	Section of the temporal bone through the middle ear, etc.	19
11.	Sphenoid bone, upper surface	21
12.	Sphenoid bone, anterior surface	22
13.	Ethmoid bone	25
14.	Lachrymal bone	26
15.	Nasal bone	27
16.	Malar bones	28
17.	Superior maxillary bone	29
18.	Superior maxillary, inner surface	30
19.	Palate bone (viewed posteriorly)	32
20.	Palate bone (inner surface)	32
21.	Inferior turbinated bones	34
22.	Vomer	35
23.	Inferior maxillary bone	36
24.	Left half of inferior maxillary bone, inner surface	37
25.	The hyoid bone	38
26.	Fossæ of skull	41
27.	Facial portion of skull	43
28.	Nasal meatuses	45
29.	Base of skull, external surface	47
30.	Floor of the cranium	49
31.	Sternum and costal cartilages	51
32.	The peculiar ribs	53
33.	The vertebral column, or spine	55
34.	A dorsal vertebra	56
35.	A cervical vertebra	57
36.	The atlas	57
37.	The axis	58
38.	Seventh cervical, or vertebra prominens	58
39.	Peculiar dorsal vertebræ	59
40.	A lumbar vertebra	60
41.	The sacrum, anterior surface	61
42.	The sacrum, posterior surface	62
43.	The left clavicle, upper surface	64
44.	The left clavicle, under surface	65
45.	The scapula, anterior surface	66
46.	The scapula, posterior surface	67
47.	The humerus, anterior surface	69
48.	The humerus, posterior surface	69
49.	Ulna and radius, anterior aspect	73
50.	Radius and ulna, posterior aspect	75
51.	Carpus, metacarpus, and phalanges, dorsal surface	77
52.	Carpus, metacarpus, and phalanges, palmar surface	79
53.	Os innominatum, outer surface	82
54.	Os innominatum, inner surface	83
55.	The femur, anterior surface	87
56.	The femur, posterior surface	87
57.	The tibia and fibula, anterior surface	91
58.	The tibia and fibula, posterior surface	91
59.	The tarsus, metatarsus, and phalanges, dorsal surface	95
60.	The tarsus, metatarsus, and phalanges, plantar surface	97

FIG.		PAGE
61.	The thorax	111
62.	The pelvis	112
63.	The shoulder	115
64.	The elbow	117
65.	The knee	123
66.	The knee	123
67.	Muscles of the back	139
68.	Muscles of the abdomen	144
69.	The diaphragm	145
70.	Muscles of the shoulder and arm	149
71.	Triceps muscles	149
72.	Posterior superficial muscles of the forearm	151
73.	Muscles of the anterior femoral region	157
74.	Muscles of the posterior femoral region	157
75.	Anterior muscles of the leg	161
76.	Posterior muscles of the leg	161
77.	Right side of heart	171
78.	Diagram of the fœtal circulation	177
79.	Arteries of the face	182
80.	Internal maxillary artery	184
81.	The arteries of the head and neck. (*Colored*)	Facing 184
82.	The arteries of the upper extremity. (*Colored*)	Facing 186
83.	Abdominal aorta	195
84.	The arteries of the trunk. (*Colored*)	Facing 196
85.	The arteries of the lower extremity. (*Colored*)	Facing 198
86.	Temporary teeth	226
87.	Permanent teeth	227
88.	Pharynx, laid open from behind	231
89.	Regions of the abdomen	232
90.	Abdominal viscera	235
91.	The peritoneum	236
92.	The liver	247
93.	Transverse section of lobules of liver	248
94.	Vertical section of larynx	256
95.	Heart and lungs	263
96.	Longitudinal section of kidney	267
97.	Diagram of the course of the uriniferous tubules	269
98.	Male organs of generation	275
99.	The testicles and epididymis	277
100.	Vertical section of testicle	279
101.	Internal female genitals	283
102.	Female organs of generation	285
103.	Section of an ovary	287
104.	External female genitals	289
105.	Surface anatomy of the myelencephalon	300
106.	Left side of human cerebrum	303
107.	Convolutions and fissures of the median and tentorial surfaces of the right cerebral hemisphere	305
108.	Inferior aspect of cerebral hemisphere	307
109.	The lateral ventricles and choroid plexus	309
110.	Mesial section of brain and brain stem	313
111.	Interior of mesencephalon	317
112.	Diagram of sensory tracts from spinal cord to brain	319
113.	Diagram of motor tracts from brain to spinal cord	321
114.	Scheme of the nuclei and root-fibers of the cranial nerves	323
115.	Base of brain and cranial nerves	324
116.	Optic, oculomotor, trachlear, and trifacial nerves	Facing 324
117.	Facial and auditory nerves	327
118.	Glossopharyngeal, pneumogastric, spinal accessory, and hypoglossal nerves	329
119.	Cervical plexus and branches	333
120.	Section of the spinal cord and membranes	334
121.	Brachial plexus and branches	335
122.	Lumbar plexus and branches	Facing 338
123.	Sacral plexus and branches	Facing 342
124.	The sympathetic system	Facing 350
125.	The olfactory nerves and nerves of common sensation to the nose	355
126.	Nasal meatuses and accessory cavities	357
127.	Inner wall of orbit and adjacent parts	358
128.	Horizontal section of right orbit	359
129.	Anteroposterior section of eyeball	360
130.	Vessels of the eye	363

FIG.		PAGE
131.	The structure of the human retina	365
132.	Diagram of the retinal vessels	366
133.	The orbital muscles	370
134.	The ophthalmic artery and branches	371
135.	The lachrymal apparatus	374
136.	External, middle, and internal ear	377
137.	The auditory ossicles	381
138.	Organ of corti	384
139.	Triangles of the neck	393
140.	The axilla	395
141.	Dissection of the inguinal canal	397
142.	Deep femoral region—the femoral vessels, etc. (*McGrath*)	399
143.	Male perineum, superficial dissection	402
144.	Male perineum, deep dissection	403
145.	Female perineum	405
146.	Maxillary and mandibular process of first visceral arch and fronto-nasal process	409
147.	Sutures of the hard palate	410
148.	Four mandibles ranging from birth to eighteen months	411
149.	Muscles of expression	412
150.	Tooth development	413
151.	Tooth development	414
152.	Root growth	417
153.	Occlusal surfaces of teeth	420
154.	Cross section through roots of teeth *in situ*	421
	Chart of cranial nerves ..... Facing	422

INTRODUCTORY.

The term "anatomy," derived from the Greek ἀνά, "through," and τέμνεω, "to cut," signifies dissection, but has been appropriated under the general term Morphology, to the science which treats of the apparent properties of organized bodies. It is the science of organization and of form. Anatomy is divided into *vegetable,* which treats of the structures and properties of vegetal bodies; *comparative,* which treats of the anatomy of animals; *human,* which treats of the anatomy of man in a physiological or healthy state; *pathological,* which treats of the anatomy of the diseased human body, etc.

Human anatomy is subdivided into general, descriptive, and surgical.

General anatomy treats of the minute structure or physical elements of the organs of the body. It is also called microscopical anatomy, or histology. It comprises four distinct elementary tissues:—

Epithelial, including mucous membranes, epidermis, glands, etc.
Muscular, including striated and nonstriated muscles.
Nervous, including the proper nerve elements.
Connective, including white fibrous, elastic, adipose, cartilage, and bone.

Descriptive or *special anatomy* treats of the various properties of the organs arranged into systems; hence the name systematic. It includes:—

Osteology, the anatomy of the bones.
Syndesmology, the anatomy of the joints.
Myology, the anatomy of the muscles.
Angiology, the anatomy of the vessels.
Neurology, the anatomy of the nerves.
Splanchnology, the anatomy of the viscera, etc., etc.

Surgical or *topographical anatomy* treats of the relative position of organs to one another and to the surrounding parts in special regions of the body, as the axilla, neck, or groin.

OSTEOLOGY.

The framework of the body is composed of bones, which constitute the skeleton. This in the adult consists of 206 bones, including the ossicula auditus: Excluding the ear ossicles, the number is 200, or excluding also the two patellæ and the hyoid bone the number is 197. Spine (including coccyx and sacrum) 26, cranium 8, face 14, ribs, sternum, and os hyoideum 26, upper extremity 64, lower extremity 62, ear ossicles 6.

The bones of the *head* number 22, consisting of

Eight *cranial bones*, the frontal, 2 parietal, occipital, 2 temporal, the sphenoid and ethmoid bones; 14 facial bones, 2 lachrymal, 2 nasal, 2 malar, 2 superior maxillæ, 2 palate, 2 turbinal, 1 vomer, and 1 inferior maxilla.

The bones of the *trunk* number 52, comprising

Twenty-six vertebræ, 7 cervical, 12 dorsal, 5 lumbar, 1 sacrum and 1 coccyx.

Twenty-six of the thorax, 7 pairs of true ribs, 3 pairs of false ribs, 2 pairs of floating ribs, the sternum and os hyoideum.

The bones of the skull, face, thorax, and vertebral column are known as the axial skeleton, and consist of 74 segments.

The bones of the upper extremity number 64, comprising on either side:—

Two shoulder, clavicle and scapula; 1 arm, humerus; 2 forearm, radius and ulna; 8 wrist (carpus), scaphoid, semilunar, cuneiform, pisiform, trapezium, trapezoid, os magnum and unciform; 19 hand, 5 metacarpal and 14 phalanges.

The bones of the lower extremity number 62, comprising on either side:—

One hip, divided into 3 portions, the ilium, ischium and pubes; 1 thigh, the femur; 2 leg, tibia and fibula; 1 knee, the patella; 26 foot, 7 tarsal bones, the astragalus, os calcis, scaphoid, cuboid, external, middle, and internal cuneiform; 5 metatarsal bones, and 14 phalanges.

The bones of the shoulder-girdle, upper extremities, pelvic girdle, and lower extremities are known as the appendicular skeleton, and consist of 126 segments. They are divided into long, short, flat or tabular and irregular.

Long bones, such as femur, humerus, or radius, consist of shaft or diaphysis, and two extremities or epiphyses.

The shaft or *diaphysis* is a cylindrical tube composed externally of compact tissue and internally of cancellous tissue, the center being hollowed out by the *medullary canal.*

The *epiphyses,* or extremities, are expanded for articulation, and are composed of a mass of solid cancellous tissue with a thin coating of compact tissue.

The *short bones,* as tarsus or carpus, are small, compact, irregular cubes.

Flat bones, as those of skull and shoulder-blade, afford extensive surfaces for protection or muscular attachment.

Under *irregular* or mixed bones are classed the vertebral, sphenoid, maxillary bones, and such that could not be placed under either of the other heads.

The *surfaces* of the bones are marked by certain eminences and depressions, which have received the following names:—

An apophysis is a prominent excrescence formed directly upon a bone, and is distinguished from

An epiphysis, which has been formed from a distinct center and separated by cartilage, but afterward united to the bone.

A head is a rounded, smooth, articular eminence for articulation.

A condyle is an irregular prominence for muscular attachment.

A trochanter is a large prominence for the attachment of rotator muscles.

A tuberosity is a broad, uneven eminence.

A tubercle is a small tuberosity.

A spine is a sharp-pointed eminence.

A line, or ridge, is a rough, narrow elevation, extending some distance.

Others, from their fancied resemblance to ordinary objects, have received the following names:—

Coronoid, like a crown; coracoid, like a crow's beak; unciform or hamular, hook-like; malleolar, like a mallet; mastoid, nipple-like; zygoma, yoke-like; pterygoid, wing-like; odontoid, tooth-like; spinous, thorn-like; styloid, pen-like; rostrum, a beak; vaginal, ensheathing; squamous, scaly; conoid, cone-like.

The *cavities* of bones are divided into the articular and the non-articular.

The articular are named acetabulum, measure-like; glenoid, hollow; cotyloid, cup-like; facet, smooth; trochlear, pulley-like; alveolar, socket-like.

The non-articular cavities are named notches, fissures, grooves, furrows, fossæ, hiatus, foramina, canals, sinuses, aqueducts, cells, depressions, meatuses, etc.

Composition of Bone.—Adult human bones have a specific gravity of 1.92, and are composed of about one-third (33.30)

organic or animal matter, principally gelatin, and two-thirds inorganic or mineral matter, as follows:—

Gelatin and blood-vessels, 33.30; phosphate, carbonate, and fluoride of calcium, 64.34; soda, sodium chloride, and magnesium phosphate, 2.36; total, 100.

Structure of Bone.—In *structure* they consist of an ivory-like compact substance (*substantia compacta*) inclosing a lamellar, recticular *cancellous substance;* also designated loose or spongy bone (*substantia spongiosa*).

They are covered with periosteum, and their cavities are lined with endosteum and filled with medulla, or marrow.

Periosteum is a fibrovascular membrane, composed of two layers, the outer formed chiefly of connective tissue, the inner composed of several layers of elastic fibers, the deepest of which is the "osteogenic," or bone-producing layer. The tendons and ligaments are attached to the periosteum by a mutual interlacement of the fibers.

Endosteum, medullary membrane or internal periosteum, is a delicate, highly vascular membrane lining the cylindrical cavity of long bones.

Medulla, or bone-marrow, is of two kinds, the red in the flat and irregular bones, and the yellow in the shafts of adult long bones. The red marrow (*medulla ossium rubra*) has few blood-vessels, but many corpuscular elements. These may be divided into three groups: (1) red, nucleated, true "marrow-cells," or myelocytes; (2) large, pinkish cells, "myeloplaques" of Robin, supposed to be the source of the red blood-corpuscles or erythroblasts; and (3) *giant cells,* or "osteoclasts."

The yellow marrow (*medulla ossium flavo*) or myelocytes contains numerous blood-vessels, a few "marrow-cells," and a large quantity of fat which imparts to it its color.

Blood-vessels of Bone.—The *arteries* consist of three sets: The arteries of the (1) compact and (2) cancellous tissue are derived chiefly from the periosteum, the latter being larger and less numerous. The medullary canal of long bones has (3) one or more nutrient arteries, which penetrate the compact tissue obliquely and divide into two branches, one passing upward, the other downward, in the canal. All the arteries anastomose freely with each other.

The *veins* consist of three sets also: 1. The veins of the compact substance are small and join the periosteum. 2. The veins of the cancellous tissue do not accompany the arteries, but in certain localities form large, tortuous channels, as in the diploïc veins of the cranium. In the long bones they emerge

at the ends near the articular surfaces. 3. The nutrient arteries are accompanied by one or more large veins, which emerge at the nutrient foramen.

Lymphatics and *nerves* are numerous in the periosteum and are also found in the substance of the bone.

Microscopic Appearance.—Microscopically, bone-tissue consists of concentric layers or *lamellæ*, arranged about the course of a vascular or Haversian canal $\frac{1}{16000}$ inch in diameter. In and between these plates of bone-tissue are minute cavities, or *lacunæ*, each containing a bone-cell, or "osteoblast," and from which diverge in every direction minute canals, or *canaliculi*, connecting the lacunæ with each other and with the Haversian canals. Each canaliculus contains an artery, vein, and lymphatic (Schäffer). In this manner every part of the osseous substance communicates.

Development.—The development of bone is effected in two ways: (1) from cartilage, the intracartilaginous; (2) from membrane, the intramembranous; the former occurring at the base of the skull for the protection of vital centers, or in the extremities to secure rigidity of the parts.

In the *intracartilaginous* the parts are first formed in cartilage and then converted into bone. The process is as follows: The cartilage cells at the "center of ossification" become enlarged and arranged in rows. The cartilaginous matrix also increases and separates the cells. Lime salts are deposited between the rows of cells, inclosing them in oblong spaces called *primary areolæ*.

Blood-vessels from the deep or osteogenic layer of the periosteum, carrying numerous osteoblasts (bone-forming cells) and osteoclasts (bone-absorbing cells) pass into the area of calcified cartilage (center of ossification). The osteoblasts replace the calcified cartilage, which is absorbed, with new bone, which latter is absorbed in part (tunneled) by the osteoclasts to form the medullary spaces or marrow cavity.

The walls of the spaces are gradually thickened by successive layers of osteoblasts, forming lamellæ of bone, till nothing remains but a channel—the Haversian canal.

The perichondrium having been in the mean time converted into periosteum, the osteogenic, or vascular, layer of this membrane furnishes a layer of osteoblasts that form enveloping, circumferential layers of bone.

Thus, from the osteoblasts all the structures of bone are produced; the remains of a group of cells constitute an Haversian canal, the layers deposited by them and the adjacent cells,

the lamellæ, and the isolated, persistent cells (osteoblasts) form the contents of the lacunæ, or "true bone-cells," with their nutrient canaliculi diverging from them.

In the *intramembranous* form the parts are first formed in membrane, and from one or more centers of ossification lime salts are deposited in radiating spiculæ, or *osteogenic fibers,* inclosing the *osteoblasts.*

From these fibers the process spreads, and vessels from the neighboring parts pass into it and form Haversian canals.

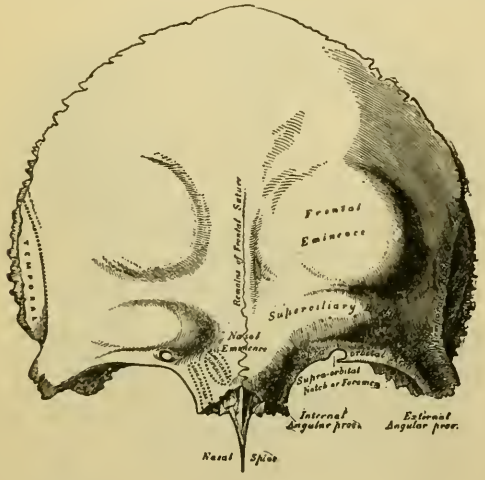

FIG. 1.

Frontal bone, outer surface.

The formation of the lamellæ and the lacunæ is essentially the same as in the intracartilaginous, and in most bones both processes go on simultaneously.

Ossification appears first in the clavicle and inferior maxilla (from fifth to seventh week) and last in the pisiform bone (twelfth year). The epiphyses ossify from birth and unite from the age of puberty on to maturity, in reverse order to the appearance of ossification, being regulated, apparently, by the direction of the nutrient artery in the upper extremity toward the elbow and in the lower extremity from the knee. The only exception to this rule is the lower end of the fibula, which ossifies and also becomes united before the upper (*vide* Table of Ossifi-

cation). In bones with only one epiphysis the artery is directed toward the other extremity.

Growth of Bones.—Long bones grow in thickness from the periosteum and in length from the cartilage between the epiphyses and the shaft near the extremities. The medullary cavity is at first solid and grows by absorption of the cancellous tissue by the giant cells, or osteoblasts.

Flat bones grow in thickness from the periosteum and in surface from the borders. Short bones grow from the center or centers of ossification in all directions.

THE CRANIAL BONES.

The cranial bones are eight in number:—

1 Frontal,	2 Temporal,
2 Parietal,	1 Sphenoid,
1 Occipital,	1 Ethmoid.

THE FRONTAL BONE (*os frontale*) forms the anterior portion of the cranium and consists of two portions, a vertical or frontal portion and a horizontal or orbitonasal portion.

The vertical portion consists of two surfaces, external and internal.

The external surface (*facies frontalis*) is convex, and presents the frontal eminence (*tuber frontale*) on either side of the median line, the superciliary ridges (*arcus superciliaris*) produced by the frontal sinuses, beneath, below which is the supraorbital arch (*margo supraorbitalis*), forming the upper boundary of the orbit, and terminating on either side in the external angular process (*processus zygomaticus*), articulating with the malar bone, and the *internal angular process,* articulating with the lachrymal bone, and having at its inner third a notch or foramen, the supraorbital foramen, for passage of supraorbital artery, nerve and vein.

Ascending from the external angular process is the temporal ridge (*linea temporalis*) for attachment of temporal fascia. Between the internal angular processes is the *nasal notch,* for articulation with the nasal bone, and nasal process of superior maxilla, terminating below in the nasal spine (*spina nasalis* or *frontalis*), and above it projects the *nasal eminence,* or glabella, marking the location of the frontal sinuses.

The posterior or *internal surface* (cerebral surface, or *facies cerebralis*) is concave and lodges the anterior lobes of the brain.

In the median line is the frontal crest (*crista frontalis*), which gives attachment to the falx cerebri and terminates below in a foramen, the foramen cæcum, for passage of a small vein from the nose to the longitudinal sinus. The crest is grooved for longitudinal sinus, and has on either side of it depressions for the Pacchionian bodies. This surface is also grooved for anterior meningeal arteries.

The horizontal portion or orbital portion (*pars orbitalis*) consists of an external and internal (cerebral surface, *facies cerebralis*) surface.

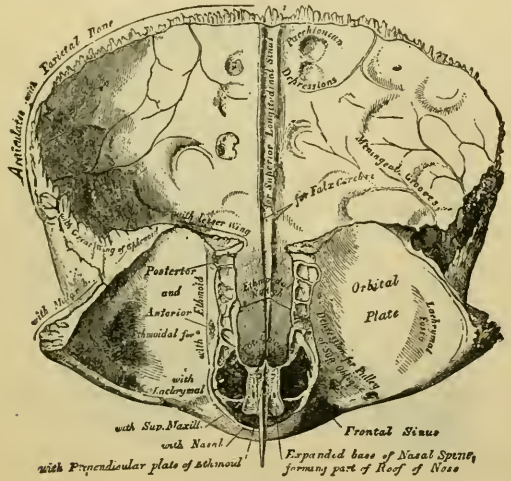

FIG. 2.

Frontal bone, inner surface.

The external surface (*facies orbitalis*) is concave, to form the roof of the orbit, and separated from the opposite side by the ethmoidal notch.

To the outer side is a deep depression for the lachrymal gland, the lachrymal fossa (*fossa glandula lacrimalis*), and to the inner side a slight one, the trochlear fossa (*fovea trochlearis*), for the *pulley* of superior oblique.

On the margin of the orbital plate are two notches converted into foramina by articulation with the ethmoid, the anterior ethmoidal canal (*foramen ethmoidale anterius*), for passage of nasal nerve and anterior ethmoidal vessels, and the posterior ethmoidal canal (*foramen ethmoidale posterius*), for passage of posterior ethmoidal vessels.

The *internal surface* is marked by the convolutions of the anterior lobes of the brain.

Between the two plates of the vertebral portion are the frontal sinuses, two irregular cavities lined with mucous membrane and opening into the middle meatus of the nose on either side by the infundibulum (*infundibulum ethmoidale*).

It articulates with twelve bones: two parietal, sphenoid, ethmoid, nasal, superior maxillary, lachrymal, and malar.

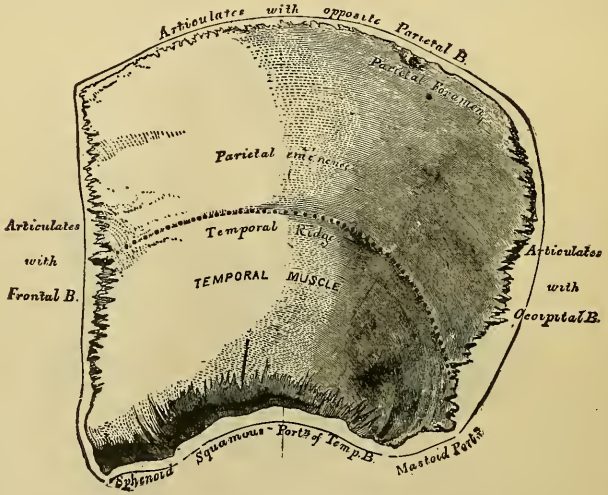

FIG. 3.

Parietal bone, outer surface.

Its muscular attachments are three pairs: corrugator supercilii, orbicularis palpebrarum, and temporal.

It is developed from membrane by two ossific centers, one for each lateral half.

PARIETALS (*os parietale*).—These are two quadrilateral bones forming the superior and lateral walls of the cranium. Each bone consists of two surfaces, four borders, and four angles.

The external surface (*facies parietalis*) is convex and presents the parietal eminence (*tuber parietale*) a little above the middle, marking the original center of ossification, the temporal ridge (*linea temporalis*), crossing about the center for attachment of the temporal fascia, and the parietal foramen (*foramen*

parietale), near the superior border or sagittal suture, for passage of a vein, the emissary vein of Santorini, to the longitudinal sinus.

The internal surface or cerebral surface (*facies cerebralis*) is concave, and presents *furrows* for the branches of the meningeal arteries, depressions (*foveolæ granulares* [Pacchioni]) for cerebral convolutions, and Pacchionian bodies.

A half-groove (*sulcus sagittalis*) along the superior border for longitudinal sinus, and

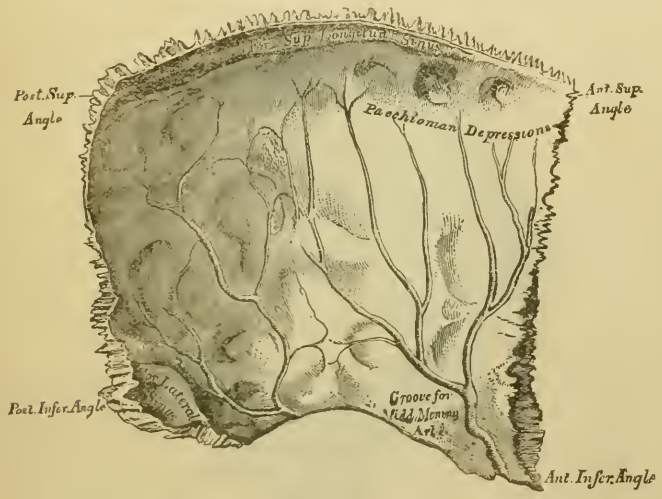

FIG. 4.

Parietal bone, inner surface.

A groove (*sulcus transversus*) near the posterior inferior angle for the lateral sinus.

The superior border or sagittal margin (*margo sagittalis*) articulates with its fellow of the opposite side, forming the sagittal suture;

The inferior border—also called the squamous margin (*margo squamosus*)—articulates from before backward with the sphenoid, squamous and mastoid portions of temporal bones;

The anterior border—also called frontal margin (*margo frontalis*)—forms with the frontal bone the coronal suture, and

The posterior border or occipital margin (*margo occipitalis*) forms with the occipital bone the lambdoid suture.

Of the angles, the anterior inferior (*angulus sphenoidalis*) is the only important one, being longer and grooved internally by the middle meningeal artery.

It articulates with five bones—frontal, sphenoid, temporal, occipital, and opposite parietal bones.

It has but one muscle attached—the temporal.

It is developed from an ossific center.

The occipital bone (*os occipitalis*) forms the posterior inferior portion of the cranium. It presents two surfaces, four angles, and four borders.

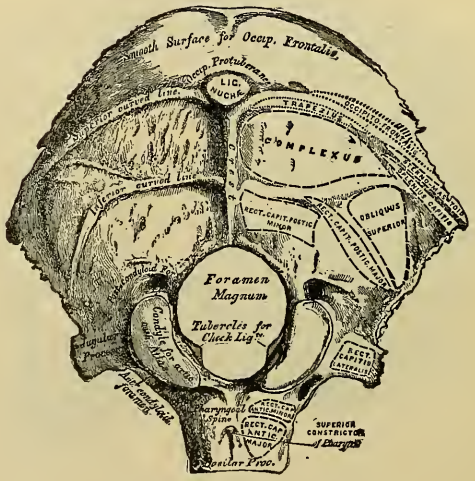

FIG. 5.

Occipital bone, outer surface.

The *external* and *posterior surface* is irregularly convex, and presents

The occipital protuberance or inion (*protuberantia occipitalis externa*), for insertion of ligamentum nuchæ, descending from which to the foramen magnum is

The occipital crest (*crista occipitalis externa*) for tendinous attachment, and diverging on either side, above and below, are

The superior curved or superior nuchal line (*linea nuchæ supræma*) for attachment of occipitofrontalis, trapezius, and other muscles; and

The inferior curved or inferior nuchal line (*linea nuchæ inferior*) for attachment of rectus capitis posticus, major and minor.

Anteriorly it presents a large aperture,

The foramen magnum (*foramen occipitale magnum*), transmitting the medulla oblongata and its coverings, the vertebral arteries, and the spinal accessory nerves.

On either side of the foramen magnum are the condylic or lateral portions (*partes laterales*) bearing the condyles (*con-*

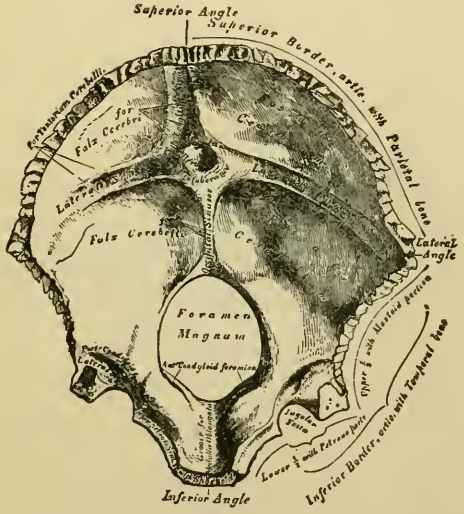

FIG. 6.

Occipital bone, inner surface.

dylus occipitalis) for articulation with the atlas, the inner border of each condyle presenting a *tubercle* for the check ligament.

Externally to each condyle are the jugular processes (*processus jugularis*) affording attachment for the *rectus capitis lateralis*, and forming by its articulation with the fibrous portion of the temporal bone the *jugular foramen*, or *foramen lacerum posterius*, transmitting the internal jugular vein, glossopharyngeal, pneumogastric and spinal accessory nerves, and meningeal branches of the ascending pharyngeal and occipital arteries.

In front of the condyles on either side are the openings of

the anterior condyloid foramen (*canalis hypoglossi*), for passage of hypoglossal nerve and meningeal branch from the ascending pharyngeal artery; and behind, the posterior condyloid foramen (*canalis condyloideus*), for passage of a small vein to the lateral sinus.

In front of the foramen magnum is the basilar process (*pars basilaris*), articulating with the sphenoid bone, and grooved on its under surface by the pharyngeal spine (*tuberculum pharyngeum*) for the insertion of the tendinous raphé and superior constrictor of the pharynx.

The *internal* or *cerebral surface* is irregularly concave and divided by a *crucial ridge,* or *occipital cross,* into four fossæ, the upper, for the posterior lobes of the cerebrum, and the lower, for the lateral lobes of the cerebellum. Its center is marked by an eminence, the internal occipital protuberance (*protuberantia occipitalis interna*), which is hollowed out to correspond to the *torcular Herophili,* or *confluence of the sinuses.*

The upper division of the crucial ridge affords attachment for the falx cerebri, being grooved for the great longitudinal sinus; the lower extremity, called also the internal occipital crest (*crista occipitalis interna*), affords attachment for the falx cerebelli, being grooved for the occipital sinus; and the lateral divisions afford attachment for the tentorium cerebelli and are grooved for the lateral sinuses.

The *internal* surfaces of the jugular processes are grooved for the lateral sinuses.

In front of the foramen magnum is the basilar groove (*clivus*) lodging the medulla oblongata and part of the pons Varolii. Its lateral borders (the basilar process) are grooved (*sulcus petrosus inferior*) for the *inferior* petrosal sinus.

The *superior angle* articulates with the parietal bones, the *inferior angle* articulates with the sphenoid, and the *lateral angles* are wedged in between the mastoid portion of the temporal and the posterior inferior angle of the parietal.

This bone has four foramina—foramen magnum, anterior and posterior condyloid, and foramen lacerum posterius.

It articulates with six bones—two parietal, two temporal, the sphenoid and the atlas.

The muscular attachments are twelve (12): occipitofrontalis, trapezius, sternomastoid, complexus, splenius capitis, obliquus superior, rectus capitis posticus major and minor, rectus lateralis, rectus anticus major and minor and constrictor pharyngis superior.

It is developed from seven (7) ossific centers: four for

the tabular, or *supraoccipital,* or occipital portion proper: one for each condyloid, or *external occipital* portion, and one for the basilar, or *basioccipital* portion.

Temporals (*os temporale*).—These are situated at the side and base of the cranium, and consist of three portions—the squamous, mastoid and petrous.

The squamous portion (*squama temporalis*) is scale-like, and overlaps the parietal bone. Its external surface (*facies temporalis*), convex behind, concave in front, presents from before backward the following:—

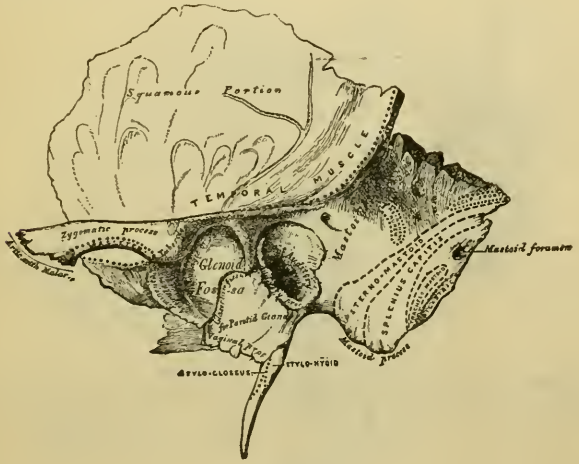

Fig. 7.

Left temporal bone, outer surface.

The zygoma, or zygomatic process (*processus zygomaticus*), an arched process of bone articulating with the zygomatic process of the malar bone, affording attachment above to the temporal fascia and below to the masseter muscle. It is connected to the body of the bone by three roots, the *anterior root* of which ends in the eminentia articularis (*tuberculum articulare*), a process of bone in front of the glenoid cavity, and presents at its junction a *tubercle* for the external lateral ligament; the *middle root,* also called the postglenoid process or tubercle, terminates at the Glaserian fissure (*fissura petrotympanic* [*Glaseri*]), and the *posterior root* forms the posterior portion of temporal ridge and gives attachment to the retrahens aurem.

The *glenoid fossa* (mandibular) is a marked depression hollowed out for articulation of the condyle of the lower jaw. It is bounded in front by the eminentia articularis, to the outer side by the middle root, and behind by the vaginal process (*vagina processus styloidei*). It is divided into two portions by the Glaserian fissure, the anterior being separated from the auditory process by the *postglenoid tubercle*—rudimentary in man—and the posterior being formed by the *tympanic plate*, a thin plate of bone forming the front wall of the tympanum.

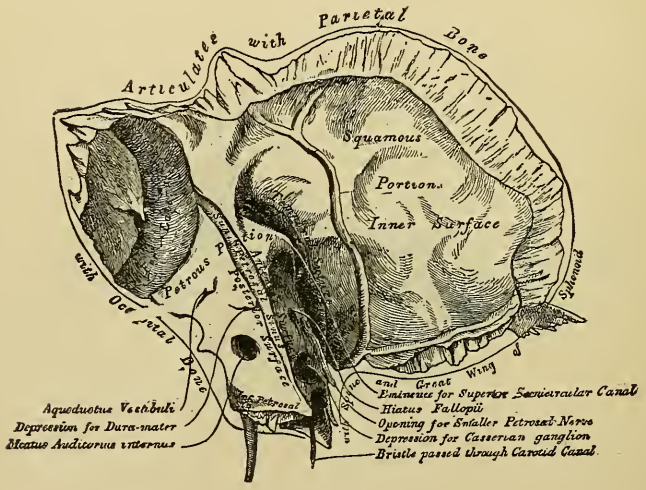

FIG. 8.

Left temporal bone, inner surface.

The *Glaserian fissure* communicates with the tympanum, transmits the tympanic branch of the internal maxillary artery, and lodges the processus gracilis of the malleus.

In the angle between the squamous and petrous portions the chorda tympani nerve passes from the tympanum through the canal of Huguier (*canaliculus chordæ tympani*).

The internal surface (cerebral surface, *facies cerebralis*) of the squamous portion presents the markings of the convolutions, and grooves for the ramifications of the middle meningeal artery. The mastoid portion (*pars mastoidea*) is convex, rough, and nipple-like, and presents, externally, the following:—

The mastoid foramen (*foramen mastoideum*) near the pos-

terior border, transmits a branch of the occipital artery to the dura mater and a small vein to the lateral sinus;

The mastoid process (*processus mastoideus*), a prominent projection, composed of the mastoid cells (*cellulæ mastoideæ*), and affording insertion for the splenius capitis, sternomastoid and trachelomastoid muscles.

To its inner side is a groove, the digastric groove, also called digastric fossa (*incisura mastoidea*), for attachment of

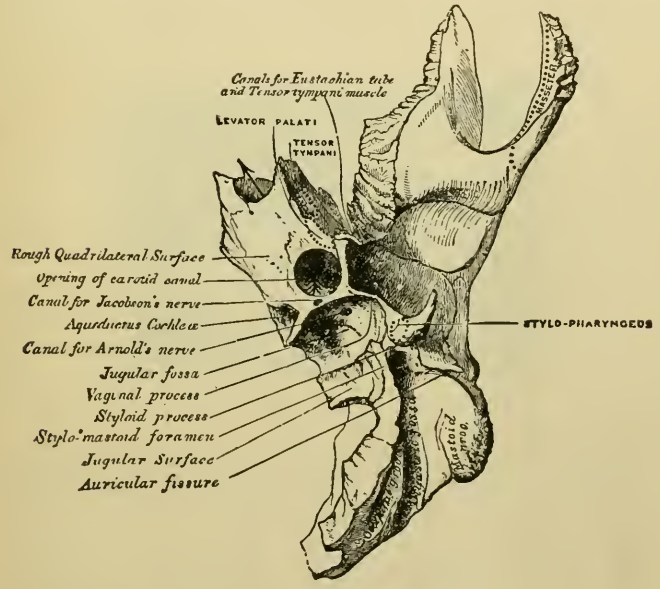

FIG. 9.

Left temporal bone, inferior surface of the petrous portion.

the digastric muscle, and still more internally the occipital groove (*sulcus a. occipitalis*) for the accommodation of the occipital artery.

The internal surface is concave, and presents a groove, the fossa sigmoidea (*sulcus sigmoideus*) for the lateral sinus, in the bottom of which is the opening of the mastoid foramen (*foramen mastoideum*).

The petrous portion (*pars petrosa pyramis*) is pyramidal in shape, intensely hard, and contains the internal ear. It pro-

jects downward, forward and inward, and presents for examination a superior, posterior and inferior surface.

The superior or anterior surface (*facies anterior pyramidis*) is united to the squamous portion by the temporal suture and presents the following:—

An eminence (*eminentia arcuata*), marking the position of the superior semicircular canal;

A *depression,* forming the roof of the tympanum;

The hiatus Fallopii (*hiatus canalis facialis*), transmitting a branch of the middle meningeal artery and the petrosal branch of the Vidian nerve to the aqueduct of Fallopius;

Foramen (*apertura superior canaliculi tympanici*) for the smaller petrosal nerve;

Orifice of the *carotid canal,* transmitting the carotid plexus of the sympathetic and the internal carotid artery; and

Depression (*impressio trigemini*) for Gasserian ganglion of the trifacial nerve.

The posterior surface (*facies posterior pyramidis*) presents about its middle

The *meatus auditorius internus* (*meatus acusticus internus*), at the bottom of which is the *lamina cribrosa,* a perpendicular plate of bone, and numerous foramina for the exit of the auditory nerve and the auditory branch of the basilar artery, one of which is the commencement of the aquæductus Fallopii (*canalis facialis*) for the facial nerve.

Posteriorly to the internal meatus is the *aquæductus vestibuli,* lodging a process of dura mater, and transmitting an artery and vein, and between them another small depression for the same purpose.

The inferior or basilar surface (*facies inferior pyramidis*) presents, from within outward, the following:—

A *rough, quadrilateral surface,* for attachment of the tensor tympani and levator palati muscles;

The opening of the carotid canal (*foramen caroticum externum*), transmitting the carotid plexus of the sympathetic and the internal carotid artery;

Aquæductus cochleæ (*apertura externa canaliculi cochleæ*), transmitting a vein to the internal jugular vein from the cochlea;

Jugular fossa (*fossa jugularis*), forming the jugular foramen (*foramen lacerum posterius*) by articulation with the occipital bone, and transmitting the internal jugular vein, the glossopharyngeal, pneumogastric, and spinal accessory nerves,

and meningeal branches of the ascending pharyngeal and occipital arteries;

Foramen for *Jacobson's nerve,* the tympanic branch of the glossopharyngeal (*n. tympanicus*);

Foramen for *entrance* of *Arnold's nerve,* the auricular branch of the pneumogastric;

Jugular surface for *articulation* with *jugular process* on occipital bone;

The vaginal process (*vagina processus styloidea*), extending from the mastoid process to the carotid canal, and ensheathing

FIG. 10.

Section of the temporal bone (natural size) through the middle ear, Fallopian canal, mastoid antrum, and cells, showing dense bone between the antrum and cells, with no communication between them: 1, drumhead; 2, tip of the mallet handle; 3, anvil, showing the long crus at the right for articulation with the stirrup, and the short process at the left which serves the purpose of an anchor to the bone; 4, head of the mallet; 5, tensor tympani muscle and tendon; 6, dense bone where pneumatic spaces are usually found; 7, pneumatic cells in the tip of the mastoid process; 8, Fallopian canal, for the facial nerve; 9, the stirrup. At the right of 9 and at the left of the anvil is the aditus ad antrum, connecting the tympanum with the antrum.

The styloid process (*processus styloideus*), affording attachment for the stylomaxillary and stylohyoid ligaments and the stylohyoideus, stylopharyngeus and styloglossus muscles;

The stylomastoid foramen (*foramen stylomastoideum*), for exit of facial nerve;

The auricular fissure (*fissura tympanomastoidea*), for the exit of Arnold's nerve, the auricular branch of the pneumogastric.

The *base* of the *petrous portion* presents

The external auditory meatus (*meatus acusticus externus*), the canal leading into the tympanum, and

The *auditory process,* a lamina of bone forming the greater part of its walls.

Borders.—The superior border (*angulus superior pyramidis*) affords attachment to the *tentorium cerebelli,* and has a groove for the superior petrosal sinus. The posterior border (*angulus posterior pyramidis*) forms part of the jugular fossa (*fossa jugularis*). The anterior border (*angulus anterior pyramidis*) articulates with the spinous process of the sphenoid. Between the squamous and petrous portions may be seen the opening of the *canalis musculotubarius;* this canal is found either completely or partially divided by an osseous lamina, separated by the *processus cochleariformis* (*septum canalis musculotubarii*), for the tensor tympani muscle above and the Eustachian tube below.

Muscular attachments are fifteen:—

To the squamous portion, 2—the temporal and masseter; to the mastoid portion, 6—sternomastoid, occipitofrontalis, splenius capitis, trachelomastoid, retrahens aurem, and digastricus; to the styloid portion, 3—stylohyoideus, stylopharyngeus and styloglossus; and to the petrous portion, 4—levator palati, tensor palati, tensor tympani and stapedius.

Its ossific centers are ten (10), 1 for the squamous portion, including the zygoma, 1 for auditory process, 6 for petrous and mastoid portions, and 2 for the styloid process.

The sphenoid (*os sphenoidale*) is wedged in between the bones at the base of the skull anteriorly and resembles a bat with extended wings. It consists of

A body,	2 Lesser wings, and
2 Greater wings,	2 Pterygoid processes.

It presents

12 Foramina,	12 Pairs of muscles, and
12 Articulations,	14 Centers of ossification,

and is in every respect the most important bone of the cranium, entering into the formation of

5 Cavities—
- (1) Anterior cerebral,
- (2) Middle cerebral,
- (3) Orbital,
- (4) Pharyngeal,
- (5) Nasal,

4 Fossæ—
- (1) Temporal,
- (2) Zygomatic,
- (3) Sphenomaxillary,
- (4) Nasal, and

3 Fissures—
- (1) Sphenomaxillary,
- (2) Pterygomaxillary, and
- (3) Sphenoidal or foramen lacerum anterior.

The body (*corpus*) is a hollow cube and presents upper, lower, anterior and posterior surfaces.

The upper surface (*facies cerebralis*) of the body presents from before backward the following points:—

Ethmoidal spine (*spina ethmoidalis*), for articulation with the cribriform plate of the ethmoid;

Optic groove (*sulcus chiasmatis*), lodging the optic commissure and terminating in the optic foramen;

Olivary process (*tuberculum sellæ*), a small, olive-like eminence behind the optic groove;

Pituitary fossa or sella turcica (*fossa hypohyseos*), for the pituitary body;

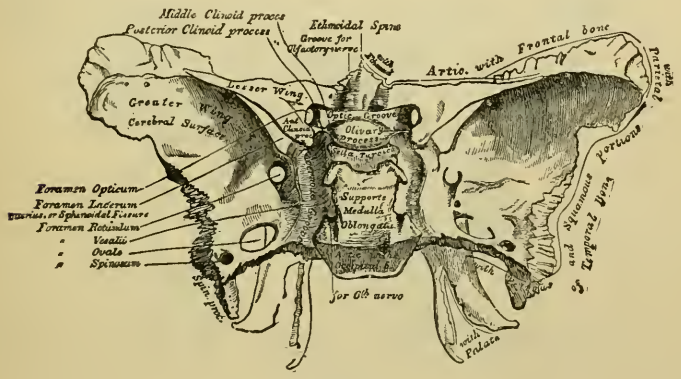

FIG. 11.

Sphenoid bone, upper surface.

Middle clinoid processes (*processus clinoidei medii*), one on either side bounding the pituitary fossa;

Dorsum sellæ, or dorsum ephippii, a quadrilateral plate of bone, bounding the pituitary fossa behind, and notched on either side for the passage of the sixth cranial nerves;

Posterior clinoid processes (*processus clinoideus posterior*) are the terminations of the dorsum sellæ on either side and afford attachment to the tentorium cerebelli;

Declivity, or *clivus Blumenbachii* (*clivus*), supporting the upper part of the pons Varolii;

Carotid or cavernous groove (*sulcus caroticus*), lodging the cavernous sinus and the internal carotid artery;

Lingula (*lingula sphenoidalis*), a ridge of bone to the outer side of the cavernous sinus.

The lower surface presents:—

Rostrum (*rostrum sphenoidalis*), the continuation downward of the ethmoidal crest, for articulation with the alæ of the vomer;

Vaginal processes, a thin plate of bone on either side articulating with the edges of the vomer; and

Groove (*sulcus pterygopalatinus*), converted into the pterygopalatine canal by articulation with the sphenoidal process of the palate bone for transmission of the pharyngeal nerve and pterygopalatine vessels.

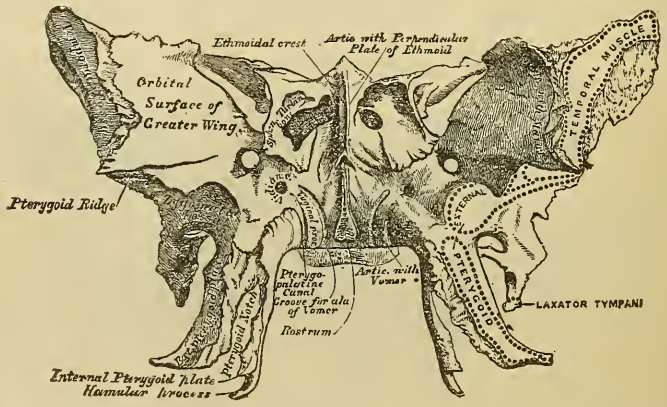

FIG. 12.

Sphenoid bone, anterior surface.

The anterior surface presents:—

Ethmoidal crest or sphenoidal crest (*crista sphenoidalis*), a thin plate of bone articulating with the ethmoid;

Openings of sphenoidal cells or sinuses (*sinus sphenoidales*) partially closed by the sphenoidal turbinated bones or pyramids of Wistar (*conchæ sphenoidales*), two curved plates of bone absent in infancy, but derived as a pair of cones from the ethmoid. The sphenoidal cells open into the superior meatus of the nose, but occasionally into the posterior ethmoidal sinuses.

The posterior surface articulates with the basilar process of the occipital and becomes united to it between the eighteenth and twenty-fifth year.

GREATER OR TEMPORAL WINGS OF THE SPHENOID (ALÆ MAGNÆ).

The superior surfaces (*facies cerebralis*) of the great wing, deeply concave, forms part of middle fossa of skull, and presents the following:—

Foramen rotundum, for second division of fifth nerve; *foramen ovale,* for third division of fifth, small meningeal artery, and small petrosal nerve; *foramen Vesalii,* for small vein, and *foramen spinosum,* for passage of middle meningeal artery.

The *exterior surface* is convex and presents:—

Pterygoid ridge or infratemporal crest (*crista infratemporalis*), dividing the bone into two portions;

Spinous process, for attachment of tensor palati muscle, and the internal lateral ligament of the lower jaw.

The anterior or orbital surface (*facies orbitalis*) enters into the formation of the orbit and presents numerous *external orbital foramina* for passage of branches of the deep temporal arteries.

The *circumference* of the greater wing forms part of the sphenoidal fissure and articulates with the frontal bone in front and laterally with the parietal, squamous and petrous portions of the temporal bone.

The lesser or orbital wings (*alæ parvæ*), or *processes of Ingrassias,* project on either side from the superior surface of the body, to which they are attached by two roots.

The *upper surface* forms part of the anterior fossa of the skull. The lower surface forms part of the orbit and the upper border of the *sphenoidal fissure,* or *foramen lacerum anterius* (*fissura orbitalis superior*), transmitting the third, fourth and ophthalmic divisions of the fifth and the sixth cranial nerve, orbital branch of the middle meningeal artery, a recurrent branch of the lachrymal artery, the ophthalmic vein, and filaments from the cavernous plexus.

The anterior clinoid process (*processus clinoideus anterior*) is formed by the inner extremity of the posterior border.

Between the two roots is the optic foramen (*foramen opticum*), transmitting the optic nerve and ophthalmic artery.

The pterygoid processes (*processus pterygoidei*) are two wing-like processes descending from the junction of the greater wings with the body.

Each process presents the following:—

An external pterygoid plate (*lamina lateralis processus pterygoidei*), for attachment of the external pterygoid muscle;

The pterygoid fossa (*fossa pterygoidei*) lies between the two plates and affords attachment for the internal pterygoid muscle.

The internal pterygoid plate (*lamina medialis processus pterygoidei*), terminating below in a hook-like process—the hamular process (*hamulus pterygoideus*)—for the tendon of the tensor palati muscle.

The scaphoid fossa (*fossa scaphoidea*), at the base of the internal plate, affording origin for the tensor palati muscle and presenting just above it, the posterior opening of the Vidian canal (*canalis pterygoideus* [Vidii]) for the Vidian vessels and nerves.

An angular interval between the two plates articulates with tuberosity or pterygoid process of the palate bone.

The foramina are: Opticum, lacerum anterius, rotundum, Vesalii, ovale, spinosum, and two canals—Vidian and pterygopalatine; articulates with twelve bones—two malar, two palate, vomer, and all of cranium. Its muscular attachments are eleven pairs—external and internal pterygoid, temporal, tensor palati, superior constrictor, levator palpebræ, obliquus superior; superior, inferior, internal and external recti. Its ossific centers are fourteen, as follows: Body, 2 anterior and 2 posterior; external pterygoid plates and greater wings, 2; internal pterygoid plates, 2; lingula, 2; lesser wings, 2; sphenoturbinals, 2.

The ethmoid (*os ethmoidale*) is a spongy, cubical bone, consisting of a perpendicular lamella, a horizontal or cribriform plate, and two lateral masses.

The horizontal or cribriform plate (*lamina cribrosa*) presents from before backward the following points:—

Two projections (*processus alares*) completing the *foramen cæcum*, the commencement of the longitudinal sinus;

Crista galli, affording attachment to the falx cerebri;

Foramina cribrosa, three rows, transmitting filaments of the olfactory body;

Fissure for passage of the nasal branch of the ophthalmic nerve.

The perpendicular plate (*lamina perpendicularis*, or mesethmoid) assists in forming the nasal septum, articulating in front with the crest of the nasal bones and the frontal bone and behind with the sphenoid and vomer. It is usually inclined to one side.

The lateral masses—labyrinth (*labyrinthus ethmoidalis*)—are composed of the ethmoidal cells.

The *upper surface* presents two notches, converted into foramina by articulation with the frontal bone—

The anterior ethmoidal foramen (*canalis ethmoidalis anterius*), transmitting the anterior ethmoidal artery and nasal nerve, and

The posterior ethmoidal foramen (*canalis ethmoidalis posterius*), transmitting the posterior ethmoidal artery and vein.

The *outer surface* presents

The *os planum* (*lamina papyracea*), a smooth plate of bone forming the inner wall of the orbit, and projecting downward from it is

FIG. 13.
Ethmoid bone.

The unciform process (*processus uncinatus*), a hook-like plate of bone closing the upper part of the opening of the antrum.

The *inner surface* forms part of the nasal fossa, and presents

The superior turbinated bone (*concha nasalis superior*), forming the upper boundary of the superior meatus (*meatus nasi superior*), into which open the sphenoidal and posterior ethmoidal cells, and the

Middle turbinated bone or the inferior ethmoidal turbinate bone (*concha nasalis media*), forming the upper boundary of the middle meatus of the nose, into which open the anterior ethmoidal cells, the frontal cells through the infundibulum (*infundibulum ethmoidale*) and the antrum Highmorianum (*sinus maxillaris*).

It articulates with fifteen bones—two sphenoidal turbinated, sphenoid, frontal, and eleven of the face, the two nasal, two lachrymal, two superior maxillæ, two palate, two inferior turbinated and the vomer.

It has no muscular attachments.

Its ossific centers are three—one for the lamella and one for each lateral mass.

BONES OF THE FACE (OSSA FACIEI).

The bones of the face are fourteen in number—six pairs and two single bones: Two lachrymal, two nasal, two malar, two

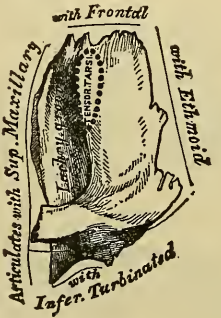

FIG. 14.

Lachrymal bone.

superior maxillary, two palate, two turbinal, one vomer and one inferior maxillary.

THE LACHRYMAL (*os lacrimale*) are two small, thin bones forming part of the inner wall of the orbit and the lachrymo-nasal duct, and named, from their resemblance to a finger-nail, the ossa unguis.

Each presents externally:—

The lachrymal crest (*crista lacrimalis posterior*) affords attachment for the tensor tarsi and separates the anterior surface from the groove;

The *groove* forms part of the lachrymal groove and lodges the lachrymal sac;

The hamular process (*hamulus lacrimalis*), or, when separate, called the *lesser lachrymal bone,* projects downward and articulates with the lachrymal tubercle of the superior maxilla.

Internally:—

A *furrow*, corresponding to the lachrymal crest on the external surface;

The *internal surface* enters into the formation of the middle meatus, closing in the anterior ethmoidal cells.

It articulates with four bones—the frontal, ethmoid, superior maxilla and inferior turbinated.

The only muscular attachment is the tensor tarsi.

It is developed from one ossific center.

THE NASAL bones (*ossa nasalia*) are two irregularly quadrate bones forming together the bridge of the nose.

The *outer surface*, covered by the compressor nasi and pyramidalis nasi muscles, presents

A foramen (*foramen nasale*), transmitting a small vein.

The *inner surface* presents

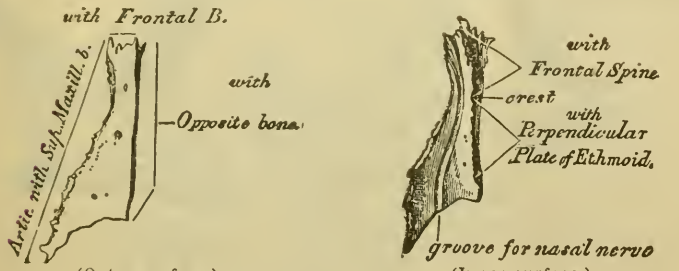

FIG. 15.

Nasal bones.

A *groove* or *canal* for a branch of the nasal nerve.

The inferior border, the most important, has attached to it the lateral cartilage of the nose, and presents

A *spine*, forming, with its fellow, the *nasal angle*, a *notch* for exit of the branch of the nasal nerve which grooves the posterior surface.

It articulates with four bones—frontal, ethmoid, superior maxilla, and its fellow.

It has no muscular attachments. It is developed from one center.

THE MALAR BONES (*os zygomaticum*) are two quadrilateral bones forming the prominence of the cheek. They enter into the formation of the orbit and the zygomatic and temporal fossæ.

Each bone has four processes—zygomatic, maxillary, frontal and orbital.

The external or malar surface (*facies malaris*) has attached to it the zygomatic muscles (major and minor), and presents

A foramen (*foramen zygomaticofaciale*) to its outer side for the malar branch of the temporomalar nerve and a foramen to its inner side for the temporal branch of the temporomalar.

The internal or temporal surface (*facies temporalis*) articulates with the superior maxilla, has attached to it the masseter and temporal muscles, and presents the internal openings of the foramen given above.

The zygomatic process (*processus temporalis*) forms, with the zygomatic process of the temporal bone, the zygoma.

(Outer surface.) (Inner surface.)

FIG. 16.

Malar bones.

The *maxillary process* is triangular and roughened for articulation with the superior maxilla.

The frontal process (*processus frontosphenoidalis*) is articulated with the external angular process of the temporal bone.

The *orbital process,* the most important, articulates by its upper and inner surface, or supero-internal surface (*facies orbitalis*) with the greater wing of the sphenoid, forming part of the outer wall of the orbit; the under surface forms part of the temporal fossa, while the posterior margin forms part of the sphenomaxillary fissure. The *superior surface* presents two temporomalar foramina (*foramen zygomatico-orbitale*), transmitting temporomalar branches of the superior maxillary nerve.

It articulates with four bones—the frontal, sphenoid, temporal and superior maxilla.

Its muscular attachments are five—the masseter, temporal, zygomaticus major and minor, and the levator labii superioris.

It is developed from one ossific center.

THE SUPERIOR MAXILLA is the largest bone of the face, excepting the lower jaw, and one of the most important, assisting in the formation of three cavities, the mouth, nose and orbit; two fissures, the sphenomaxillary and pterygomaxillary; and two fossæ, the sphenomaxillary and zygomatic. It consists of a body and four processes—the nasal, the malar, the palatine and the alveolar (Fig. 17).

The body (*corpus maxillæ*) is excavated to form the *maxillary sinus* or *antrum Highmorianum* (*sinus maxillaris*), a large,

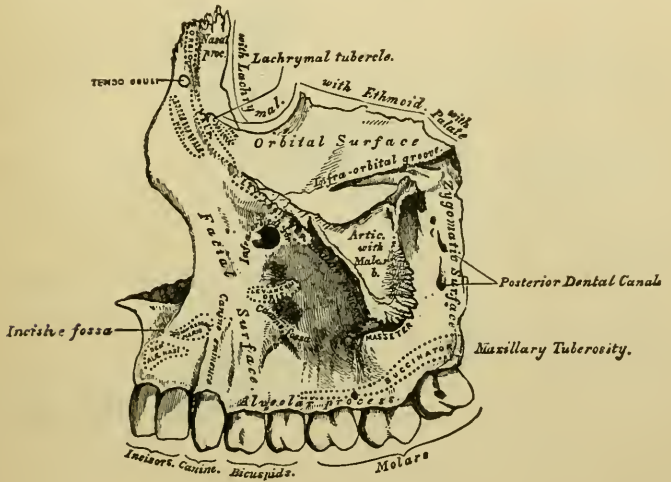

FIG. 17.

Superior maxillary bone.

irregular triangular cavity, with its base directed inward, its apex upward and outward, projecting into the malar process.

Its posterior wall (*facies infratemporalis*) presents the *posterior dental canals*, transmitting the posterior dental vessels and nerves.

The external or facial surface (*facies anterior*) (Fig. 17) of the body presents the following points:—

Incisive fossa, or *myrtiform fossa*, for the origin of the depressor alæ nasi:

Canine fossa (*fossa canina*), for origin of levator anguli oris;

Canine eminence, over the position of the canine tooth;

Infraorbital foramen (*foramen infraorbitale*), for the exit of the infraorbital nerve and artery.

The internal surface (*facies nasalis*) of the body presents:—

Palate process (*processus palatinus*) separating the mouth from the nasal fossæ;

An irregular opening, the maxillary hiatus (*hiatus maxillaris*), leading to the *antrum Highmorianum*, before alluded to;

Groove completing the posterior palatine canals behind;

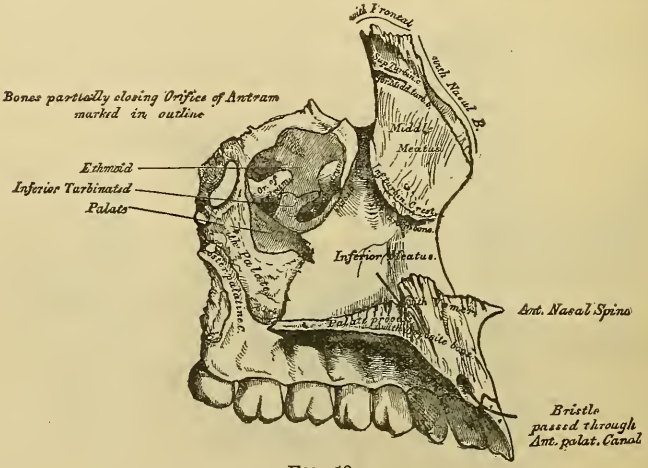

FIG. 18.

Superior maxillary, inner surface.

Deep groove in front, forming, with the inferior turbinated bone and lachrymal, the lachrymal canal (*canalis nasolacrimalis*) for lachrymonasal duct;

Inferior turbinated crest (*crista conchalis*) for the turbinated bone.

The superior orbital surface (*facies orbitalis*) presents:—

Infraorbital groove (*sulcus infraorbitalis*) about the middle for the infraorbital artery and nerve;

Anterior dental canal, one of the divisions of the infraorbital canal, transmitting the anterior dental vessels and nerve.

The posterior or zygomatic surface (*facies infratemporalis*) presents:—

Posterior dental canals (*foramina alveolaria*), transmitting posterior dental nerves and vessels;

Maxillary tuberosity (*tuber maxillare*), articulating with the tuberosity of the palate bone;

Groove, converted into posterior palatine canal by the palate bone for posterior palatine vessels and nerves.

The nasal process (*processus frontalis*) projects upward to articulate with the frontal bone, its external surface smooth, affording attachment to several muscles, its internal surface forming part of the outer wall of the nose. It presents the following:—

Superior turbinated crest (*crista ethmoidalis*), for the middle turbinated bone of the ethmoid;

Inferior turbinated crest (*crista conchalis*) below, for the inferior turbinated bone;

Groove at the posterior margin, forming part of the lachrymal canal;

Lachrymal tubercle, at the junction of the nasal process with the orbital surface.

The malar process (*processus zygomaticus*) projects upward and outward to articulate with the malar bone.

The palatine process (*processus palatinus*) projects from the internal surface of the bone to form part of the roof of the mouth and the floor of the nose. It presents:—

Anterior palatine canal or fossa (*foramen incisivum*), divided into four canals;

Foramina of *Stenson*, one on either side, transmit the anterior branch of the descending palatine artery;

Foramina of *Scarpa*, one in front and behind, transmit the nasopalatine nerves;

Suture in the anterior part showing original separation of the incisive or intermaxillary bone (*os incisivum*);

Posterior palatine groove for the posterior palatine vessels, and anterior palatine nerves from Meckel's ganglion;

Nasal crest (*crista nasalis*) for the vomer, and

Anterior nasal spine (*spina nasalis anterior*), projecting from the anterior extremity of the crest.

The alveolar process (*processus alveolaris*) forms the curved, spongy portion for the insertion of the upper teeth. It presents

The *alveoli* or sockets (*alveoli dentales*) of varying depths, eight in the adult, five in the child.

It articulates with nine (9) bones—the ethmoid, frontal, lachrymal, nasal, malar, inferior turbinated, palate, vomer, and its fellow of the opposite side.

Its muscular attachments are nine—the levator labii superioris alæque nasi, levator labii superioris proprius, levator anguli oris, compressor naris, depressor alæ nasi, orbicularis palpebrarum, inferior obliquus, masseter and buccinator.

It is developed from four centers: one for incisive bone, or premaxilla; one for palate process, or prepalatine; one for the maxillary portion, including the orbital and facial portion; and one for the malar portion.

Each palate bone (*os palatinum*) is a thin, -shaped bone, consisting of an inferior or horizontal plate and a superior or vertical plate.

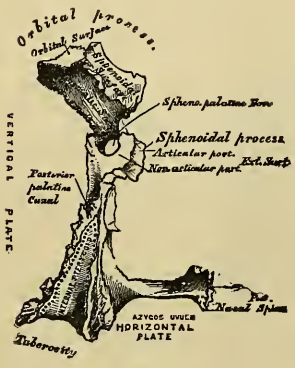

Fig. 19.

Palate bone (viewed posteriorly).

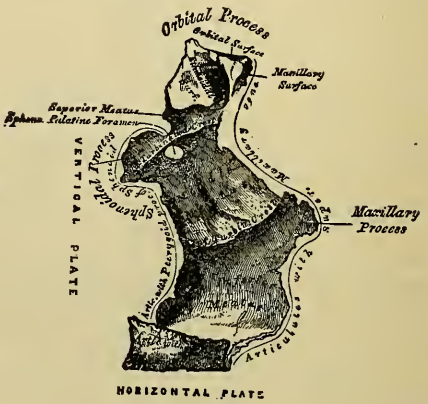

Fig. 20.

Palate bone (inner surface).

Each bone assists in forming three cavities—the outer wall and floor of the nose, the roof of the mouth and floor of the orbit; two fossæ—the pterygoid (*fossa pterygoidea*) and sphenomaxillary (*fossa pterygopalatina*), and one fissure—the sphenomaxillary (*fissura orbitalis inferior*).

The horizontal plate (*pars horizontalis*) is quadrilateral. Its inferior surface (*facies palatina*) presents

A *ridge* for the aponeurosis of the tensor palati muscle;

A groove (*sulcus pterygopalatinus*) entering into the formation of the *posterior palatine canal;*

Accessory palatine foramina (*canales palatini*) for posterior descending palatine nerves.

Its posterior border (*spina nasalis posterior*) presents

The posterior nasal spine (*crista nasalis*) for the azygos uvulæ muscles.

The *internal border* articulates with its fellow and presents

A *crest* for the vomer.

The vertical or perpendicular plate (*pars perpendicularis*) projects upward and inward, terminating above in two well-marked processes—the *orbital* and *sphenoidal processes.*

The internal or nasal surface (*facies nasalis*) forms part of the outer wall of the nasal fossa, and presents

An inferior turbinated crest (*crista conchalis*) for the inferior turbinated bone;

A superior turbinated crest (*crista ethmoidalis*) for the middle turbinated bone, separating the middle from the inferior meatus of the nose.

The external or maxillary surface (*facies maxillaris*) forms part of the sphenomaxillary fossa and covers part of the orifice of the antrum.

It presents at the posterior part

A *groove,* converted by the superior maxilla into a canal, the posterior palatine, for the passage of the descending palatine vessels and the descending palatine branches from Meckel's ganglion.

The *anterior* border presents

The maxillary process (*processus maxillaris*), closing part of the orifice of the antrum.

The pterygoid process (*processus pyramidalis*), or tuberosity of the palate, at its lower part wedged in between the pterygoid plates of the sphenoid, and giving origin to part of the superior constrictor and the internal pterygoid muscle.

Foramina of *accessory descending palatine canals,* for posterior descending branches from Meckel's ganglion.

The orbital process (*processus orbitalis*), a large, hollow, triangular process, is so called from its forming part of the orbit.

It presents

The *anterior* or *maxillary articular surface* for superior maxilla;

The *posterior* or *sphenoidal articular surface* for sphenoid;

The *internal* or *ethmoidal articular surface* for ethmoid;

A *superior* or *orbital surface,* a smooth portion entering into the formation of the orbit;

An *external* or *zygomatic surface,* also smooth, forming part of the zygomatic fossa.

The sphenoidal process (*processus sphenoidalis*) is a small, thin plate of bone which articulates by its upper surface with the sphenoidal turbinated bone; its inner surface forms

part of the nasal fossa, and its outer surface articulates with the pterygoid process of the sphenoid and forms part of the sphenomaxillary fossa.

The anterior border forms a part of the *sphenopalatine foramen,* which passes between the orbital process and the sphenoidal process.

It articulates with six (6) bones—ethmoid, sphenoid, superior maxillary, vomer, inferior turbinated, and fellow of the opposite side.

Its muscular attachments are azygos uvulæ, tensor palati, internal and external pterygoid and superior constrictor. It has one ossific center at the junction of the plates.

THE INFERIOR TURBINATED BONES (*concha nasalis inferior*) are small, scroll-like bones, situated on the outer wall of the

(Inner surface.) (Outer surface.)

FIG. 21.

Inferior turbinated bones.

nasal fossa, separating the middle from the inferior meatus. Each presents two surfaces and three processes—the lachrymal, ethmoidal and maxillary.

The *internal surface* is lined in the recent state with the mucous membrane of the nose.

The *external surface* is attached to the superior maxilla and palate bone, and presents above the three processes.

The lachrymal process (*processus lacrimalis*) forms part of the lachrymal canal, articulating with the superior maxilla and the lachrymal bone.

The ethmoidal process (*processus ethmoidalis*) articulates with the hook-like process of the ethmoid bone.

The maxillary process (*processus maxillaris*) projects outward and downward from the ethmoidal process, and narrows the orifice of the antrum.

It articulates with four bones—ethmoid, palate, superior maxillary and lachrymal.

Muscular attachments, none. It has one ossific center.

The vomer is a thin, triangular plate of bone, contributing to form part of the *septum nasi*. It is usually bent to one side.

The superior border presents a groove with overlapping laminæ, or vaginal processes (*alæ vomeris*) for articulation with the rostrum and vaginal processes of the sphenoid.

The *inferior border* articulates with the crests of the superior maxillæ and palate-bones.

The *posterior border* is smooth and free, forming the posterior nasal septum.

The *lateral surfaces* present

Furrows for blood-vessels, and

Nasopalatine grooves for the nasopalatine nerves, which descend to the foramina of Scarpa.

Fig. 22.

Vomer.

It articulates with six bones—the ethmoid, sphenoid, two palate and two superior maxillæ.

It has no muscular attachments. It is developed from a single ossific center, although it begins as two cartilaginous laminæ, which coalesce.

The inferior maxilla, or mandible (*mandibula*), is the largest bone in the face. It consists of a body and two rami.

The body (*corpus mandibulæ*) is the horizontal, horseshoe-like portion, containing the lower teeth.

The *external surface* presents from before backward:—

Symphysis, a vertical median line indicating the junction of the vaginal halves;

Mental process (*protuberantia mentalis*), a triangular prominence constituting the chin;

Incisive fossa, for the origin of the levator labii inferioris;

Mental foramen (*foramen mentale*), for the exit of the mental nerve and artery;

External oblique line (*linea obliqua*), running backward and upward from the mental process, for the attachment of the depressor anguli oris and depressor labii inferioris.

The *internal surface* presents from before backward:—

Genial tubercles (*spinæ mentales*), four in number, for attachment of the geniohyoglossi muscles above and the geniohyoidei below;

Sublingual fossa (*fovea sublingualis*), for the sublingual gland;

Internal oblique line or mylohyoid ridge (*linea mylohyoidea*), for the attachment of the superior constrictor, the mylohyoid muscles, and the pterygomaxillary ligament;

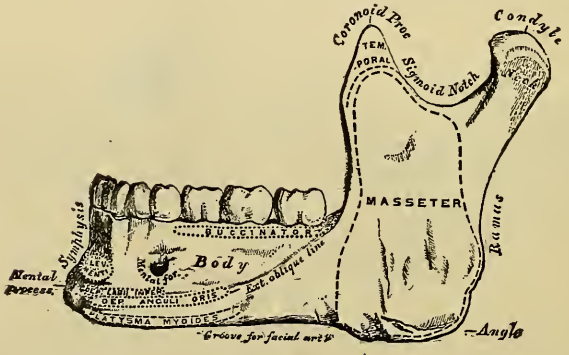

FIG. 23.

Inferior maxillary bone.

Submaxillary fossa (*fovea submaxillaris*), for the submaxillary gland.

The superior or alveolar border (*pars alveolaris*) presents sixteen cavities (ten in childhood) for the teeth.

The inferior border, or basilar portion (*basis mandibulæ*) is grooved posteriorly for the facial artery.

The ramus, or perpendicular portion (*rami mandibulæ*), on either side is somewhat quadrilateral, and presents the following points:—

The *internal surface of ramus;*

Foramen (*foramen mandibulare*) of *inferior* dental canal (*canalis mandibulæ*), for inferior dental vessels and nerve;

Mylohyoidean groove (*sulcus mylohyoideus*), described above;

Spine, for attachment of the internal lateral ligament of the lower jaw.

The *upper border* is surmounted by two processes, the coronoid and the condyloid processes, separated by the sigmoid notch.

The coronoid process (*processus coronoideus*) is in *front,* and affords attachment for the temporal muscle.

The condyloid process (*processus condyloideus*) articulates with the glenoid fossa of the temporal bone, being supported upon a constricted portion, the neck (*collum mandibulæ*), which receives the insertion of the external pterygoid muscle, and

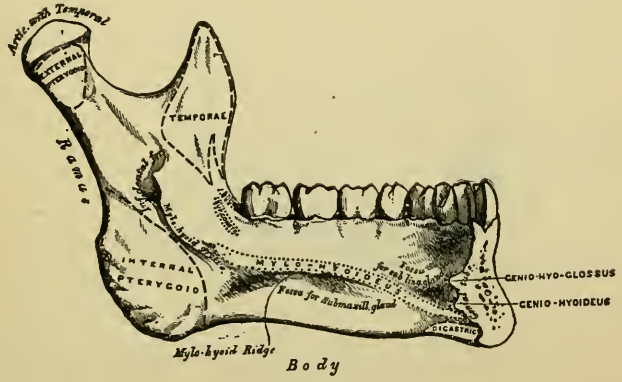

FIG. 24.

Left half of inferior maxillary bone, inner surface.

presents to its outer side a tubercle for the external lateral ligament of the lower jaw.

The sigmoid notch (*incisura mandibulæ*) is crossed by the masseteric vessels and nerve.

The *lower border* presents:—

Angle of the jaw (*angulus mandibulæ*), the point of junction of the ramus with the body;

Rough surface, for attachment of the stylomaxillary ligament, and on its inner side the internal pterygoid muscle, and on its outer side the masseter.

It articulates with the two temporal bones.

The muscular attachments are fifteen pairs: to the external surface, six—depressor anguli oris, depressor labii inferioris, levator labii inferioris, orbicularis oris, platysma myoides and buccinator; from the internal surface of the body, five—the

geniohyoglossus, geniohyoid, mylohyoid, digastric and superior constrictor; and to the ramus, four—the masseter, internal and external pterygoids and temporal.

It has two ossific centers, one for each lateral half, developed partly from membrane, partly from cartilage, being preceded in time only by one bone—the clavicle.

Changes in Lower Jaw.—Certain changes occur in the size and shape of the lower jaw as age advances.

At birth the body is shell-like, containing sockets for the ten temporary teeth, the mental foramen is large and opens beneath first molar, and the coronoid process is large and at right angles to base.

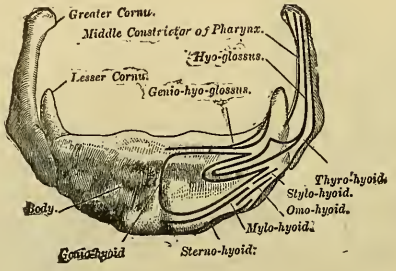

FIG. 25.

The hyoid bone.

In adults the base and alveolar process are equal in size, the mental foramen opens midway between upper and lower borders, and the rami are at nearly right angles to base.

In advanced age the loss of the teeth and alveolar borders greatly reduces the body, the mental foramen opens near the alveolar border, and the rami are united at very obtuse angles with the base.

THE HYOID BONE, or lingual bone (*os hyoideum*) is a small, U-shaped bone situated at the base of the tongue, consisting of a body (*corpus ossei hyoidei*), two greater and two lesser cornua.

It is supported by the stylohyoid ligament from the styloid processes of the temporal bones.

The *anterior surface* is divided by a *crucial ridge* into four depressions for muscular attachments, and its center presents a *tubercle*.

The *posterior surface* is in relation with the epiglottis, being separated by the thyrohyoid membrane.

The *upper* and *lower borders* afford attachment to muscles, and the *lateral surfaces* are mounted with cartilage for articulation with the greater cornua.

The greater cornua, or thyrohyals (*cornua majora*), project backward, afford attachment to the hyoglossus, thyrohyoid, and middle constrictor of the pharynx, and terminate behind in a tubercle for the attachment of the thyrohyoid ligament.

The lesser cornua, or ceratohyals (*cornua minora*), are two tuber-like projections attached at the junction of the body with the greater cornua, and receiving the insertion of the stylohyoid ligaments. They do not articulate with any bone.

Its muscular attachments are ten—the lingualis, hyoglossus, geniohyoglossus, middle constrictor, stylo-, mylo-, genio-, sternothyro-, omo- hyoid; also aponeurosis of digastric and stylohyoid ligament.

Ossific centers, five—one for body and one for each horn.

The Sutures and Fontanelles.—The *sutures* are divided into three sets, those of the vertex, side, and base of the skull.

At the *vertex* of the skull there are three:—

Sagittal, or interparietal (*sutura sagittalis*);
Coronal, or frontoparietal (*sutura coronalis*);
Lambdoid, or occipitoparietal (*sutura lambdoidea*).

At the *side* of the skull are three:—

Sphenoparietal (*sutura sphenoparietalis*);
Squamoparietal, or squamous (*sutura squamosa*);
Mastoparietal (*sutura parietomastoidea*).

At the *base* of the skull are nine:—

Basilar, in center (*fissura spheno-occipitalis*),
Petro-occipital (*fissura petro-occipitalis*),
Masto-occipital (*sutura occipitomastoidea*),
Petrosphenoidal (*fissura sphenopetrosa*),
Squamosphenoidal (*sutura sphenosquamosa*),
} on either side.

The sutures of the face are very numerous, but the most important are:—

Zygomatic, at the temporomalar junction;
Transverse, passes from one external angular process to the other, and connects the frontal with the malar, ethmoid, sphenoid, lachrymal, superior maxillary and nasal bones;
Intermaxillary, the median suture between the superior maxillæ;
Symphysis, the remains of a fetal suture.

The fontanelles (*fonticuli*) are six membranous intervals in the infant's skull corresponding to the four angles of the parietal bones. The anterior or bregmatic (*fonticulus frontalis*), larger

and lozenge-shaped, is at the junction of sagittal and coronal sutures; the posterior (*fonticulis occipitalis*), smaller and triangular, is at the junction of sagittal and lambdoid sutures; and the four lateral are at anterior and posterior inferior angles of parietal bones (*fonticulus sphenoidalis et fonticulus mastoideus*).

The Wormian, supernumerary, sutural or epactal bones (*ossa triquetra*) are irregular bones interposed in intervals between the cranial bones, chiefly in the course of the lambdoid suture.

Congenital fissures from an arrest of ossification also occur, the most common being the parietal and sagittal fissures (Treves).

FOSSÆ OF SKULL.

The fossæ at the lateral region of the skull are temporal, zygomatic, or infratemporal, and sphenomaxillary or pterygopalatine fossa.

The temporal fossa (*fossa temporalis*) is deeply concave in front, convex behind; it is formed by parts of five bones—frontal, malar, sphenoid, temporal and parietal. It is bounded above and behind by temporal ridge; in front by the sphenoid, malar and frontal; below and externally by zygoma, and pterygoid ridge on greater wing of sphenoid. It is crossed by six sutures—sphenomalar, sphenoparietal, squamoparietal, squamosphenoidal, coronal and transverse facial. It opens below into the zygomatic fossa, is filled by the temporal muscle, and lodges the deep temporal vessels.

The zygomatic or infratemporal fossa (*fossa infratemporalis*) is an irregular cavity containing parts of temporal, external and internal pterygoid muscles, and is bounded above by pterygoid ridge of sphenoid and squamous portion of temporal, below by alveolar border of superior maxilla, in front by tuberosity of superior maxillary, behind by border of pterygoid process, externally by zygoma and ramus of lower jaw and internally by external pterygoid plate. It is traversed by two fissures—sphenomaxillary and pterygomaxillary.

The sphenomaxillary fissure (*fissura orbitalis inferior*) connects the zygomatic, temporal and sphenomaxillary fossæ, and transmits the infraorbital artery, ascending branches of Meckel's ganglion, the superior maxillary nerve and its orbital branch.

It is bounded above by great wing of sphenoid, below by superior maxilla and part of palate bone; internally it opens into pterygomaxillary fissure and externally part of malar bone.

The *pterygomaxillary fissure* connects the zygomatic and sphenomaxillary fossæ, passing vertically between pterygoid process of sphenoid and superior maxillary bone, and transmits branches of internal maxillary artery.

The sphenomaxillary or pterygopalatine fossa (*fossa pterygopalatina*) is a triangular cavity, bounded above by body of

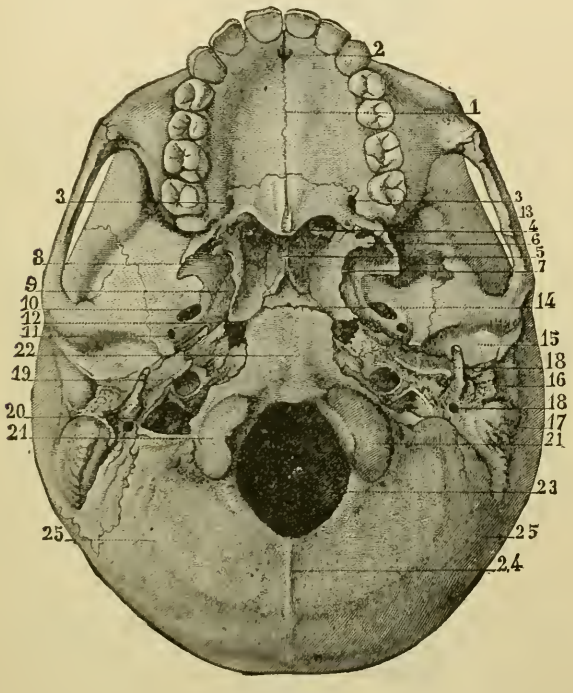

FIG. 26.

1, median suture; 2, anterior palatine foramen; 3, posterior palatine foramen; 4, posterior nasal spine; 5, vomer; 6, hamular process; 7, pterygopalatine canal; 8, external plate; 9, scaphoid fossa; 10, foramen ovale; 11, foramen spinosum; 12, foramen lacerum medium; 13, zygoma; 14, basilar suture; 15, glenoid fossa; 16, external auditory meatus; 17, mastoid process; 18, styloid process; 19, carotid foramen; 20, foramen lacerum posterius; 21, occipital condyles; 22, basilar process; 23, foramen magnum; 24, occipital crest; 25, inferior curved lines.

sphenoid and orbital plate of palate-bone, within by vertical plate of palate, in front by superior maxillary, and behind by pterygoid process of sphenoid. It has communicating with it

Three fossæ—orbital, nasal and zygomatic;

Three fissures—sphenoidal, sphenomaxillary and pterygo-maxillary;

Two cavities—cranial and buccal; and

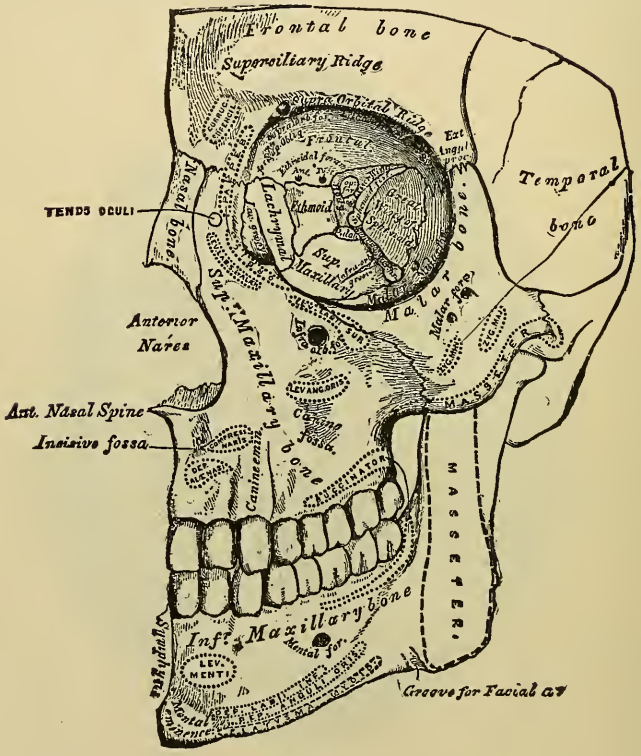

FIG. 27.

Facial portion of skull.

Five foramina—foramen rotundum, Vidian and pterygo-palatine posteriorly; sphenopalatine, on inner wall, and posterior palatine canal, and (sometimes) accessory posterior palatine canals below. It contains internal maxillary artery, superior maxillary nerve and Meckel's ganglion.

THE ORBITS are two pyramidal cavities, situated between the nose and external angular processes, the forehead and face, their bases outward and forward, their apices converging toward

the body of the sphenoid bone. They contain the eye and its appendages, and are each formed by seven bones—frontal, ethmoid, sphenoid (entering into both cavities), superior maxillary, lachrymal, malar and palate (separate in each). The roof (*paries superior*), concave, presents:—

Externally, depression for lachrymal gland;

Internally, depression for pulley of superior oblique;

Posteriorly, a suture between lesser wing and frontal bone.

It is formed by the orbital plate of frontal and lesser wing of sphenoid.

The floor (*paries inferior*) is short and flat, and presents:—

Internally, a depression for inferior oblique muscle;

Middle, the infraorbital groove for nerve and artery;

Externally, suture of superior maxillary and malar;

Posteriorly, suture between palate and superior maxillary.

It is formed by orbital processes of malar and superior maxilla and orbital surface of palate.

Inner wall (*paries medialis*) presents crest of lachrymal bone, lachrymal groove, sutures between ethmoid and sphenoid and ethmoid and lachrymal.

It is formed by lachrymal, parts of ethmoid, and sphenoid and nasal process of superior maxilla.

The outer wall (*paries lateralis*) presents suture between malar and sphenoid and orifices of malar canals. It is formed by orbital plate of sphenoid and orbital process of malar.

The *angles* of the orbit are four—superior internal and external, inferior internal and external.

They present the following:—

Superior internal angle:

Foramen ethmoidal anterior, transmitting anterior ethmoidal vessels and nasal nerve;

Foramen ethmoidal posterior, transmitting posterior ethmoidal artery and vein;

Suture between frontal and ethmoid, and frontal and lachrymal;

Superior external angle:

Sphenoidal fissure, or *foramen lacerum anterius,* transmitting third, fourth, ophthalmic division of fifth and sixth nerves; orbital branch of middle meningeal artery, filaments of cavernous plexus of sympathetic, recurrent branch of lachrymal artery, and ophthalmic vein and process of dura mater.

Suture between great wing of sphenoid and malar bone.

Inferior internal angle:

Suture between superior maxillary and palate bones, uniting with lachrymal and os planum of ethmoid;

Inferior external angle:

Sphenomaxillary fissure, for passage of superior maxillary nerve and its orbital branch, infraorbital vessels, and ascending branches from Meckel's ganglion.

The circumference is bounded:—

Inner side by nasal process of superior maxilla and internal angular process of frontal;

Outer side by external angular process of frontal and malar bone;

Above (*margo supraorbitalis*) by supraorbital arch;

Below (*margo infraorbitalis*) by lachrymal, superior maxilla and malar.

It presents *sutures malomaxillary* below;

Sutures frontomalar to outer side;

Sutures frontomaxillary to inner side;

Supraorbital notch or *foramen* above, for passage of supraorbital nerve, artery and vein, and forms part of lachrymal groove.

The *apex* presents:—

Optic foramen, for passage of optic nerve and ophthalmic artery.

Each *orbit* presents nine (9) openings, as follows:—

1. *Supraorbital* foramen for passage of supraorbital artery, vein and nerve;

2. *Infraorbital* canal for infraorbital nerve and artery;

3. *Anterior ethmoidal foramen* for anterior ethmoidal artery, vein, and the nasal nerve;

4. *Posterior ethmoidal foramen* for posterior ethmoidal artery and vein;

5. *Malar foramina,* for malar and temporal branches of temporomalar nerve;

6. *Lachrymal canal,* for lachrymonasal duct;

7. *Sphenomaxillary* fissure, for infraorbital vessels, superior maxillary nerve and its orbital branches, and ascending branches from sphenopalatine (Meckel's) ganglion;

8. *Foramen lacerum anterius* (or sphenoidal fissure), for third, fourth, ophthalmic division of fifth and sixth nerves, ophthalmic vein, branches of lachrymal and meningeal arteries, filaments of the sympathetic nerve and a process of dura mater for ensheathing of the nerve;

9. Optic foramen, for optic nerve and ophthalmic artery.

THE NASAL FOSSÆ (*cavum nasi*) consist of two large cavities separated from each other by the *septum nasi* (*septum nasi osseum*), and opening in front by the anterior nares (*apertura pyriformis*), and behind into the pharynx by the posterior nares (*choanæ*).

They are formed by fourteen bones—the frontal, ethmoid, sphenoid and all the bones of the face except the lower jaw and malar.

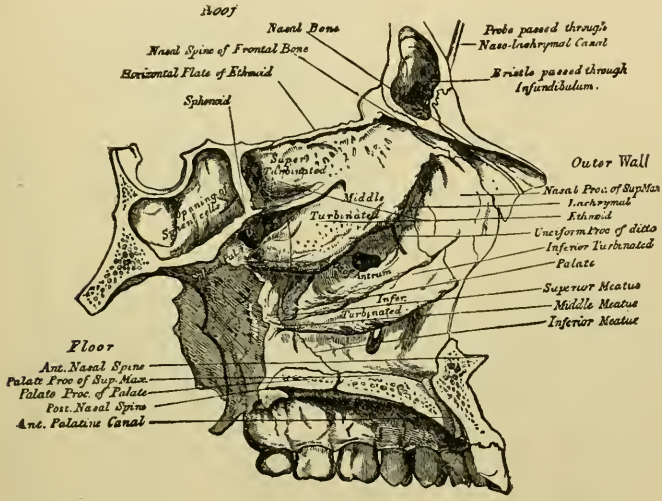

FIG. 28.

Nasal meatuses.

They have each four sinuses opening into them—the ethmoidal and antrum of Highmore (maxillary) on either side, the sphenoidal behind and the frontal above, and communicate with the mouth by the anterior palatine canal, with the orbit by the lachrymal canal, with the sphenomaxillary fossa by the sphenopalatine foramen, and with the cranium by the olfactory foramina.

They are each bounded by an outer, inner, upper and lower wall.

The *outer wall* is divided by the *middle* turbinated *process* of the *ethmoid* and the inferior turbinated bone into the *superior*, *middle* and *inferior meatuses* of the *nose*.

The superior meatus (*meatus nasi superior*), the smallest, has three orifices opening into it:—

The posterior ethmoidal cells;

The sphenoidal sinuses, opening behind the superior turbinated bone and

The sphenopalatine foramen, for transmission of sphenopalatine vessels and superior nasal and nasopalatine nerves.

The middle meatus (*meatus nasi medius*) has two orifices:—

The *infundibulum* (*infundibulum ethmoidale*), communicating with the frontal sinuses, and through them with the anterior ethmoidal cells and the orifice of the antrum or maxillary sinus.

The inferior meatus (*meatus nasi inferior*), the smallest, has two orifices:—

The *lachrymal canal,* for lachrymonasal duct and the *anterior palatine canals,* for anterior branches of descending palatine arteries (foramina of Stenson) and nasopalatine nerves (foramina of Scarpa).

The *inner wall* (*septum nasi*) is formed by the vomer, vertical plate of the ethmoid and the triangular cartilage of the nose, with portions of the following bones: nasal spine of the frontal, rostrum of the sphenoid, and the crests of the nasal, palate and superior maxillary bones. It is grooved by the nasopalatine and other nerves.

The *upper wall* or *roof* presents the following from before backward:—

The *nasal slit* in the cribriform plate, for passage of nasal nerve, a branch of ophthalmic;

The *olfactory foramina,* for olfactory filaments and

Openings or *orifices* posteriorly of the sphenoidal sinuses.

The *lower wall* or *floor* presents from before backward:—

The *anterior nasal spine;*

The *anterior palatine canals,* given above;

Crest or *ridge* for vomer;

Suture between superior maxillary and palate-bone and

Posterior nasal spine.

FORAMINA AT THE BASE OF THE SKULL.

Anterior fossa (*fossa cranii anterior*) presents one single foramen and four in pairs:—

Foramen cæcum transmits a small vein to the superior longitudinal sinus;

Ethmoidal fissure transmits nasal branch of ophthalmic nerve;

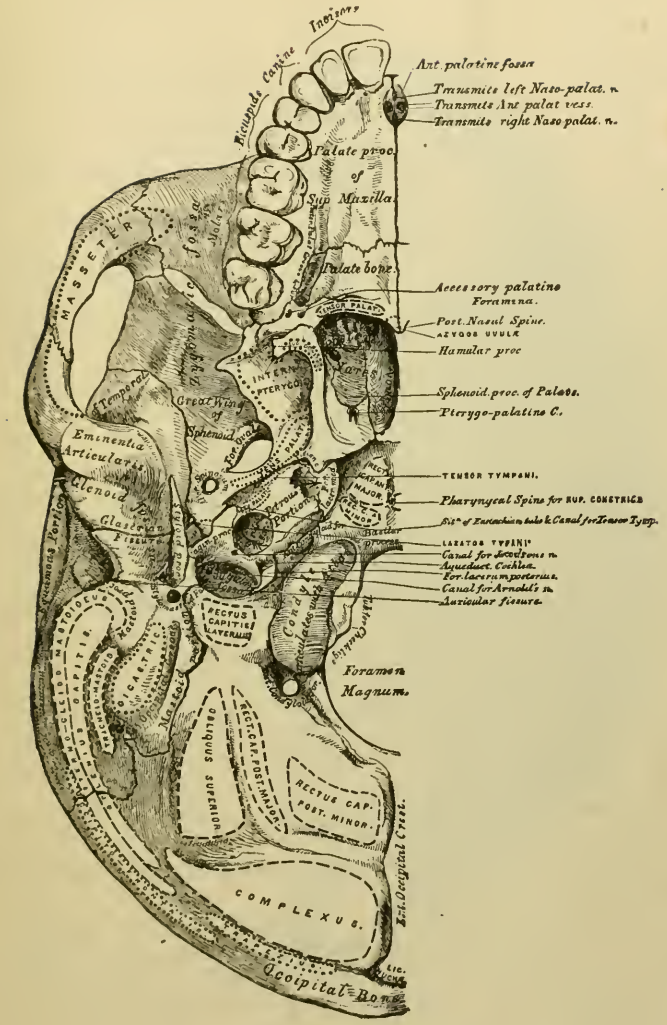

FIG. 29.

Base of skull, external surface.

Olfactory foramina, for filaments of olfactory bulb;

Anterior ethmoidal transmit anterior ethmoidal artery and nasal nerve;

Posterior ethmoidal transmits posterior ethmoidal artery and vein.

Middle fossa (*fossa cranii media*) presents nine (9) pairs:—

Optic foramen transmits the optic nerve and ophthalmic artery;

Foramen lacerum anterius, or sphenoidal fissure (*fissura orbitalis superior*), transmits third, fourth, three branches of the ophthalmic division of the fifth and the sixth nerve, orbital branch of the middle meningeal, recurrent branch from the lachrymal artery, filaments of the sympathetic nerve, and ophthalmic vein;

Foramen rotundum transmits second division of fifth or superior maxillary;

Foramen Vesalii transmits a small vein;

Foramen ovale transmits third division of fifth or inferior maxillary nerve, small petrosal nerve and small meningeal artery;

Foramen spinosum transmits middle or great meningeal artery;

Foramen lacerum medium transmits the internal carotid artery, carotid plexus, a branch of ascending pharyngeal artery and the Vidian or large petrosal nerve;

Foramen for lesser petrosal nerve, and

Hiatus Fallopii transmits petrosal branch of middle meningeal artery and petrosal branch of the Vidian nerve.

Posterior fossa (*fossa cranii posterior*) presents six pairs and one single one:—

Meatus auditorius internus transmits auditory artery, facial and auditory nerves;

Aquæductus vestibuli transmits small artery and vein and lodges a process of dura mater;

Foramen lacerum posterius, or jugular foramen, transmits inferior petrosal sinus and lateral sinus, forming the internal jugular vein, glossopharyngeal, pneumogastric, spinal accessory nerves and meningeal branches of ascending pharyngeal and occipital arteries;

Mastoid foramen transmits small vein to the lateral sinus and small artery from occipital to the dura mater;

Anterior condyloid foramen transmits meningeal branch from ascending pharyngeal artery and hypoglossal nerve;

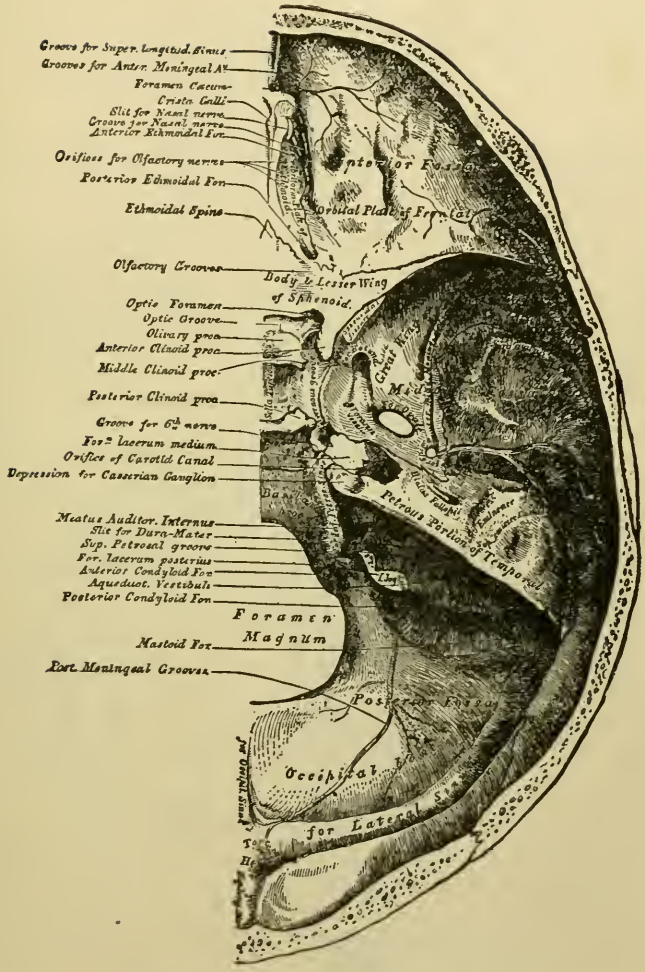

FIG. 30.

Floor of the cranium.

Posterior condyloid foramen transmits posterior condyloid vein;

Foramen magnum transmits vertebral arteries, medulla oblongata and its membranes and the spinal accessory nerves.

OTHER FORAMINA OF SKULL.

The *external surface of the base,* or basilar surface, presents seven pairs:—

PALATAL PORTION:—

Incisive foramina transmit nerves and vessels to the incisor teeth;

Foramina of Stenson transmit the anterior branch of the posterior palatine vessels;

Foramina of Scarpa transmit the right and left nasopalatine nerve;

Posterior palatine foramina transmit posterior palatine vessels and descending palatine nerve;

Accessory palatine foramina transmit posterior palatine nerves;

Pterygopalatine canals transmit pterygopalatine vessels, and the

Pterygoid or Vidian canal (*canalis pterygoideus*) transmits the Vidian artery and nerve.

LATERAL PORTION presents nine pairs:—

Opening of the Eustachian tube;

Opening of the tensor tympani canal transmits the tensor tympani muscle;

Glaserian fissure transmits the tympanic branch of the internal maxillary artery and lodges the processus gracilis of the malleus;

Canal of Huguier transmits chorda tympani nerve;

Foramen for Jacobson's nerve, the tympanic branch of the glossopharyngeal nerve;

Foramen for Arnold's nerve, the auricular branch of the pneumogastric nerve;

Opening of aquæductus cochleæ transmits a vein from the cochlea to internal jugular vein;

Auricular fissure gives exit to Arnold's nerve;

Stylomastoid foramen transmits the facial nerve and stylomastoid artery.

ANTERIOR REGION presents three pairs:—

Supraorbital foramen, or notch, transmits supraorbital artery, vein and nerve;

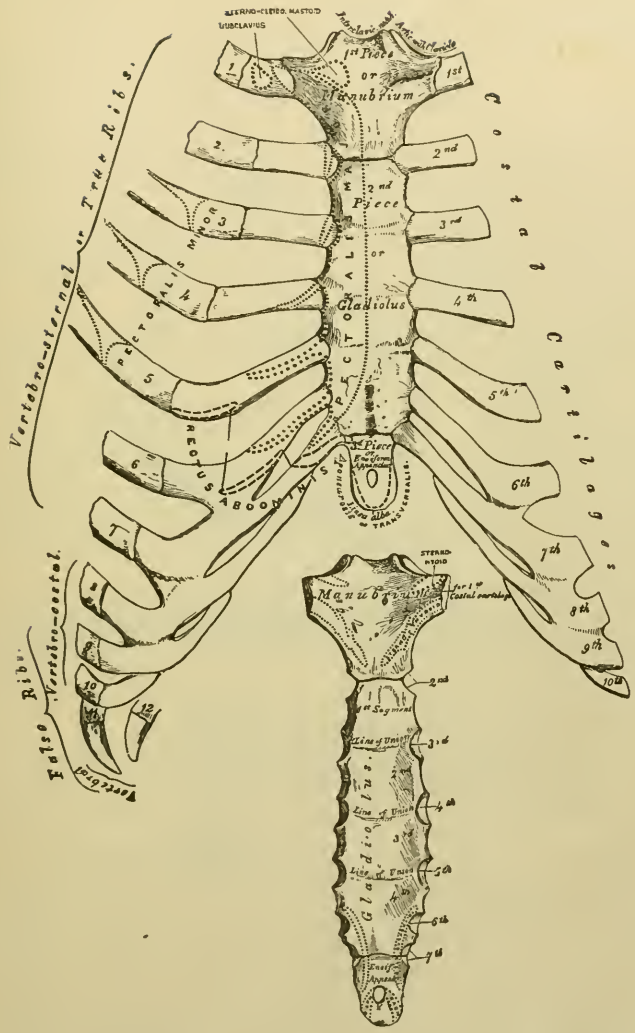

FIG. 31.

Sternum and costal cartilages.

Infraorbital foramen transmits infraorbital artery and nerve, and

Mental foramen transmits mental nerve and artery.

BONES OF THE TRUNK.

The sternum, or breast bone, is a long, narrow, sword-like bone occupying the anterior part of the thorax and consisting of three portions: manubrium (*manubrium sterni* or *presternum*—handle), gladiolus (*mesosternum* or *corpus sterni*—blade), xyphoid or ensiform appendix (*processus xiphoideus* or *metasternum*—point). Its anterior surface is irregularly flat, posterior surface slightly concave.

Manubrium sterni (*presternum*) is thick and triangular, and presents above the interclavicular notch, on either side of which are facets for articulation of clavicles. Laterally it presents an articular facet for the cartilage of the first rib and a half facet for part of second costal cartilage.

Gladiolus or corpus sterni (*mesosternum*) is the longest, narrowest portion and presents about its center, between the third and fourth segments, the *sternal foramen,* laterally facets for half of the second and for the third, fourth, fifth and sixth costal cartilages.

Ensiform appendix (*processus xiphoideus* or *metasternum*) is cartilaginous in youth and varies much in size and shape.

It *articulates* with the clavicles and seven costal cartilages on side.

Its ossific centers are six—one each for the manubrium and appendix and four for the gladiolus, or body.

Its muscular attachments are ten—sternomastoid, sternohyoid, sternothyroid, pectoralis major, triangularis sterni, obliquus externus and internus, transversalis, rectus and diaphragm.

The ribs (*costæ*), twelve on each side, form a series of narrow elastic arches on each side of the thorax, constituting the chief part of the thorax. They are divided into seven vertebrosternal, true or sternal ribs (*costæ veræ*), each of which joins the sternum by a separate costal cartilage; three vertebrochondral, or false (*costæ spuriæ*), the cartilages of which join each other and with the seventh before uniting with the sternum, and two *vertebral, free* or *floating,* which have no sternal attachment.

Each rib consists of a head, neck, tubercle and body.

The head (*capitulum costæ*) presents facet (except the first, tenth, eleventh and twelfth) for articulation with the bodies of

the contiguous dorsal vertebræ, separated by a ridge (*crista capituli*) for the interarticular ligament.

The neck (*collum costæ*) or constricted portion is smooth in front and presents a *rough surface* behind for the middle costotransverse ligament and a rough crest (*crista colli costæ*) above for the anterior costotransverse ligament.

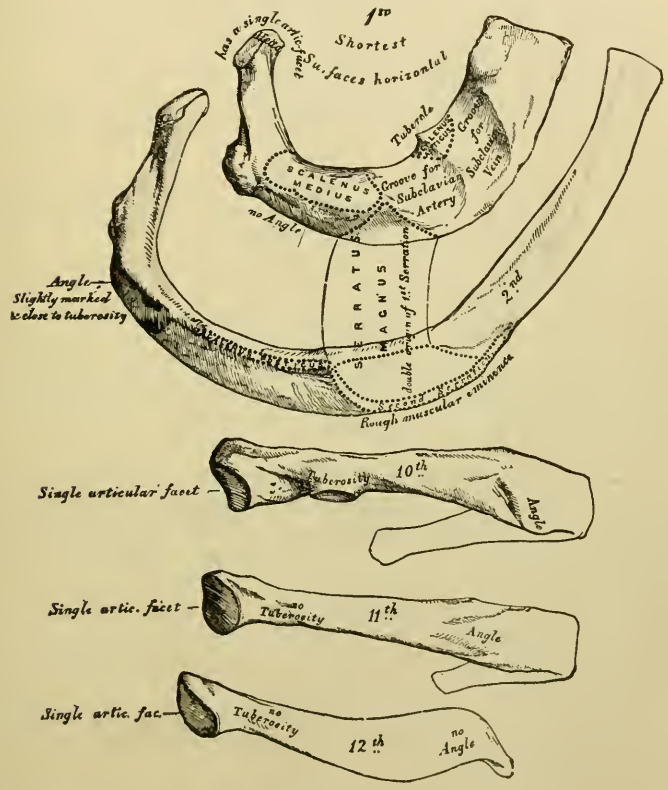

FIG. 32.

The peculiar ribs.

The tubercle or tuberosity (*tuberculum costæ*) (wanting in eleventh and twelfth), presents an articular surface (*facies articularis tuberculi*) for articulation with the transverse process of the vertebra below, and a non-articular surface for attachment of the posterior costotransverse ligament.

The shaft or body (*corpus costæ*) is flat, thin and twisted on itself. Its anterior extremity presents an *oval depression* for costal cartilage.

The *internal surface* is smooth, concave, and presents in front of the angle a *ridge,* forming the side of the groove on the inferior border.

The *external surface* is rough, convex and presents a little in front of the tubercle, a bend or angle (*angulus costæ*) marked by a prominent *line,* and near the sternal extremity another bend, the anterior angle, marked by an *oblique line.*

The *superior border* is round and thick and presents an *external* and *internal lip* for external and internal intercostal muscles.

The inferior border, at its posterior third, presents a groove (*sulcus costæ*) for the intercostal vessels and nerve, and at its anterior two-thirds is sharp and thin.

Peculiar Ribs.—The peculiar ribs are the first, second, tenth, eleventh and twelfth.

The *first* is short, broad, has no angle, and but one facet on the head. Its upper surface is marked by two parallel *grooves,* the anterior for the subclavian vein, the posterior for the artery separated by a tubercle (*tuberculum scaleni*) for insertion of scalenus anticus muscle,—an important guide in ligation of the subclavian artery.

The *second* resembles the first in being flattened and not twisted. The tubercle and angle are slight and almost coincide in position. The *outer surface* of the shaft presents near its middle a *rough eminence* for the second and third portions of the serratus magnus.

The *tenth* rib has but one facet for articulation with the tenth dorsal vertebra.

The *eleventh* has single facet on head, slight angle, but no tubercle or neck.

The *twelfth,* single facet, but no angle, tubercle, or neck.

The ribs articulate with twelve vertebræ behind and twelve costal cartilages in front.

Muscular attachments are twenty—scalenus anticus, medius and posticus, pectoralis minor, intercostals, serratus magnus, obliquus externus, transversalis, quadratus lumborum, diaphragm, latissimus dorsi, serratus posticus, superior and inferior; sacrolumbalis, musculus accessorius ad iliocostaleni, levatores costarum, longissimus dorsi, cervicalis ascendens, and infracostales.

Each rib has one center for its head, shaft and tubercle, except the eleventh and twelfth, which have but two centers, that for the tubercle being wanting.

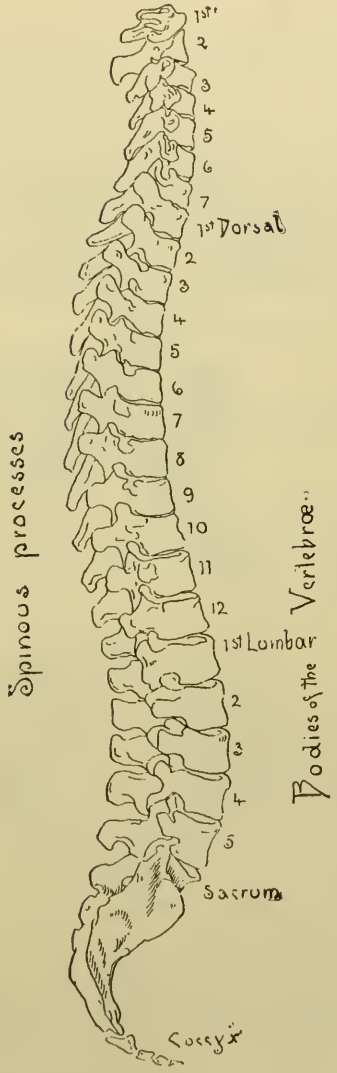

FIG. 33.

The vertebral column, or spine.

VERTEBRÆ.

THE SPINE, OR VERTEBRAL COLUMN (*columna vertebralis*), is a flexible column composed of twenty-six bones (thirty-three vertebræ), as follows: seven cervical, twelve dorsal, five lumbar, sacrum and coccyx. Each vertebra consists of a body or centrum (*corpus vertebræ*), and an arch (*arcus vertebræ*), composed of two pedicles and two laminæ, supporting seven processes —one spinous, two transverse and four articular.

The body (*centrum—corpus vertebræ*), the large, solid, anterior portion, is generally half-cylindrical, concave behind, convex in front and sides. Its upper and lower surfaces are

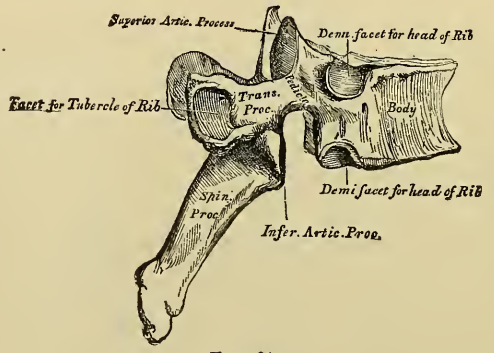

FIG. 34.

A dorsal vertebra.

broad and rough, for attachment of interarticular cartilages. Its posterior surface has large foramen for exit of veins.

The pedicles (*radix arcus vertebræ*) project backward (except the cervical, which project obliquely outward), and present four intervertebral notches (*incisura vertebralis superior et inferior*), two each, above and below. These, when articulated, form interarticular foramina (*foramina intervertebralia*) for exit of spinal nerves and passage of blood-vessels.

The *laminæ* are two broad, flat plates of bone, projecting backward and inward from the pedicles to complete the vertebral arch and inclose the spinal foramen. Their upper and lower margins are rough for attachment of the ligamenta subflava.

The *spinous processes* vary much in size and shape in the different regions. They project backward from the junction of the laminæ and afford attachment for muscles.

The transverse processes (*processus transversi*) project one on each side, from the junction of the laminæ with the pedicles, and in the cervical region from the sides of the body also, inclosing the foramen for the vertebral artery.

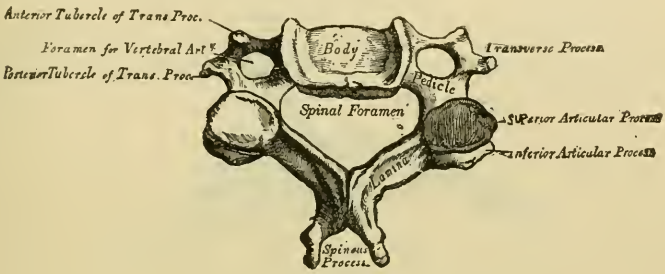

FIG. 35.

A cervical vertebra.

The articular processes (*zygapophyses*), four in number, project one above and below on each side, from the junction of the laminæ and pedicles. The two superior (*processus articularis superior*) project upward and more or less backward, the

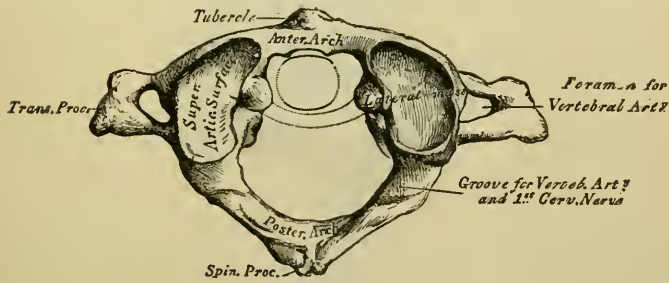

FIG. 36.

The atlas.

inferior (*processus articularis inferior*) downward and more or less forward, articulating with the corresponding processes of the adjoining vertebra.

The spinal foramen (*foramen vertebrale*) is a large, triangular canal, inclosed by the body in front, the pedicles laterally and the laminæ behind, for the passage of the spinal cord and its membranes.

The cervical vertebræ (*vertebræ cervicales*) are characterized by small body, concave above, convex below, the anterior margin overlapping the one below; short and bifid transverse process, perforated at base by foramen for vertebral artery;

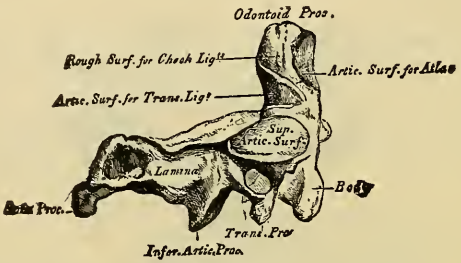

Fig. 37.

The axis.

oblique articular processes—superior convex directed upward and backward, inferior concave downward and forward; short spinous process, bifid, placed horizontally; long and narrow lamina, inclosing large, triangular spinal canal (*canalis vertebralis*).

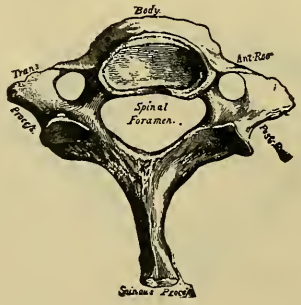

Fig. 38.

Seventh cervical, or vertebra prominens.

The *peculiar cervical vertebræ* are first, second and seventh.

The *first* or *atlas* is ring-like, without either body or spinous process, and consists of an anterior arch (*arcus anterior*), a posterior arch (*arcus posterior*) and two lateral masses (*massæ laterales*). The anterior arch, convex in front, presents tubercle for longus colli muscles and behind articulates with odontoid

process of axis. The posterior arch is deeply grooved above for transmission of vertebral artery and suboccipital nerves and terminates behind in a rudimentary spine. It articulates above with condyles of occipital, below with axis. The transverse process is short and contains a foramen.

The *axis* (*epistropheus*), so called from the pivot-like odontoid process (*dens*), which projects from the upper part of its body to articulate with the anterior arch and transverse ligament of atlas.

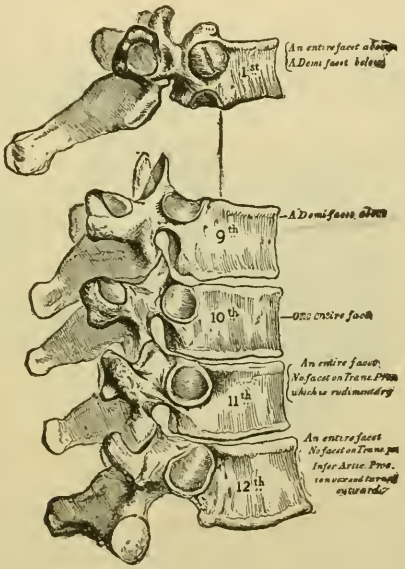

FIG. 39.

Peculiar dorsal vertebræ.

The *seventh* resembles the dorsal series; its spinous process being long, not bifid, and prominent; hence its name, "vertebra prominens." To it is attached the ligamentum nuchæ.

THE DORSAL VERTEBRÆ (*vertebræ thoracales*) have large, heart-shaped bodies, flat above and below. Laterally have demi-articular facets (*fovea costalis superior et inferior*) for heads of ribs; long, strong, transverse processes, marked by facet for tubercle of rib (*fovea costalis vertebralis*); vertical articular processes, superior backward, inferior forward; long, triangular, overlapping spinous process; small, and nearly circular, spinal canal.

The *peculiar dorsal vertebræ* are: first, which resembles cervical, and has distinct facet for head of first rib, and half-one for half of second head; tenth, eleventh and twelfth; one facet for head of rib; and eleventh and twelfth, no facet on transverse processes for tubercle of rib.

The LUMBAR VERTEBRÆ (*vertebræ lumbales*) are the largest, and have transverse oval body, flat above and below; long, thin, transverse processes, representing ribs; vertical processes interlocking with adjacent vertebræ; large, triangular spinal canal.

The *last lumbar* is *peculiar* in having body thicker in front, shorter and stronger transverse process, and inferior articular processes wider apart, and directed forward.

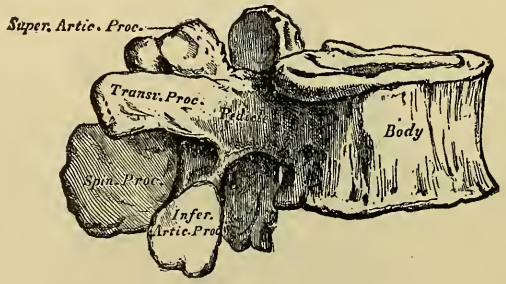

FIG. 40.

A lumbar vertebra.

Muscular attachments to *atlas,* ten—rectus anticus minor, rectus lateralis, rectus posticus minor, obliquus superior and inferior, splenius colli, levator anguli scapulæ, interspinous and intertransverse. To *axis,* ten—the last five of preceding, and obliquus inferior, rectus posticus major, semispinalis colli, multifidus spinæ, scalenus posticus and transversalis colli.

To the remaining vertebræ are attached anteriorly ten (10) muscles, and posteriorly twenty-two (22) [*vide* Spinal Muscles, p. 107].

Development.—The ossific centers for each vertebra are three primary, one for the body and one for each side, and five secondary epiphyses, as follows: one for tip of each spinous and transverse process, and the remaining two are thin plates on articular surfaces.

The exceptions to this rule are: atlas, with two primary centers and one epiphysis; the axis, with three extra centers for

odontoid process; the seventh cervical, with one extra center for each transverse process, and the lumbar vertebræ, two additional centers for tubercles.

THE SACRUM (*os sacrum*) is a large, wedge-shaped bone, base above, apex below, with expanded lateral masses and alæ, composed of five consolidated sacral vertebræ, and forming the posterior wall of pelvis.

The base (*basis oss. sacri*) articulates with the last lumbar vertebra. Its anterior edge forms the *promontory* or *sacrover-*

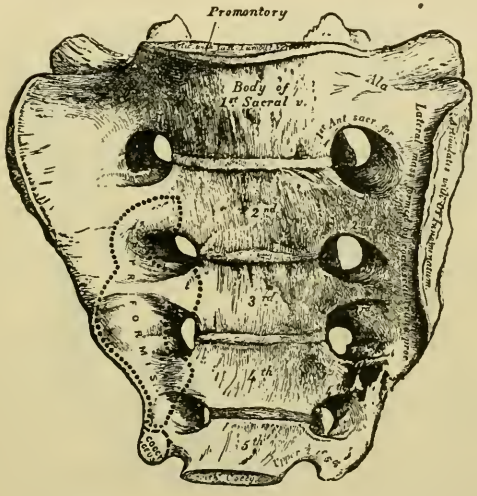

FIG. 41.

The sacrum, anterior surface.

tebral angle (*promontorium*) on each side of which is a smooth triangular surface, the ala (*ala sacralis*). Behind the articulating surface is the sacral canal (*canalis sacralis*), and on either side are the superior processes.

The apex (*apex oss. sacri*) is small and articulates with the coccyx.

The anterior concave surface (*facies pelvina*) presents four ridges (*lineæ transversæ*) indicating the original separations, which terminate externally in eight anterior sacral foramina (*foramina sacralia anteriora*), with wide, shallow *grooves*, for the exit of the anterior sacral nerves. To the outer side of these foramina is the lateral mass (*pars lateralis*) for origin of pyriformis muscle.

The posterior surface (*facies dorsalis*) presents rudimentary spinous articular and transverse processes, the laminæ of the last two segments being deficient.[1] On the other side of the spinous process is a broad, shallow concavity, the sacral groove, for the origin of the erector spinæ muscle, and external to the articular processes are four posterior sacral foramina (*foramina sacralia posteriora*) for the exit of posterior sacral nerves.

The *lateral surfaces* have each a rough *articular surface* for articulation, with ossa innominata, and below presents a deep

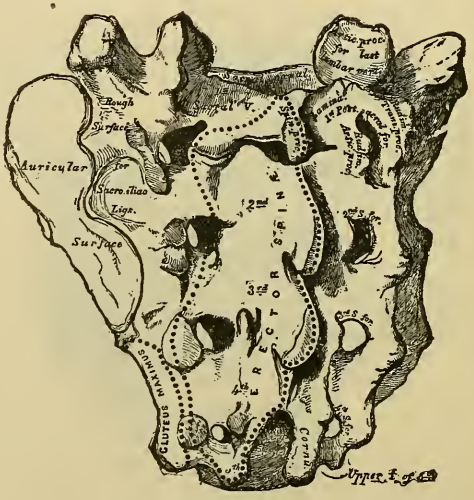

FIG. 42.

The sacrum, posterior surface.

notch on each side of the apex, which is converted by articulation with the transverse process of the coccyx into the fifth sacral foramen, for exit of anterior division of the fifth sacral nerve.

The sacral canal (*canalis sacralis*), continuous above with the spinal foramen of the vertebræ, runs through the center. Large and triangular above, small and flattened below, its lower posterior wall is deficient (*hiatus sacralis*). It lodges the sacral nerves, and out of it pass the anterior and posterior sacral foramina.

---

[1] The articular processes of the fourth and fifth unite to form the sacral cornua for articulation with the cornua of the coccyx.

It articulates with four bones,—two ossa innominata, last lumbar vertebra and coccyx.

Muscular attachments are seven—iliacus, pyriformis, coccygeus, gluteus maximus, latissimus dorsi, multifidus spinæ and erector spinæ.

Its *ossific centers* are thirty-five, as follows: bodies, including interarticular plates, three each (15); arches, two each (10); lateral masses, six (6); epiphyseal plates of lateral surfaces, four (4). Total, 35.

The coccyx (*os coccygis*) is a small triangular bone, resembling a cuckoo's beak, and composed of four rudimentary vertebræ more or less co-ossified (*vertebræ coccygeæ*).

The base articulates with the sacral apex, being prolonged upward into two cornua to complete the fifth posterior sacral foramen for exit of posterior branch of fifth sacral nerve.

Laterally the base is prolonged into rudimentary transverse processes, completing with the notch of the sacrum the fifth anterior sacral foramina for exit of the anterior branch of fifth sacral nerve.

The *anterior* concave *surface* supports the rectum and gives attachment to levator ani muscle and anterior sacrococcygeal ligament.

The *posterior* convex *surface* presents rudimentary, articular processes and transverse grooves.

The apex is rounded, occasionally bifid, or deviated to one side, and affords attachment to the levator ani and sphincter ani muscles.

The muscular attachments are coccygei, gluteus maximus, extensor coccygeus (occasionally present), levator and sphincter ani.

Its ossific centers are four—one for each segment.

THE UPPER EXTREMITY.

The upper extremity consists of the arm, forearm and hand. It is attached to the trunk by the shoulder-girdle formed by the clavicles and scapulæ and contains the following bones: Clavicle, scapula, humerus, radius, ulna, eight carpus, five metacarpus and fourteen phalanges.

The clavicle (*clavicula*), or collar- or key- bone, is a long bone, curved horizontally like the italic letter *f*, extending almost horizontally between the sternum and acromial process of scapula. Its inner two-thirds are cylindrical and convex in front, its outer third flattened from above downward and concave in front.

It consists of a body, or shaft, and outer, or acromial, and inner, or sternal extremities.

The *shaft* presents in its outer third the following points:—

Superior surface, rough *impression* in front for deltoid muscle, rough *impression* behind for trapezius;

Anterior border, occasionally *deltoid tubercle* about the center for attachment of deltoid;

Inferior surface, conoid tubercle (*tuberositas coracoidea*) at the posterior border for conoid ligament; *oblique line* extending outward and forward from this for attachment of trapezoid ligament.

The inner two-thirds is prismatic and presents three surfaces and three borders:—

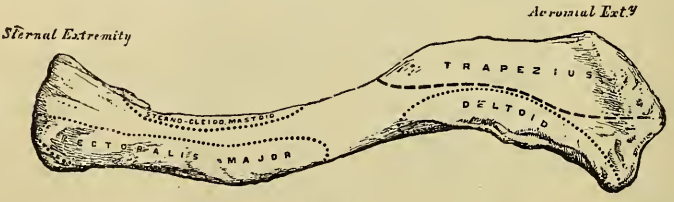

FIG. 43.

The left clavicle, upper surface.

Anterior surface, divided by *line* into upper rough surface for sternomastoid muscle and lower for pectoralis major;

Posterior or *cervical surface* gives attachment to sternohyoid muscle and presents foramen (*foramen nutricium*) for nutrient artery.

Inferior or subclavian surface presents:—

Facet, continuous with sternal articular surface, for cartilage of first rib;

Rhomboid impression (*tuberositas costalis*) for costoclavicular or rhomboid ligament;

Subclavian groove for attachment of subclavian muscle;

Longitudinal line, frequently dividing the groove into two parts, for intermuscular septum of the muscle.

Anterior border separates the anterior and posterior surfaces and limits the attachment of the pectoralis major.

Superior border gives attachment to the sternomastoid muscle.

Posterior or *subclavian border* is short and concave, extending from the rhomboid impression to the conoid tubercle and giving attachment to the *subclavian fascia.*

The acromial extremity (*extremitas acromialis*) presents an oval facet (*facies articularis acromialis*) for articulation with the acromial process of the scapula and a *rough circumference* for acromioclavicular ligaments.

The sternal extremity (*extremitas sternalis*) is triangular, and presents a facet (*facies articularis sternalis*) for cartilage of sternal articulation and *rough circumference* for sternoclavicular ligaments.

The clavicle articulates with three bones—the sternum, scapula, and first costal cartilage.

The muscular attachments are seven—subclavius, platysma, sternohyoid, sternomastoid, trapezius, pectoralis major and deltoid.

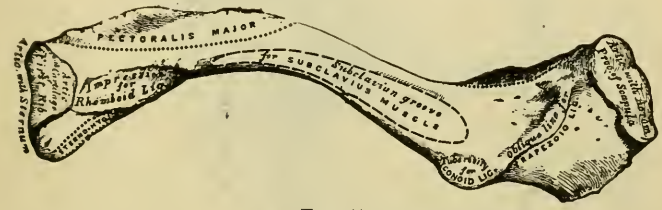

FIG. 44.

The left clavicle, under surface.

Its ossific centers are two—one each for body and sternal end.

THE SCAPULA, or *shoulder blade,* is a large, flat, triangular bone situated on the upper posterolateral aspect of the thorax from the second to seventh rib, inclusive.

It consists of a body, head, neck, acromion and coracoid processes, and presents two surfaces, three borders, and three angles.

The anterior surface, venter or costal surface (*facies costalis*) presents:—

Subscapular fossa (*fossa subscapularis*), a concave triangular surface for attachment of subscapular muscles, marked by

Oblique ridges (*lineæ musculares*) for the tendinous intersections of the muscle;

Marginal surface, for attachment of serratus magnus;

Subscapular angle (*angulus subscapularis*), a transverse depression at the upper part for the thickest part of the muscle.

The posterior surface, or dorsum (*facies dorsalis*), presents:—

Spine (*spina scapulæ*), a bony ridge passing upward, forward, and outward, dividing it unequally into two fossæ, affording attachment to the trapezius muscle above and the deltoid below, and terminating above in the *acromion process;*

Supraspinous fossa (*fossa supraspinata*) above the spine, for the origin of the supraspinatus muscle;

Infraspinous fossa (*fossa infraspinata*) below, for the origin of the infraspinatus muscle;

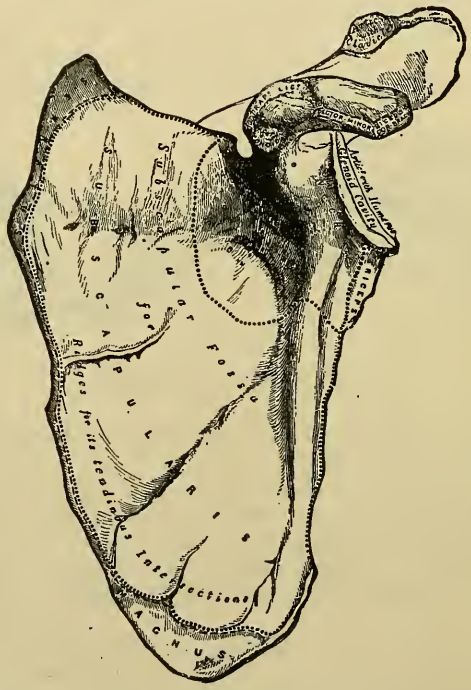

FIG. 45.

The scapula, anterior surface.

Nutrient foramen, near the upper part of the infraspinous fossa, for nutrient artery.

The *marginal surface* extends from the glenoid cavity downward and backward to an inch above inferior angle, its inner side formed by

An *elevated ridge,* for the attachment of the aponeurosis between the infraspinatus and two teres muscles; its outer side

by the axillary border. It is divided by an *oblique line* into two parts, the upper for the teres minor and the lower for the teres major muscles, and crossed by a *groove* near the upper part for the dorsalis scapulæ vessels;

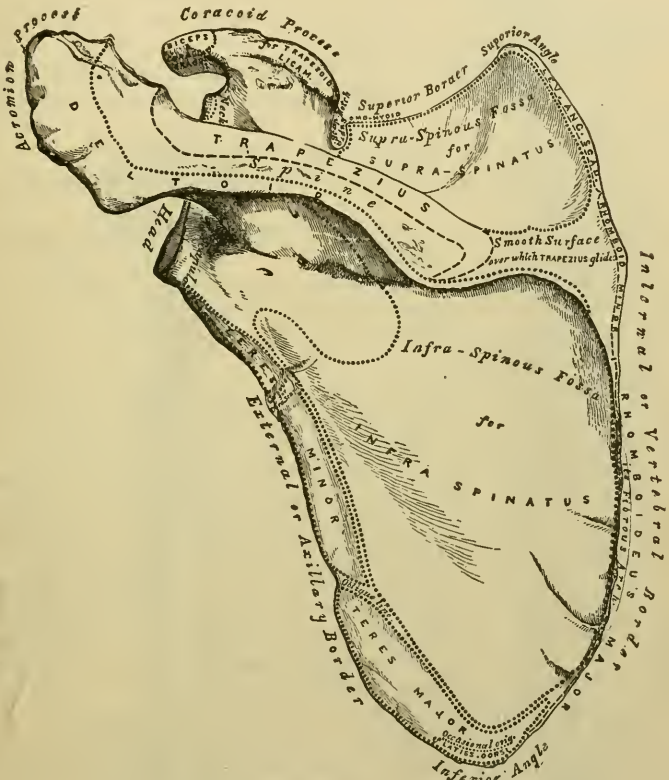

FIG. 46.

The scapula, posterior surface.

A *smooth*, triangular *surface* at the root of the spine over which the trapezius glides.

The superior border (*margo superior*), shortest, presents:—

Suprascapular notch (*incisura scapulæ*) at the base of the coracoid process, converted into a *foramen* [suprascapular] by the transverse ligament, for the passage of the suprascapular nerve (the artery passing above);

Origin of omohyoid muscle from this border just internal to notch.

External or axillary border (*margo axillaris*), thickest, presents:—

Rough impression, the infraglenoid tubercle (*tuberositas infraglenoidalis*), just below glenoid cavity, for origin of long head of triceps muscle, and below

Longitudinal groove, for origin of part of subscapularis.

Internal, veretebral border—base (*margo vertebralis*), longest, presents:—

Anterior lip, for insertion of serratus magnus;

Posterior lip, for attachment above of supraspinatus, below infraspinatus.

The superior angle (*angulus medialis*) gives attachment to part of levator anguli scapulæ;

The *inferior angle* (*angulus inferior*), for attachment of teres major, and sometimes part of latissimus dorsi.

The anterior or external angle (*angulus lateralis*) is thickest, and forms the head.

The *head* is connected to the body of the scapula by a constricted portion, the neck (*collum scapulæ*), from the anterior surface of which arises the coracoid process. It presents

The glenoid cavity or fossa (*cavitas glenoidalis*), a shallow, pyriform, articular depression, deepened in the recent state by the glenoid ligament, for the head of the humerus. To its upper part or apex is attached the long head of the biceps muscle.

The acromion process (*acromion*), forming the summit of the shoulder, is a triangular process, projecting forward, outward and upward, to overarch the glenoid cavity. It gives attachment by its upper surface to the platysma and deltoid and by its inner margin to the trapezius. It presents

An *apex,* for attachment of coracoacromial ligament;

Articular facet, just behind the apex for the clavicle.

The coracoid process (*processus coracoideus*)—like a crow's beak—arches forward, upward, and inward above the glenoid cavity. It presents

Attachment for pectoralis minor muscle from the anterior border near the tip;

Apex, for attachment of coracobrachialis and short head of biceps;

Rough impression at the inner side of the root for the conoid ligament, and from it

A *ridge* running outward and forward for the trapezoid ligament.

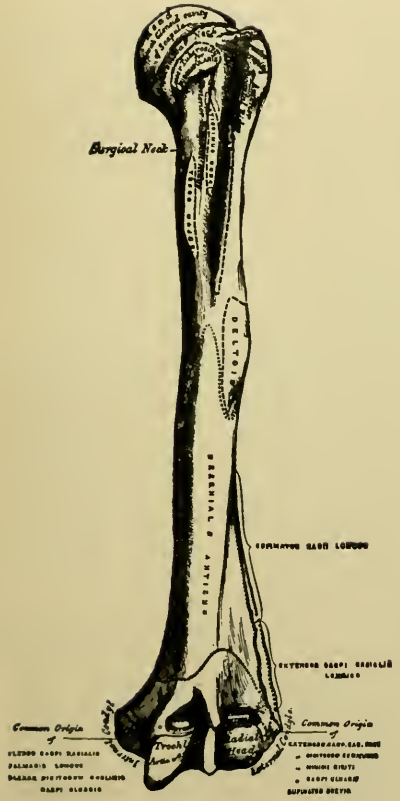

FIG. 47.

The humerus, anterior surface.

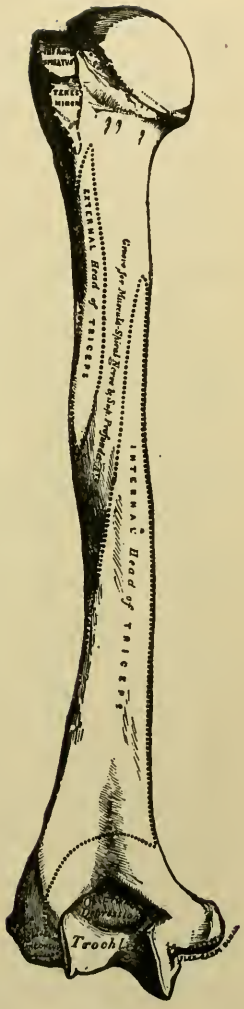

FIG. 48.

The humerus, posterior surface.

It articulates with the clavicle and humerus.

Its muscular attachments are 18: platysma, supra- and infra- spinatus, subscapular, deltoid, trapezius, omohyoid, serratus magnus, levator anguli scapulæ, rhomboideus major and minor, triceps, teres major and minor, biceps, coracobrachialis, pectoralis minor and latissimus dorsi.

Its ossific centers are seven—one each for body, posterior border, and inferior angle, and two each for acromion and coracoid processes.

THE HUMERUS, OR ARM BONE, the largest and longest bone of the upper extremity, consists of a shaft, head, neck, greater and lesser tuberosities and lower extremity.

The shaft (*corpus humeri*), cylindrical above, flattened and prismoid below, becomes twisted in the middle, and presents

A *rough triangular surface* about the middle of its outer surface (*tuberositas deltoidea*) for insertion of the deltoid muscle, and a

Musculospiral groove for the musculospiral nerve and superior profunda artery, on each side of which arise the external and internal heads of the triceps muscle.

The *upper extremity* presents

The head (*caput humeri*) forming nearly a sphere, projecting upward, backward and inward, articulating with the glenoid cavity;

The anatomical neck (*collum anatomicum*), immediately beneath, is slightly *grooved* for the attachment of the capsular ligament;

Greater tuberosity (*tuberculum majus*), external to the head and lesser tuberosity, with three facets from before backward for attachment of supraspinatus, infraspinatus and teres minor muscles;

Lesser tuberosity (*tuberculum minus*), smaller but more prominent than greater, is anterior to head, for the subscapular muscle;

Bicipital groove (*sulcus intertubercularis*), passes downward and inward between the two tuberosities and lodges the long tendon of biceps;

The anterior bicipital ridge (*crista tuberculi minoris*), bounds the groove in front and receives insertion of pectoralis major muscle;

The posterior bicipital ridge (*crista tuberculi majoris*), receives the latissimus dorsi and teres major;

The surgical neck (*collum chirurgicum*), including the head, neck and both tuberosities;

A *rough impression* near the center of the inner border for the coracobrachialis muscle;

Nutrient canal, below and directed toward the lower extremity.

The *lower extremity* presents from within outward the following[1]:—

Internal condyloid ridge, extending upward from the condyle;

Internal condyle or epicondyle (*epicondylus medialis*), more prominent than external, gives origin to the flexors and pronator radii teres;

Epitrochlea, an eminence separating the trochlea from the internal condyle;

Trochlea (*trochlea humeri*) a pulley-like articulating surface for greater sigmoid cavity of ulna;

Coronoid fossa (*fossa coronoidea*) a small depression bounding the trochlea in front, and receiving the coronoid of the ulna in flexion;

Olecranon fossa (*fossa olecrani*), a larger depression behind, and receiving the olecranon process of ulna in extension;

Supratrochlear foramen, sometimes formed by perforation of one fossa into the other;

Radial head, or capitellum (*capitulum humeri*), a smooth, rounded eminence articulating with cup-like depression on head of radius;

External condyle or epicondyle (*epicondylus lateralis*), less prominent, gives origin to the extensors and supinators;

External condyloid ridge, extending upward on the shaft from the condyle.

It articulates with three bones—scapula, radius and ulna.

Its muscular attachments are twenty-five—subscapularis, supra- and infra- spinatus, teres major and minor, pectoralis major, latissimus dorsi, deltoid, coracobrachialis, brachialis anticus, triceps, pronators and flexors to inner condyle, pronator radii teres, flexor carpi radialis, palmaris longus, flexor sublimus digitorum, flexor carpi ulnaris, supinators and extensors to outer condyle, supinator longus, extensor carpi radialis longior and brevior, extensor communis digitorum, extensor minimi digiti,

---

[1] Some confusion exists in anatomical works because of the loose employment of the terms *condyle, epicondyle,* and *epitrochlear.* It should be borne in mind, however, that many anatomists use the terms *external condyle* and *external epicondyle* synonymously, while others designate the inner condyle as the internal epicondyle or epitrochlea.

extensor carpi ulnaris, anconeus and subanconeus, supinator brevis.

Its ossific centers are seven—one each for head, shaft, tuberosities, condyles, radial head, and trochlear portion.

THE ULNA, or elbow bone, is a long bone to the inner side of the forearm, and consists of a shaft and an upper and lower extremity. It forms the greater part of the articulation with the humerus, but does not enter into the formation of the wrist-joint, being excluded by the interarticular fibrocartilage.

The shaft (*corpus ulnæ*) is prismatic above, smooth and rounded below, and presents:—

Anterior or palmar surface (*facies volaris*), gives attachment to the deep flexors and pronator quadratus;

Nutrient foramen (*foramen nutricium*) on anterior surface, directed upward toward the elbow-joint;

Posterior or dorsal surface (*facies dorsalis*) marked above by an *oblique line* for part of supinator brevis, above which is smooth triangular surface for anconeus muscle, and the lower third for extensor muscles of the thumb;

External or interosseous border (*crista interossea*), sharp in middle two-thirds, for attachment of interosseus membrane.

The *upper extremity* is large and irregular, and presents:—

Olecranon process (*olecranon*—head of elbow), projects upward and forward, its apex being received into the olecranon fossa of the humerus in extension of the forearm; its upper border has rough impression for the triceps muscle; its lateral borders are grooved for external and internal lateral ligaments;

Coronoid process (*processus coronoideus*), smaller than olecranon, projects forward from anterior surface, being received into coronoid fossa of humerus in flexion.

Its *upper surface* forms part of the great sigmoid cavity.

Its *under surface* has rough impression for insertion of brachialis anticus, and has, at its junction with the shaft, the tubercle of the ulna (*tuberositas ulnæ*) for the oblique ligament.

Its *outer surface* is the lesser sigmoid cavity.

Its *inner surface* gives attachment to the internal lateral ligament, and the flexor digitorum sublimis, flexor profundus digitorum, and one head of pronator radii teres.

Greater sigmoid cavity (*incisura semilunaris*) is a large, semilunar depression between the olecranon and coronoid processes, divided into two unequal lateral parts by an elevated ridge. It is continuous on the outer side with the lesser sigmoid cavity and articulates with the trochlear surface of the humerus.

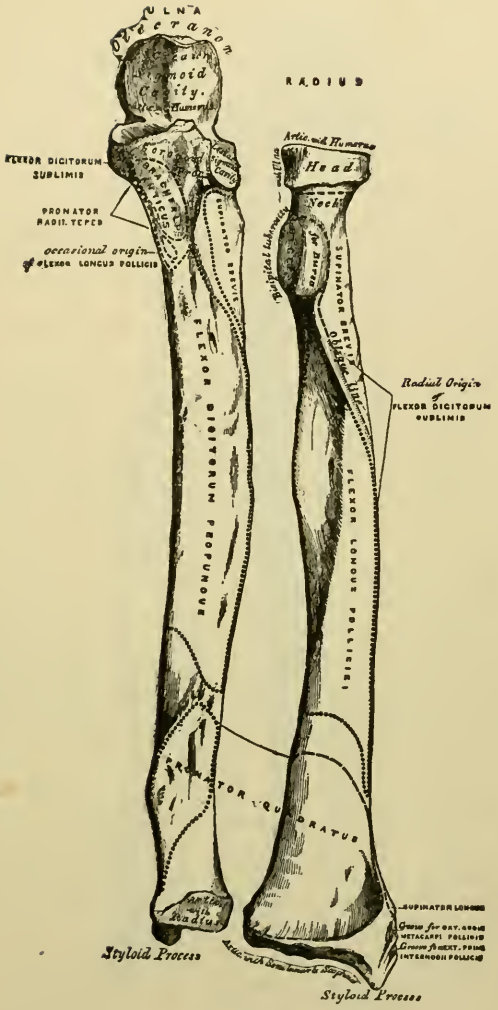

FIG. 49.

Ulna and radius, anterior aspect.

Lesser sigmoid cavity (*incisura radialis*) is an oval, concave, articular depression, external to the coronoid process, for articulation with the head of the radius. Its prominent extremities give attachment to the orbicular ligament.

The lower extremity is small and cylindrical and presents:—

Head (*capitulum ulnæ*), an external, rounded, articular process, for the triangular fibrocartilage below and the sigmoid cavity of the radius externally;

Styloid process (*processus styloideus*) projects from the posterior and internal part of the extremity, its apex gives attachment to the internal lateral ligament of the wrist, and it is marked at its root by a depression between it and the head, for attachment of the fibrocartilage;

Groove, upon the posterior surface, for passage of extensor carpi ulnaris.

It articulates with two bones—humerus and radius.

Its muscular attachments are sixteen—brachialis anticus, triceps, anconeus, flexor and extensor carpi ulnaris, pronator radii teres, flexor sublimus and profundus digitorum, pronator quadratus, supinator brevis, extensor indicis, extensor ossis metacarpi, extensor secundi internodii pollicis and flexor longus pollicis.

Its ossific centers are three—one each for shaft, olecranon and inferior extremity.

The radius is a long bone, shorter than the ulna, situated on the outer side of the forearm, the upper end small, the shaft slightly curved, and the lower end expanded to form part of the wrist joint. It consists of shaft, upper and lower extremity.

The shaft (*corpus radii*) is prismoid, slightly curved, and presents

An internal or interosseous border (*crista interossea*), sharp and prominent, for interosseous membrane;

An anterior or palmar border (*margo volaris*) marked at its upper third by an *oblique line,* for attachment of flexor longus pollicis, supinator brevis and flexor sublimis digitorum;

Anterior, palmar, or flexor surface (*facies volaris*), affords attachment above for flexor longus pollicis, below for pronator quadratus, and presents at the junction of middle and upper two-thirds a *nutrient foramen* directed upward;

Posterior, dorsal, or extensor surface (*facies dorsalis*) gives attachment at upper third to supinator brevis, and at middle third to extensors of thumb.

The *upper extremity* presents:—

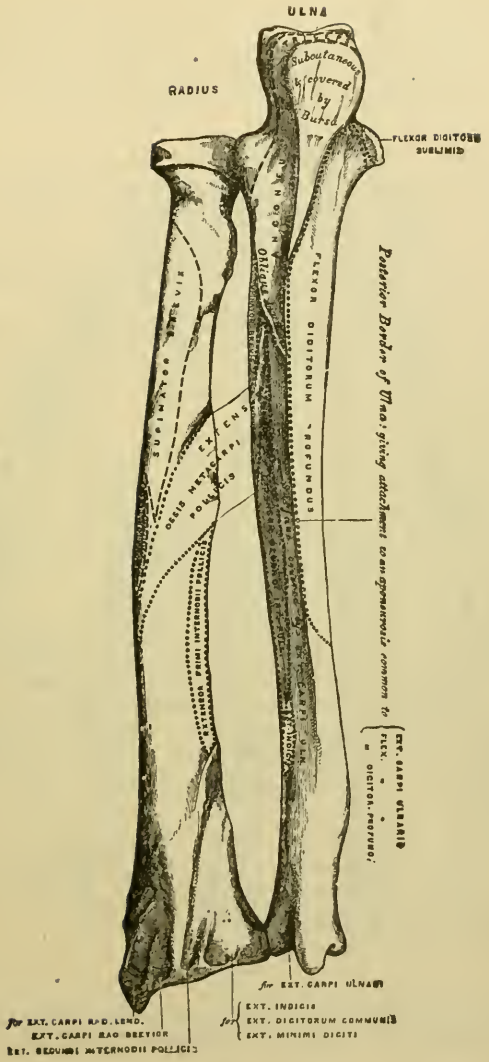

FIG. 50.

Radius and ulna, posterior aspect.

Head (*capitulum radii*)—a cup-like cylindrical cavity, for articulation with capitellum of humerus, and on its side an articulating surface for lesser sigmoid cavity of ulna and orbicular ligament, which nearly surrounds it;

Neck (*collum radii*), the constricted portion below the head;

Bicipital tuberosity (*tuberositas radii*), below and to inner side, divided by a vertical line into a rough surface posteriorly, for attachment of biceps tendon, and smooth surface anteriorly for bursa.

The *lower extremity,* large, expanded and quadrilateral presents:—

Carpal articular surface (*facies articularis carpea*), smooth, concave, triangular depression divided by an anteroposterior ridge into an outer facet for scaphoid bone and inner for semilunar;

Sigmoid cavity (*incisura ulnaris*), a shallow concavity at inner side of carpal end, for articulation with ulnar head;

Styloid process (*processus styloideus*), projects obliquely downward from the external surface, for attachment by its apex to external lateral ligament of wrist joint, and by its base to insertion of supinator longus muscle. Its outer surface is marked by two *grooves* for extensors of thumb;

The *posterior surface* of the lower extremity is also marked by three *grooves* from without inward for the following: ext. carpi radialis longior and brevior in first, ext. secundi internodii in second, and ext. indicis, ext. communis digitorum, and ext. minimi digiti in third innermost. This surface has also attachment of posterior ligament of wrist.

It articulates with four bones—humerus, ulna, scaphoid and semilunar.

Its muscular attachments are nine—biceps, supinator longus and brevis, flexor digitorum sublimis, flexor longus pollicis, pronator quadratus, extensor ossis metacarpi pollicis, ext. primi internodii pollicis and pronator radii teres.

Its ossific centers are three—one each for shaft and each extremity.

The Hand.—The bones of the hand consist of eight carpus, five metacarpus, and fourteen phalanges; total, twenty-seven bones.

The carpus (*ossa carpi*) consist of eight small bones arranged in two rows—first, or proximal row, from the radial side inward are scaphoid, semilunar, cuneiform and pisiform; the

second, or distal row, in same order are trapezium, trapezoid, os magnum and unciform.

Scaphoid (*os naviculare manus*—boat-shaped), largest of first row, convex above, concave below, articulates with five bones,

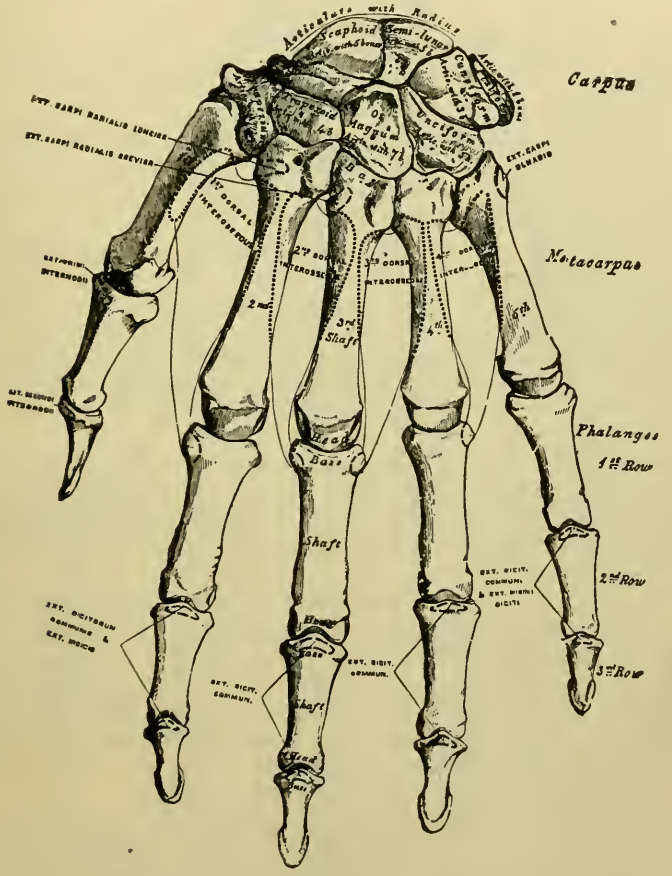

Fig. 51.

Carpus, metacarpus, and phalanges, dorsal surface.

as follows: superior surface, with radius; inferior, with trapezium and trapezoid; internal, with semilunar above and os magnum beneath. The external surface has attachment of external lateral ligament of wrist.

Semilunar (*os lunatum*—half-moon), crescentic in outline, presents articulating surfaces for five bones, as follows: superior convex surface with radius, inferior concave facet with os magnum and unciform, quadrilateral internal facet with cuneiform, and external with scaphoid.

Cuneiform (*os triquetrum*) is wedge-shaped, the base, directed outward, articulates with the semilunar, apex with the interarticular fibrocartilage of wrist joint, inferior surface with unciform, and anterior with pisiform; in all, three bones.

Pisiform (*os pisiforme*—pea-like) is a small, pea-shaped bone articulating with anterior surface of cuneiform, and affording attachment to annular ligament and two muscles, flexor carpi ulnaris, abductor minimi digiti.

Trapezium (*os multangulum*—a table), a very irregular bone, articulates above by concave surface with scaphoid; below, by surface concave from side to side, convex from before backward, with first metacarpal; by internal surface with trapezoid, inferior with second metacarpal. Its dorsal surface is rough; its palmar grooved by flexor carpi radialis tendon. Muscular attachments are three—flexor ossis metacarpi, flexor brevis pollicis and abductor pollicis.

Trapezoid (*os multangulum minus*), smallest of second row, is wedge-shaped, apex palmar; articulates with four bones—superior surface with scaphoid, inferior with second metacarpal, external with trapezium, internal with os magnum and interosseous ligament.

It has one muscular attachment for flexor brevis pollicis.

Os magnum, or capitate (*os capitatum*), the largest carpal bone, consists of a body, neck, and *head*. The latter projects from the superior surface and articulates with the scaphoid and semilunar. The inferior surface articulates with second, third, and fourth metacarpal bones; the external with trapezoid, and internal with unciform; in all seven bones.

Muscular attachment for flexor brevis pollicis.

Unciform (*os hamatum*—hook-like), a wedge-shaped bone, so named from the hook-like process (*hamulus ossis hamati*) projecting from its anterior surface, below its articulation with fourth and fifth metacarpals, and above its articulation with semilunar. This process gives attachment to annular ligament, flexor brevis minimi digiti, flexor ossis metacarpi minimi digiti, and is grooved for passage of other flexor tendons. External surface articulates with os magnum and internal with cuneiform.

Muscular attachments are those to unciform process. Each carpal bone is developed from a single ossific center.

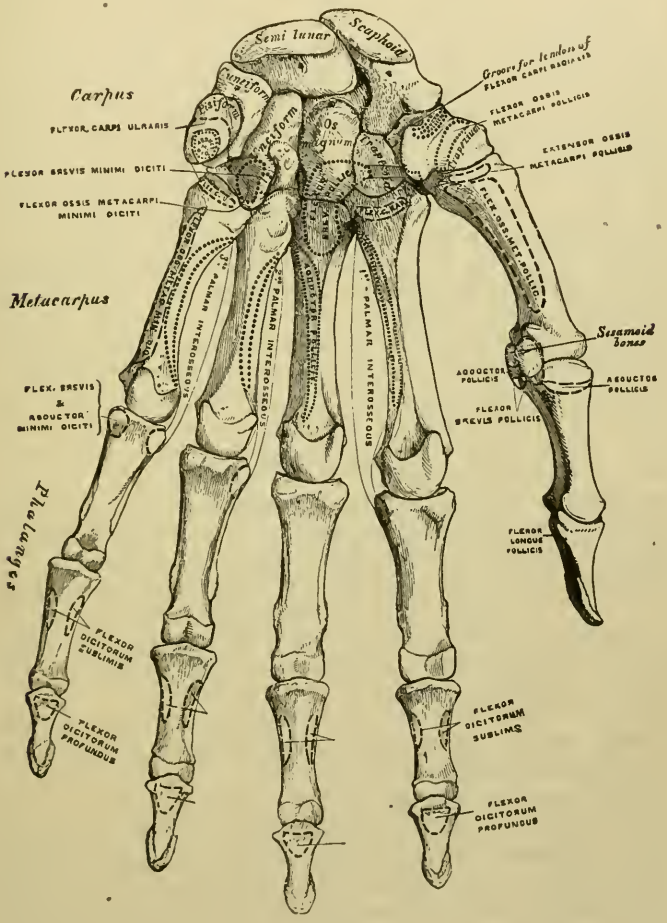

FIG. 52.

Carpus, metacarpus, and phalanges, palmar surface.

Table of Articulations of Carpal Bones.—Scaphoid, 5; semilunar, 5; cuneiform, 3; pisiform, 1; trapezium, 4; trapezoid, 4; os magnum, 7; unciform, 5.

The metacarpus (*ossa metacarpalia*) are five long bones, resembling each other, and presenting a shaft (*corpus*) and two extremities. Anterior surface is concave, posterior convex; superior, carpal or proximal extremity or base (*basis*), irregular for articulation with carpal bones and with the adjoining bones; inferior, digital or distal extremity or head (*capitulum*), presents rounded head for articulation with phalanges. The first metacarpal (*os metacarpale I*), for thumb is supported on trapezium, articulates with first phalanx, and has four muscles attached—first dorsal interosseus, flexor, and extensor ossis metacarpi pollicis and the flexor brevis pollicis; the second metacarpal (*os metacarpale II*) by three, trapezium, trapezoid and os magnum, articulates also with third metacarpal and second phalanx, and has six muscles attached—first and second dorsal interosseus, first palmar interosseus, flexor carpi radialis, and extensor carpi radialis longior and the adductor obliquus pollicis; the third metacarpal (*os metacarpale III*) supported by os magnum, articulates also with second and fourth metacarpal and third phalanx, and has six muscles attached—flexor carpi radialis, adductor obliquus pollicis, extensor carpi radialis brevior, adductor pollicis, and second and third dorsal interosseus. The fourth metacarpal (*os metacarpale IV*) is supported on os magnum and unciform, articulated with third and fifth metacarpal and fourth phalanx, and has three muscles attached—second palmar and third and fourth dorsal interosseus. The fifth metacarpal (*os metacarpale V*) supported on unciform, articulates with fourth metacarpal and fifth phalanx, and has five muscles attached—flexor ossis metacarpi minimi digiti, flexor and extensor carpi ulnaris, and fourth dorsal and third palmar interosseus.

Ossific centers are two for each bone, one each for shaft and head, except thumb, which has one each for shaft and base, resembling the phalanges.

Phalanges of the Hand (*phalanges digitorum manus*). —Each finger has three phalanges (*internodia*), except the thumb, which has but two. Palmar surface concave, dorsal convex; the superior extremity articulates with head of metacarpal, and the inferior, concave from side to side, convex from before backward, articulates with second phalanx, which presents an opposite arrangement, except in the thumb, where it articulates with ungual or terminal phalanx.

[Phalanges as a generic term is translated, *internodia;* when applied to the phalanges of the hand, *phalanges digitorum*

manus, in contradistinction to the phalanges of the foot, *phalanges digitorum pedis.*]

The second phalangeal articulation is the same, and the ungual phalanx presents a rough, arrow-shaped extremity.

The muscular insertions to the *first row* are: to thumb four, flexor brevis, abductor and adductor pollicis, and extensor primi internodii; to index two, first palmar and dorsal interosseus; to middle two, second and third dorsal interossei; to ring, two, second palmar and fourth dorsal interosseus; to little three, flexor brevis and abductor minimi digiti and third palmar interosseus.

The insertions to *second row* are: extensor secundi internodii and flexor longus pollicis; and to each of the others four, extensor communis digitorum, flexor sublimis digitorum, with the addition of extensor indicis to index and extensor minimi digiti to little.

The insertions to *third row* are: extensor communis digitorum and flexor profundus.

Ossific centers are two for each bone, one each for shaft and base.

THE LOWER EXTREMITY.

The lower extremity consists of the thigh, leg, and foot. It is connected to the trunk by the pelvic girdle formed by the hip bones and sacrum, and contains the following bones: os innominatum, femur, patella, tibia, fibula, seven tarsus, five metatarsus and fourteen phalanges.

THE OS INNOMINATUM, or hip bone, is a large, irregular bone forming the lateral and anterior walls of the pelvis, and consisting of three bones, ilium, ischium and pubes, united about puberty. It presents

The *acetabulum* or *cotyloid cavity,* a deep, cup-shaped cavity, for articulation of the head of the femur—the ischium forming a little more than two-fifths, the ilium a little less than two-fifths, and the pubes one-fifth. The bottom of the cavity presents a circular depression (*fossa acetabuli*), lodging a mass of fat, and giving attachment by its edges to the ligamentum teres, and continuous below with a deep notch, the cotyloid notch (*incisura acetabuli*), for attachment of cotyloid and part of ligamentum teres, converted into a foramen by the transverse ligament for the entrance of the nutrient vessels and nerves. The margin of the acetabulum is deepened by a fibro-cartilaginous ring.

The obturator, or thyroid, foramen (*foramen obturatum*) is

an aperture large and ovoidal in the male, small and triangular in the female, situated on the anterior inferior surface between the ischium and pubes. It is closed, in the recent state, by a strong membrane attached to its margins except above externally, where a foramen exists for obturator vessels and nerve.

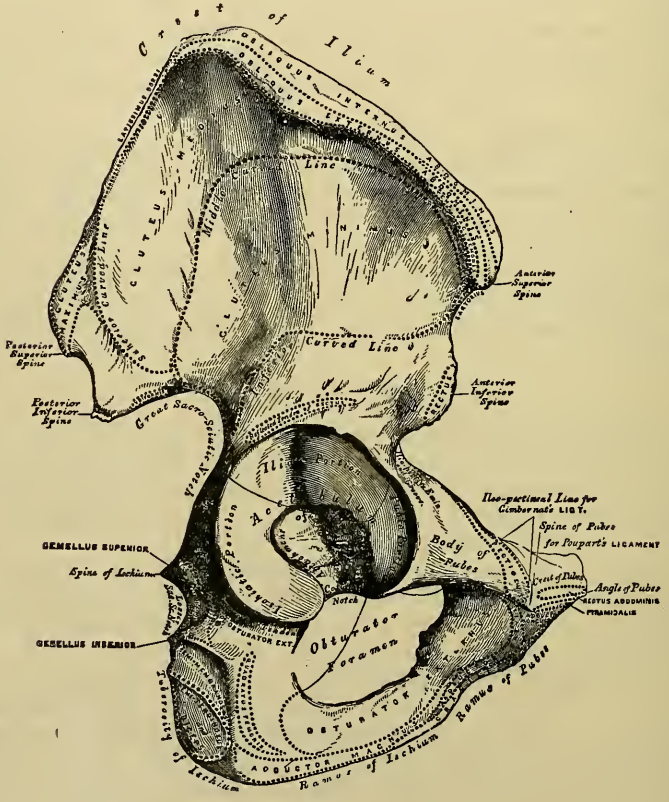

FIG. 53.

Os innominatum, outer surface.

THE ILIUM (*os ilium*), broad, flat, and triangular, forms the greater part of the bone, its base above, its apex at the acetabulum.

The *external surface,* or *dorsum,* concave in front and behind, presents from below upward

A *groove*, just above the acetabulum, for the reflected tendon of the rectus femoris muscle;

The inferior curved line, or inferior gluteal line (*linea glutea inferior*), marking the lower border of the gluteus minimus;

The middle curved line, or anterior gluteal line (*linea*

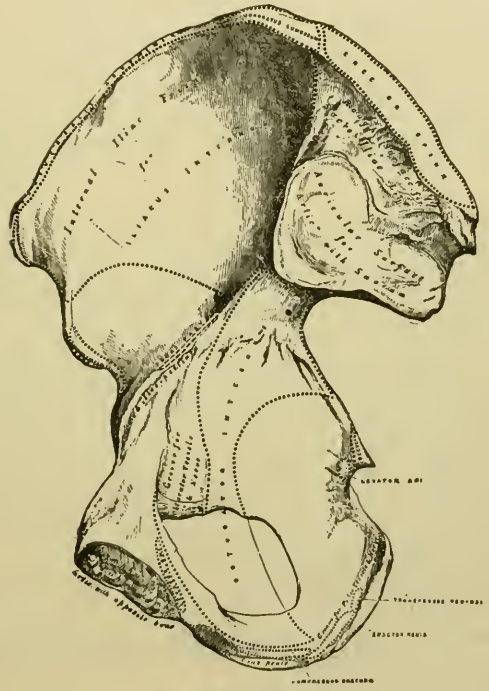

FIG. 54.

Os innominatum, inner surface.

glutea anterior), the longest of the three, marking the lower border of the gluteus medius; and

The superior curved line, or posterior gluteal line (*linea glutea posterior*), the shortest, marks the lower anterior border of the gluteus maximus, and from the surface below which arise a few fibers of the pyriformis.

The *upper* expanded *border* forms the crest of the ilium (*crista iliaca*), terminating in front in

The anterior superior spinous process (*spina iliaca anterior superior*), giving origin to the sartorius and tensor vaginæ femoris muscles and Poupart's ligament, below which is

The anterior inferior spinous process (*spina iliaca anterior inferior*), for the iliofemoral ligament, and the straight tendon of the rectus femoris muscle; and behind in

The posterior superior spinous process (*spina iliaca posterior superior*), for the oblique band of the sacroiliac ligament, and part of the multifidus spinæ muscle, below which is

The posterior inferior spinous process (*spina iliaca posterior inferior*), for attachment of the great sacrosciatic ligament.

Between the superior and inferior spinous processes, both anteriorly and posteriorly, is a *notch,* the former for partial attachment of the sartorius and passage of the external cutaneous nerve.

The *internal* concave *surface,* or *venter,* presents

The internal iliac fossa (*fossa iliaca*), lodging the iliacus muscle, and having a nutrient foramen at its lower part;

Iliopectineal line (*linea arcuata*), limiting the fossa below, and separating the false from the true pelvis;

Rough surface, divided into two parts—the posterior portion (*tuberositas iliaca*), for posterior sarcoiliac ligaments, and lower auricular or anterior surface (*facies auricularis*) for articulation with sacrum.

The ischium (*os ischii*) forms the outer back part of pelvis, and consists of a body, tuberosity, and ascending ramus.

The *external surface* of the body forms a little more than two-fifths of the acetabulum, and presents

A groove (*sulcus obturatorius*) below, for the tendon of the obturator externus.

The *internal surface* is concave and smooth, and forms the lateral wall of the true pelvis.

The *posterior border* presents

The spine (*spina ischiadica*) of the *ischium,* projecting downward, backward, and inward, from below the center for attachment of the gemellus superior, coccygeus, and levator ani muscles, and lesser sacrosciatic ligament;

Great sacrosciatic notch (*incisura ischiadica major*), a deep notch above the spine converted into a foramen (*foramen ischiadicum majus*), by the lesser sacrosciatic ligament, transmitting the pyriformis muscle, superior gluteal nerve, gluteal vessels, sciatic vessels and nerves, and the internal pudic vessels and nerves;

Lesser sacrosciatic notch (*incisura ischiadica minor*), below the spine, and between it and the tuberosity, converted into a foramen (*foramen ischiadicum minus*) by the great sacrosciatic ligament, transmitting the obturator internus muscle and nerve, the internal pudic vessels and nerves. The lowest portion of the body presents

Tuberosity (*tuber ischiadicum*), with

Outer lip, for attachment of part of adductor magnus and quadriceps femoris;

Inner lip, for part of great sacrosciatic ligament, erector penis, and transversus perinæi;

Groove, on inner lip, for internal pudic vessels and nerve;

Intermediate surface, for semimembranosus, semitendinosus, biceps, adductor magnus, gemellus inferior and great sacrosciatic ligament.

The ascending or inferior ramus (*ramus inferior ossis ischii*) passes upward and inward from the tuberosity to join the descending ramus of the pubes, forming part of the inner margin of the obturator foramen. It gives attachment to gracilis, obturator externus, part of adductor magnus, erector penis and transversus perinæi;

The pubes (*os pubis*) forms the anterior part of the pelvis and consists of a body, horizontal ramus, and descending ramus.

The body (*corpus ossis pubis*) is quadrilateral, and presents

An *anterior surface,* for attachment of adductor longus and brevis, and part of gracilis, adductor magnus and obturator externus;

Posterior surface, forming anterior wall of true pelvis and giving attachment to levator ani and part of obturator internus;

Spine (*tuberculum pubicum*), upon the upper border, for Poupart's ligament and outer pillar of external abdominal ring;

Iliopectineal line (*linea arcuata*), continuous with that on ilium;

Crest, along the upper border, internal to the spine;

Angle, at the junction of the inner border with the crest and giving attachment to internal pillar of external ring;

Symphysis, the internal oval border roughened by several ridges for articulation with opposite bone.

The ascending or superior ramus (*ramus superior ossis pubis*) joins the ilium, forming the upper part of the obturator foramen, and presents at its lower border a

Groove, for the obturator vessels and nerve.

The descending or inferior ramus (*ramus inferior ossis*

pubis) is flat and thin, and joins the ascending ramus of the ischium.

Each innominate bone *articulates* with three bones—the sacrum, femur, and its fellow of the opposite side.

Its muscular attachments are thirty-three—[ilium], latissimus dorsi, tensor vaginæ femoris, obliquus externus, erector spinæ, transversalis, quadratus lumborum, gluteus minimus, medius, and maximus, rectus, pyriformis, iliacus, multifidus spinæ, sartorius—[ischium], obturator externus and internus, gemellus superior, coccygeus, levator ani, semimembranosus and semitendinosus, biceps, quadratus femoris, adductor magnus, gemellus inferior, erector penis and transversus perinæi—[pubes], pyramidalis, obliquus internus and externus, psoas parvus, pectineus, adductor longus and brevis, gracilis and compressor urethræ.

Its ossific centers are eight—one primary for each division and five epiphyses, one each for crest of ilium, symphysis, tuberosity of ischium, anterior spinous process, and acetabulum.

THE FEMUR, or thigh bone, is the largest, longest and strongest bone in the body. In the erect position it inclines toward its fellow at the knee, being widely separated above, forming the sides of a triangle, the base of which is greater in females from the greater breadth of the pelvis. It consists of a shaft, an upper and lower extremity.

The shaft (*corpus femoris*) expanded above and below, curved and twisted, convex in front, concave behind, is nearly cylindrical throughout, and presents

Smooth *anterior surface,* for origin of crureus and subcrureus muscles;

Lateral surfaces, covered by the vasti externus and internus;

The *posterior surface,* rough and prominent, has its

Nutrient foramen between the middle and lower two-thirds directed upward;

Linea aspera, a rough, prominent, longitudinal crest descending from the trochanters along the middle third, bifurcating and diverging at the inferior extremity to the condyles, inclosing

The popliteal space (*planum popliteum*), a smooth, triangular space, on which rests the popliteal artery, and which is

Grooved at its inner margin by the femoral artery.

The outer (*labium laterale*) and inner (*labium mediale*) lip of the linea aspera give attachment to the vasti externi and interni, three adductors, pectineus, biceps and gluteus maximus.

The *upper extremity* presents the following:—

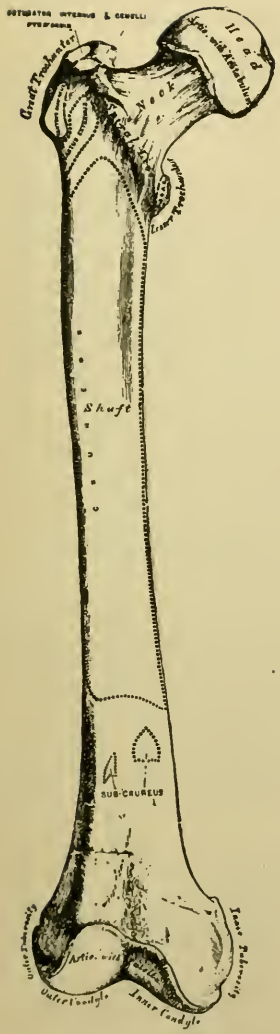

FIG. 55.

The femur, anterior surface.

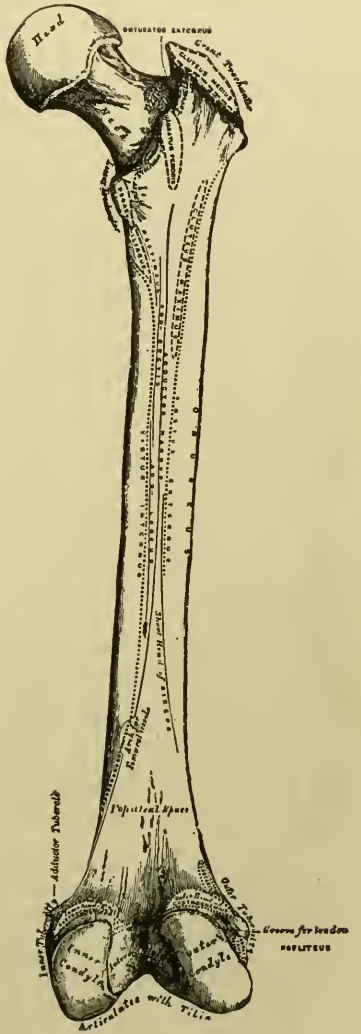

FIG. 56.

The femur, posterior surface.

The head (*caput femoris*), forming two-fifths of a sphere, articulates with the acetabulum, having a central oval depression (*fovea capitis femoris*) for the ligamentum teres;

Neck (*collum femoris*), pyramidal, with excavated surfaces, connects the head with the shaft, the angle of its obliquity to the shaft varying much from puberty to old age, being, in the adult, about 130 degrees;

The great trochanter (*trochanter major*), a large, rough, quadrilateral eminence, directed upward, outward, and backward, its external surface marked by a diagonal line for insertion of gluteus medius tendon, its outer surface smooth for the passage of the gluteus maximus tendon, separated by a bursa, and its superior surface marked by three impressions, from behind forward, for pyriformis, obturator internus and gemelli muscles. The gluteus minimus is attached to the anterior border;

Digital or trochanteric fossa (*fossa trochanterica*), to the inner side of the great trochanter, for insertion of obturator externus tendon;

The lesser trochanter (*trochanter minor*), a small, conical projection at the base of the neck posteriorly, and giving attachment to the tendon of psoas magnus muscle, the iliacus being inserted below;

Anterior intertrochanteric line (*linea intertrochanterica*) connects the trochanters in front and gives attachment at its upper part to the capsular ligament;

Posterior intertrochanteric line (*crista intertrochanterica*), a much more prominent ridge, connects them behind;

Tubercle of the femur, a prominence at the junction of the neck with the great trochanter, is the meeting-place of five muscles—two gemelli, obturator internus, gluteus minimus and vastus externus;

Tubercle of the quadratus, about the center of the posterior intertrochanter line, for the quadratus femoris;

Linea quadrati, passes vertically downward from the middle of the posterior line, and gives attachment to part of adductor magnus and quadratus femoris.

The *inferior extremity,* large and cuboidal in form, presents:—

External condyle (*condylus lateralis*), shorter and broader than the internal, has behind its center the *outer tuberosity* for the external lateral ligaments of the knee, and a *groove* below the tuberosity for the tendon of the popliteus muscle. It also

gives origin to the outer head of the gastrocnemius, above which arises the plantaris muscle;

The internal condyle (*condylus medialis*), longer by half an inch and more prominent (so as to bring them on the same horizontal plane owing to the obliquity of the shaft), has on the inner surface the *inner tuberosity* for the internal lateral ligament;

Adductor tubercle, at the summit of the internal condyle, marks the termination of the inner ridge of the linea aspera, and gives attachment to tendon of adductor magnus;

Depression, above the articular surface of the internal condyle posteriorly, for the origin of the inner head of gastrocnemius;

Intercondyloid notch (*fossa intercondyloidea*), separates the condyles behind, and lodges the crucial ligaments;

Trochlear (*facies patellaris*) is a smooth surface between the condyles in front and articulates with the patella in front. The inferior surfaces of both condyles are smooth, continuous in front, covered with cartilage in the recent state, for articulation with the head of the tibia. The femur articulates with three bones—innominatum, tibia and patella.

Its muscular attachments are twenty-three (23)—two vasti, three adductors, gluteus maximus, medius and minimus, pyriformis, obturator externus and internus, two gemelli, quadratus femoris, psoas magnus, iliacus, biceps, pectineus, crureus, subcrureus, gastrocnemius, plantaris and popliteal.

Its ossific centers are five—three primary, one each for shaft and each extremity, and one epiphysis for each trochanter.

The patella is a flat, triangular bone, sesamoid in origin, developed in the tendon of the quadriceps extensor, forming the knee-cap, and entering into the formation of the knee-joint.

The convex *anterior surface* is roughened by apertures for nutrient vessels.

The posterior or internal surface (*facies articularis*) is divided by a vertical and transverse ridge into three surfaces—two smooth, articular *facets* for either condyle of femur above, the outer being deeper and broader, and a rough surface below, the apex (*apex patellæ*) for ligamentum patellæ.

The superior border (*basis patellæ*) gives attachment to the rectus and crureus muscles, the internal and external lateral borders to the vasti internus and externus.

It articulates with the femur.

Its muscular attachments are four muscles—rectus femoris, crureus, vastus externus and vastus internus.

It is developed from a single ossific center.

The tibia, or shin bone, extends on the internal aspect of the leg from the knee to ankle, and consists of a shaft, upper and lower extremity.

The shaft (*corpus tibiæ*) is triangular, prismoid, with the base above.

Its *anterior border* and *internal surface* are subcutaneous, the former forming the shin or crest of the tibia (*crista anterior*).

The posterior surface (*facies posterior*) presents above an oblique line (*linea poplitea*) for the lower border of the popliteal muscle and fascia, and origin of the soleus, and parts of flexor longus digitorum and tibialis posticus muscles.

It presents just below the oblique line a nutrient canal (*foramen nutricium*), the largest in the skeleton, directed downward.

Its external border, or interosseous ridge (*crista interossea*) is thin, for attachment of interosseous membrane.

The *external surface* and *internal borders* are covered by muscles.

The *superior* expanded *surface* presents:—

Head, consisting of two tuberosities, internal and external (*condylus medialis* and *condylus lateralis*), each having upon their upper surfaces a smooth, concave, ovoidal articulating facet (*facies articularis superior*) for the condyles of the femur, separated by

The spinous process (*eminentia intercondyloidea*) of the tibia, in front and behind which is impression for crucial ligaments, and laterally tubercles for the extremities of the semilunar cartilages;

Tubercle (*tuberositas tibiæ*), on the anterior surface of the head, between the tuberosities, for the insertion of ligamentum patellæ;

Popliteal notch (*incisura poplitea*), separating the tuberosities posteriorly, for attachment of the posterior crucial ligament;

Transverse groove, on the posterior surface of the inner tuberosity, for insertion of semimembranosus tendon;

Facet (*facies articularis fibularis*), upon the posterior surface of the outer tuberosity, for articulation of the head of the fibula.

The *inferior extremity,* smaller than the superior, is quadrilateral, and presents in front a smooth surface for extensor tendons; behind, a groove for flexor longus pollicis tendon; exter-

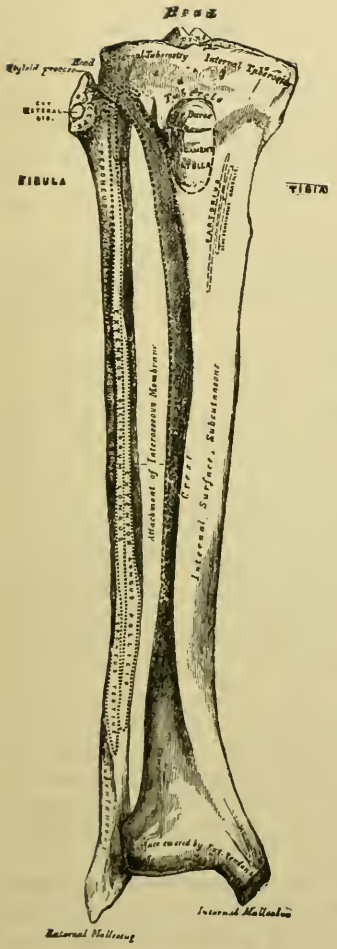

FIG. 57.

The tibia and fibula, anterior surface.

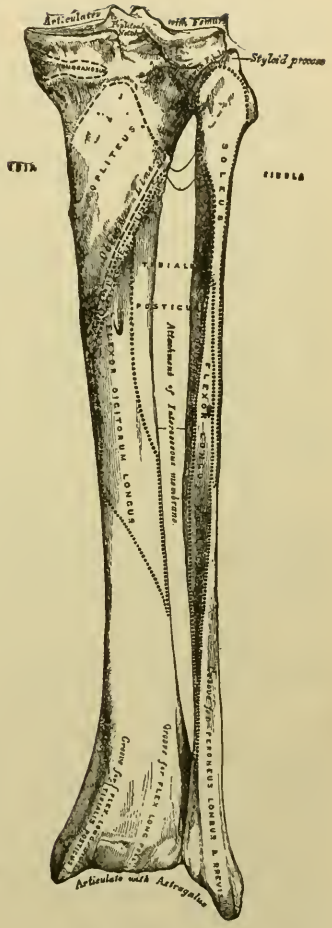

FIG. 58.

The tibia and fibula, posterior surface.

nally, a rough, triangular, articular surface, for fibula, and internally

The internal malleolus (*malleolus medialis*), which projects downward, and articulates by its outer surface with the astragalus.

Its inner surface is smooth and subcutaneous; its posterior border is grooved (*sulcus malleolaris*) for the tendons of the tibialis posticus and flexor longus digitorum muscles, and to its tip is attached the internal lateral ligament.

It articulates with three bones—femur, fibula and astragalus.

Its muscular attachments are twelve—ligamentum patellæ, popliteus, soleus, flexor longus digitorum, tibialis posticus, semimembranosus and tendinosus, gracilis, sartorius, tibialis anticus, extensor longus digitorum and biceps.

It is developed from three ossific centers, one each for shaft, upper and lower extremities.

The fibula, peroneal, or calf-bone, is a long, slender bone on the outer aspect of the leg, and consists of a shaft, upper and lower extremity.

The shaft (*corpus fibulæ*) is prismoidal, four-sided, twisted on itself, and arched backward. Its antero-internal border, or interosseous ridge (*crista interossea*), gives attachment to the interosseous membrane. The postero-internal border (*crista medialis*), called also *oblique line,* and the other surface and borders give attachment to all the muscles except the biceps.

Nutrient foramen, about the middle of the anterior-internal surface, is directed downward.

The *superior extremity* presents a *neck,* supporting a rounded, irregular head (*capitulum fibulæ*), which articulates by a flattened *facet* on its inner surface with the tibia, and is prolonged upward on its outer side by the styloid process (*apex capituli fibulæ*), giving attachment to the biceps tendon and the external lateral ligament of the knee.

The *inferior extremity* expands into the external malleolus (*malleolus lateralis*), with its convex internal surface for articulation with astragalus, outer convex surface subcutaneous, and posterior border deeply grooved (*sulcus malleolaris*) for tendons of peroneus longus and brevis muscles.

To the *summit* is attached the middle fasiculus of the external lateral ligament, and to rough *depressions* in front and behind the anterior and posterior fasciculi.

It articulates with two bones, tibia and astragalus.

Its muscular attachments are nine: soleus, biceps, three peronei, tibialis posticus, flexor longus hallucis, extensor longus digitorum and extensor longus hallucis.

It is developed from three ossific centers, one each for shaft, head and malleolus.

THE FOOT.

The bones of the foot consist of seven tarsus, five metatarsus, and fourteen phalanges.

THE TARSAL BONES (*ossa tarsi*) are: calcaneum, astragalus, cuboid, scaphoid, and internal, middle, and external cuneiform.

They may be arranged into two series, anterior and posterior; the calcis and astragalus behind, and all the others in front of the calcaneocuboid and astragaloscaphoid joints [Chopart's].

CALCANEUM, or os calcis, the largest, is irregularly cuboidal.

The *superior surface* presents two articular surfaces for the astragalus, separated by a groove for the calcaneoastragaloid ligament, and internally a projecting process, the *sustentaculum tali,* for calcaneocuboid ligament. The *inferior surface,* rough and excavated, presents two *tubercles,* an *outer* and *inner tubercle,* for muscles and ligaments.

Internal surface is concave, for passage of flexor longus and tibialis posticus tendons, and plantar vessels and nerves.

External surface presents tubercle (*processus trochlearis*) for external lateral ligament of ankle and grooves for peroneal tendons.

Posterior surface, projecting behind (*tuber calcanei*), presents a smooth surface above for bursa and rough below for attachment of tendo Achillis.

It articulates with astragalus and cuboid.

Muscular attachments are eight: tendo Achillis, plantaris, tibialis posticus, abductor hallucis, a. minimi digiti, flexor brevis digitorum, accessorius and extensor brevis digitorum.

ASTRAGALUS (*tales*) is an irregular, short bone, consisting of body (*corpus tali*), neck (*collum tali*), and head (*caput tali*). The quadrilateral *body* presents four articular surfaces, above for lower extremity of tibia and internal malleolus and external malleolus; below, two surfaces for os calcis, separated by deep groove for interosseous calcaneoastragaloid ligament; *posteriorly* it presents a deep groove (*sulcus m. flexor hallucis longi*) for flexor longus hallucis tendon; and *anteriorly,* the rounded convex *head* supported on *neck* articulates with scaphoid, and rests upon calcaneoscaphoid ligament.

It articulates with four bones: tibia, fibula, scaphoid and os calcis. It has no muscular attachments.

Cuboid (*os cuboideum*—cube-like) is a small, pyramidal bone, between the os calcis and the fourth and fifth metatarsal bones on the outer side of the foot.

The *upper* or *dorsal surface* is rough for ligamentous attachment; the *lower* or *plantar* surface is grooved (*sulcus m. peronæi longi*) for tendon of peroneus longus, behind which is a *ridge* for the long calcaneocuboid ligament, terminating externally in the tuberosity of the cuboid (*tuberositas ossis cuboidei*).

The *external surface* has a deep *notch*, the outer extremity of the peroneal groove.

The *posterior surface* has triangular *facet* for os calcis, the anterior has two facets, separated by a ridge for the fourth and fifth metatarsals, and the internal surface has broad, square facet for external cuneiform, and sometimes a smaller facet for scaphoid.

It articulates with four and occasionally with five bones.

It has one muscular attachment—part of flexor brevis pollicis.

Scaphoid, or navicular bone (*os naviculare pedis*), is a boat-like bone placed between astragalus and three cuneiform bones.

Its *posterior* concave *surface* articulates with head of astragalus, its *anterior* convex *surface* has three facets for cuneiform bones; its *internal border* presents the tuberosity of the scaphoid (*tuberositas ossis navicularis*) for insertion of tibialis posticus, the only muscular attachment. Its other borders are roughened for ligamentous attachment.

It articulates with four bones: astragalus and three cuneiforms.

The cuneiform bones are named from their position the internal, middle and external.

The internal cuneiform (*os cuneiforme primum*), the largest, has its base below, and articulates anteriorly with first metatarsal, posteriorly with scaphoid, and externally with second metatarsal and middle cuneiform. The plantar surface presents tuberosity for insertion of part of tibialis posticus and anticus tendons, the only muscular attachments. It articulates with four bones: scaphoid, middle cuneiform, first and second metatarsals.

The middle cuneiform (*os cuneiforme secundum*), the smallest, has its base upward, and articulates posteriorly with

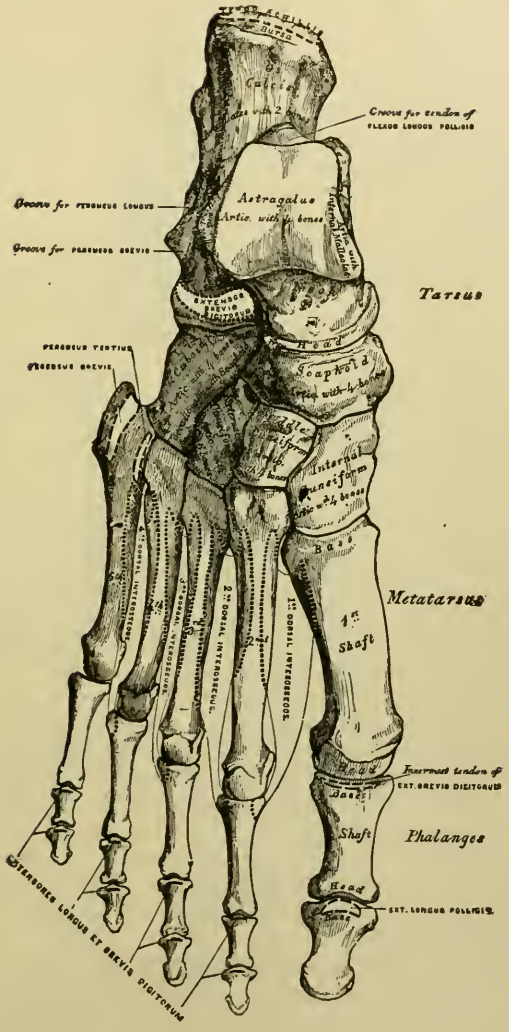

FIG. 59.

The tarsus, metatarsus, and phalanges, dorsal surface.

scaphoid, anteriorly by a triangular facet with second metatarsal, and laterally with internal and external cuneiforms. It has no muscles attached.

The external cuneiform (*os cuneiforme tertium*), intermediate in size, and more regular, articulates posteriorly with scaphoid, anteriorly with third metatarsal, internally with middle cuneiform and second metatarsal, and externally with cuboid and fourth metatarsal.

Muscular attachments are for flexor brevis pollicis and tibialis posticus.

The metatarsal bones (*ossa metatarsalia*) have the same general form as the metacarpal bones of hand, each consisting of shaft, head and base.

The shaft (*corpus*) is prismoid and curved, with concavity below, convexity above.

The head (*capitulum*) is rounded for articulation with phalanges, and has *tubercles* laterally for ligaments and a *groove* below for tendon of long flexor.

The base (*basis*) is wedge-shaped for articulation with the tarsus and with each other.

The first (*os metatarsale I*) and strongest articulates at base with internal cuneiform, at head with phalanx and second metatarsal, and has three muscular attachments: for tibialis anticus, peroneus longus and first dorsal interosseous.

The second (*os metatarsale II*) is wedged in by base between three cuneiform bones, articulates with second phalanx, first and third metatarsi, and has three muscular attachments: for adductor hallucis, first and second interosseous.

The third (*os metatarsale III*) articulates with external cuneiform below and second and third metatarsi and third phalanx, and has four muscular attachments: for adductor hallucis, first plantar, and second and third dorsal interossei.

The fourth (*os metatarsale IV*) articulates at base with external cuneiform and cuboid and at extremity with third and fifth metatarsal and fourth phalanx, and has four muscular attachments: for adductor hallucis, third and fourth dorsal, and second plantar interossei.

The fifth (*os metatarsale V*) has marked tubercle on outer side. It articulates with cuboid, fourth metatarsal, and fifth phalanx, and has five muscular attachments: for flexor brevis minimi digiti, peroneus brevis and tertius, fourth dorsal and third plantar interosseus.

The phalanges of the foot (*phalanges digitorum pedis*) have same general characteristics as in hand, but are compressed

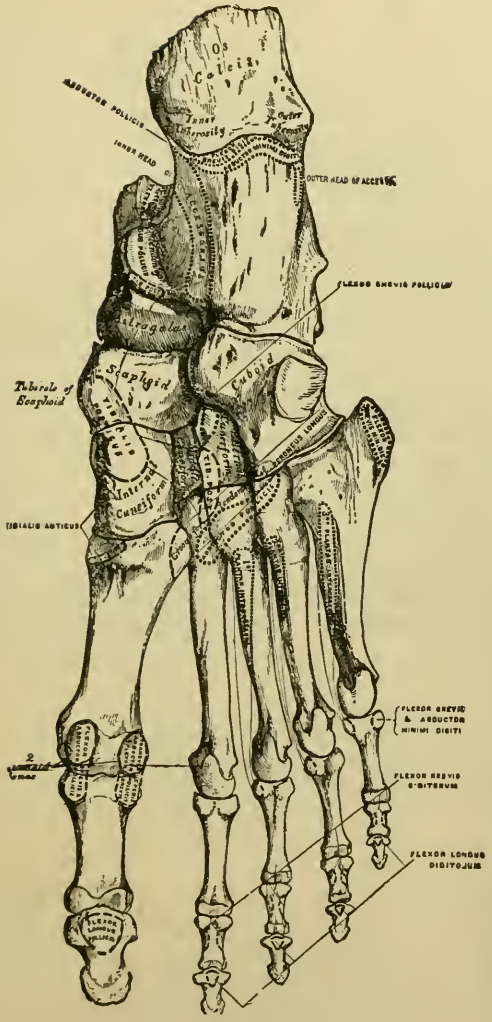

FIG. 60.

The tarsus, metatarsus, and phalanges, plantar surface.

from side to side instead of from before backward; and have the following nomenclature applied: first or proximal phalanx (*phalanx prima*); second phalanx (*phalanx secunda*); ungual or distal phalanx (*phalanx tertia*). The muscular insertions to first row are: to great toe, transversus pedis, extensor brevis digitorum, adductor, abductor and flexor brevis hallucis; to second, first and second dorsal interosseus; to third, third dorsal and first plantar interosseus; to fourth, fourth dorsal and second plantar interosseus; to fifth, abductor and flexor brevis minimi digiti and third plantar interosseus. To second row: to great toe, flexor and extensor longus hallucis; to remaining toes, extensor longus and brevis digitorum, flexor brevis digitorum and lumbricales. To third row, or ungual phalanges: flexor longus and extensor longus and brevis digitorum.

The ossific centers are one each for the tarsus, excepting the os calcis, which has an epiphysis for posterior part, and two each for metatarsals and phalanges. These latter are arranged in phalanges, one each for shaft and base, and in metatarsals, one each for shaft and head, excepting great one, which has one each for shaft and base.

Sesamoid bones (*ossa sesamoidea*) are small, osseous masses, cartilaginous in early life, developed in the tendons to relieve pressure. They are of two kinds—those over articular surfaces of joints, as patella; and those applied to the surfaces of bones, as in tendon of peroneus longus in the groove of cuboid bone.

TABLE OF OSSIFICATION.

Name.	Centers.	Time of Appearance.
VERTEBRÆ.	3 Primary:—	
	1 for each lamina.	6th week.
	1 for each process.	
	1 for body.	8th week.
	4 Secondary Centers:—	
	1 for each transverse process.	16th year.
	2 for end of spinous process.	
	2 Additional Plates:—	
	1 epiphyseal plate on upper and under surface of body.	21st year.
		All unite by 30th year.
Atlas (3).	1 for each lateral mass.	8th week.
	1 epiphysis for anterior arch.	1st year.
Axis (6).	1 for lower part of body.	6th month.
	1 for each lamina.	
	2 for lateral processes.	6th fetal month.
	1 for apex of odontoid process.	
Seventh Cervical.	1 for anterior and costal part of transverse process.	6th fetal month; joins 5th or 6th year.
Lumbar Vertebræ (2).	1 for each tubercle of superior articular process.	
Sacrum (35).		
15.	3—1 each for body and upper and lower epiphyseal plate.	8th or 9th week. 16th year, and unites 18th or 20th year.
10.	2—1 for each arch.	6th or 8th month: joins 2d to 6th year.
6.	2 for each lateral mass of the first three vertebræ.	
4.	Each lateral surface has one epiphyseal articulation and adjoining edge.	18th to 25th year.
Coccyx (7).	1 for each piece.	
	1.	Birth.
	2.	5th to 10th year.
	3.	10th to 15th year.
	4.	15th to 20th year.
CRANIAL BONES.		
Occipital (7).	4 for tabular or epi-occipital.	8th fetal week.
	1 for each condylar portion.	4th to 6th year; joined to sphenoid 18th to 25th year.
Parietal (1).	1 for basilar portion.	
	From membrane.	
	Single center at parietal eminence.	7th to 8th fetal week.

Name.	Centers.	Time of Appearance.
Frontal (2).	1 for each lateral portion.	7th to 8th week.
	From membrane.	United by 4th year.
Temporal (10).	1 for squamous process.	2d month.
	1 for auditory process.	Later.
	6 for petromastoid.	5th or 6th month.
	2 for styloid process.	
Sphenoid (14).	8 for postsphenoid.	
	1 for each greater wing and external pterygoid plate.	
	1 for each internal pterygoid plate.	
	2 for posterior part of body.	1 for base appears before birth and one after birth.
	1 for each lingula.	
	6 for presphenoid:—	Appear from 8th week to third year, and union of all parts is accomplished by the 20th year, and with occipital, 18th to 25th year.
	1 for each lesser wing.	
	2 for anterior portion of body.	
	1 for each sphenoturbinal.	
Ethmoid (3).	1 for each lateral mass.	4th to 5th fetal month.
	1 for lamella.	Unite about 2d year.
FACE.		
Nasal.	1 for each bone.	6th week.
Superior Maxillæ (4).	1 premaxilla.	Very early.
	1 prepalatine portion.	Antrum appears about fourth fetal month.
	1 maxillary portion.	
	1 malar portion.	
Lachrymal.	A single center.	7th week.
Malar.	Single center.	6th week.
Palate.	Single center at junction of plates.	2d fetal month.
Inferior Turbinated.	Single center.	Middle of fetal life.
Vomer.	Single center, but two laminæ.	8th week.
Inferior Maxilla.	Probably several centers; at birth consists of two halves.	Very early, being second in order.
BODY.		
Hyoid (5).	1 for body and for each cornu.	3 months after birth.

Name.	Centers.	Time of Appearance.
Sternum (6).	1 for manubrium.	Middle of fetal life.
	4 for gladiolus.	
	1 for ensiform appendix.	
Ribs (3).	1 for each shaft, head, and tubercle, excepting the last two, which have but 2, the tubercles being absent.	Before vertebræ. Epiphysis for tubercle appears from 16th to 20th year, and unites about 25th.
UPPER EXTREMITY.		
Clavicle (2).	1 for shaft.	About 30th day.
	1 for sternal extremity.	
Scapula (7).	1 for body.	2d month.
	2 for coracoid process.	
	2 for acromion process.	
	1 for posterior border.	Completed between 20th and 25th year.
	1 for inferior angle.	
Humerus (7).	1 for shaft.	8th week.
	1 for head.	
	1 for tuberosities.	
	1 for radial head.	Upper extremity ossifies 2d to 4th year.
	1 trochlear portion.	
	1 for each condyle.	Complete about 20th year.
Ulna (3).	1 for shaft.	8th week.
	1 for olecranon.	10th year.
	1 for lower extremity.	4th year.
Radius (3).	1 for shaft.	Soon after humerus.
	1 for upper extremity.	5th year; unites 17th to 18th year.
	1 for lower extremity.	2d year; unites 20th year.
		Upper extremity joins 16th year; lower, 20th year.
Carpus.	Each has single center:—	
	Os magnum.	1st year.
	Unciform.	1st year.
	Cuneiform.	3d year.
	Trapezium and semilunar.	5th year.
	Scaphoid.	6th year.
	Trapezoid.	8th year.
	Pisiform.	12th year.

Name.	Centers.	Time of Appearance.
Metacarpus (2).	Centers for each:—	
	1 for shaft and	8th or 9th week.
	1 for each distal extremity except thumb, which has one each for shaft and base.	3d year, and unites about 20th year.
Phalanges (2).	1 each for shaft and base.	8th week, and unites 18th to 20th year.
Lower Extremity.		
Os Innominata (8).	3 Primary:—	
	Ilium.	Same as vertebræ, 6th week.
	Ischium.	3d month.
	Pubes.	4th or 5th month.
	5 Secondary:—	
	1 crest of ilium.	Puberty.
	1 anterior inferior spinous process.	"
	1 tuber ischii.	"
	1 symphysis pubis.	"
	1 acetabulum.	13th or 14th year; completed 25th year.
Femur (5).	1 for shaft.	5th week.
	1 for lesser trochanter.	End of 1st year
	1 for great trochanter.	9th fetal month.
	1 for lower extremity.	4th year.
	1 for upper extremity.	13th or 14th year. Inferior extremity. The last is not united before the 20th year.
Patella.	Single center.	3d to 6th year; completed about puberty.
Tibia (3).	1 for shaft.	7th week.
	1 upper extremity.	Birth; unites 20th year.
	1 lower extremity.	2d year; unites 18th year.
Fibula (3).	1 for shaft.	8th fetal week.
	1 upper extremity.	4th year.
	1 lower extremity.	2d year; the lower unites first—about 20th year.

Name.	Centers.	Time of Appearance.
Tarsus.	4 os calcis:—	
	1 for body and	6th fetal month.
	1 for posterior extremity.	
	1 each for the following:—	
	Cuboid.	9th month.
	Astragalus.	7th month.
	Scaphoid.	4th year.
	Internal cuneiform.	3d year.
	Middle cuneiform.	4th year.
	External cuneiform.	1st year.
Metatarsus.	1 each for shaft	7th week.
	and digital extremity, except great toe, which is same as thumb.	3d year.
Phalanges (2).	1 each for shaft and proximal extremity.	

ARTICULATIONS AND LIGAMENTS.

The bones of the skeleton are connected together by articulations or joints.

These consist essentially of the expanded extremities of bones, covered with cartilage, often separated by interarticular fibrocartilage, held together by ligaments, and lined by synovial membrane.

The *bone* entering into the articular lamella differs from ordinary bone by its extreme density, without Haversian canals, its lacunæ being much larger, and without canaliculi. It is not perforated by blood-vessels.

Cartilage is a whitish, highly elastic, non-vascular structure, forming in the fetus the greater part of the skeleton, and found in the adult chiefly in the joints, the walls of the thorax, and certain orifices, as the nostrils, ears, etc.

It is either *temporary,* becoming ossified later, or *permanent,* remaining unossified. The latter is divided into three varieties: *articular,* in joints covering the ends of the bones; *costal,* forming part of the thorax; and *reticular,* arranged in plates or lamellæ to maintain the shape of parts.

Fibrocartilage consists of a mixture of cartilaginous with white fibrous tissue. There are four varieties:—

(*a*) *Interarticular,* interposed between the joint surfaces;
(*b*) *Connecting,* binding bones together as in pubes;
(*c*) *Circumferential,* deepening cavities, as glenoid cavity of shoulder; and
(*d*) *Stratiform,* lining grooves for tendons.

Synovial membranes are of three kinds: *articular,* lining the cavities of movable joints throughout except the surface of the cartilage; *bursal,* irregular cavities interposed at convenient positions to alleviate friction; from their contents they may be either mucous or synovial; and *vaginal synovial membranes,* or sheaths, surrounding tendons and diminishing friction.

Synovia is a transparent, viscid liquid, albuminous in its nature.

The articulations consist of three (3) classes: diarthrosis, movable; synarthrosis, immovable; and amphiarthrosis, mixed.

1. The *diarthrosis* are subdivided into:—

Arthrodia, gliding joint, as superior tibiofibular;
Enarthrosis, ball-and-socket joint, as shoulder and hip;
Ginglymus, hinge-joint, as knee and ankle;
Trochoides, a ring surrounding a pivot, as atloaxoid joint and superior radioulnar.
Condyloid, elliptical cavity receiving an ovoid head, as wrist joint.
Reciprocal reception, a concavoconvex articulation, as carpometacarpal joint of thumb.

2. *Synarthrosis*, surface immovably connected by fibrous membrane without synovial membrane.

They are divided into:—

Sutura, bones interlocking with one another;
Schindylesis, a fissure in one bone receiving a plate of bones, as between vomer and sphenoid;
Gomphosis, a socket with a pivot inserted, as in alveolar cavities for teeth.
Synchondrosis, a temporary joint in which the connecting medium is cartilage.

The sutura may be either true, *sutura vera,* or false, *sutura notha,* the former having three divisions: dentata, tooth-like processes, as interparietal suture; serrata, saw-like edges, as interfrontal suture; limbosa, dentated processes and beveled margins, as frontoparietal; the latter two divisions:—

Squamosa, overlapping beveled margins, and
Harmonia, by union of roughened surfaces, as intermaxillary suture.

3. *Amphiarthrosis,* bony surfaces connected by fibrocartilage, with or without synovial membrane, as between vertebral bodies, and pubic symphysis.

Motions in Joints.—Joints admit of four (4) distinct varieties of motion:—

(*a*) Gliding movement, between contiguous surfaces;
(*b*) Angular movement, as flexion, extension, adduction and abduction;
(*c*) Circumduction, as in true enarthrosis;
(*d*) Rotation on its own axis, as between the atlas and axis.

Temporomaxillary, or temporomandibular articulation (*articulatio mandibularis*), is formed by condyle of lower jaw, below articulating with glenoid cavity of the temporal bone and eminentia articularis above. It is a double arthrodial joint.

Ligaments.—*External Lateral* (*ligamentum temporomandibulare*).—*Origin,* tubercle on outer edge of zygoma; *insertion,* outer side of neck of condyle.

Internal Lateral (*ligamentum sphenomandibulare*).—*Origin,* spinous process of sphenoid; *insertion,* lower circumference of inferior dental foramen.

Capsular (*capsula articularis*).—*Origin,* circumference of articulation; *insertion,* neck of condyle.

Interarticular fibrocartilage (*discus articularis*) is within cavity; external pterygoid muscle attached to its inner edge.

Synovial membrane is divided into two by cartilage.

Intermaxillary ligament passes from external pterygoid process to coronoid.

Stylomaxillary or Stylomandibular Ligament (*ligamentum stylomandibulare*).—*Origin,* styloid process; *insertion,* inner surface of angle of jaw. *Nerves* are derived from the auriculotemporal and masseteric branches of the inferior maxillary.

Articulations of Vertebral Column.—These are formed between the contiguous surfaces of the vertebral bodies and articular processes, inclosed in capsular ligaments, and connected with the following ligaments:—

The anterior common ligament (*ligamentum longitudinale anterius*) extends from the front of the body of the axis down the anterior surface (ventral) of the spine to the sacrum, being expanded opposite, and attached to each intervertebral connecting fibrocartilage;

The posterior common ligament (*ligamentum longitudinale posterius*) descends along posterior surfaces (dorsal) of bodies from axis to sacrum within spinal canal. It also expands opposite and adheres to intervertebral substance;

Intervertebral substance (*fibrocartilagines intervertebrales*), disks of varying size, twenty-seven in number, composed of decussating fibers of fibrocartilage, arranged in crescentic laminæ with central, semipulpy substance, separate the vertebræ;

Ligamenta subflava (*ligamenta flava, ligamenta intercruralia*) descend in pairs, twenty-three on either side, from one lamina to another, from axis to sacrum, inclosing spinal canal;

Supraspinous ligament (*ligamentum supraspinale*) strong cord descending from one vertebra to another, from vertebra prominens (seventh cervical) to sacrum. Its continuation in cervical region forms *ligamentum nuchæ;*

Interspinous (*ligamenta interspinalia*) stretch between spinous processes throughout dorsal and lumbar regions;

Intertransverse (*ligamenta intertransversaria*), between transverse processes in lower dorsal and lumbar regions.

The *arteries* are derived from ascending cervical and vertebral in cervical, intercostals in dorsal, and lumbars in lumbar regions.

The *nerves* are from spinal nerves in each region.

ATLOAXOID OR ATLANTOAXOIDEAN ARTICULATION (*articulatio atlantoepistrophica*) consists of of four joints, the two lateral joints being arthrodia, and that between the odontoid process and arch of atlas and transverse ligament—a diarthrosis rotatoria—being double, one in front, *atlo-odontoid,* and one behind, *odontotransverse.* The ligaments are:—

Anterior atloaxoid, or anterior atlantoaxial, two—superficial and deep, connecting anterior borders together;

Posterior atloaxoid, or posterior atlantoaxial, connecting the arches of the atlas and axis posteriorly, and pierced laterally by the second spinal nerve;

Capsular (*capsulæ articulares*), two, connecting the articulating processes laterally, and lined with synovial membrane;

Transverse, or cruciform (*ligamentum transversum atlantis*), arises from the tubercle on one side of the lateral mass, passes across the back of odontoid process to be inserted into the opposite tubercle.

The *arteries* are from vertebral, *nerves* from second cervical, or from loop between it and suboccipital.

OCCIPITOATLOID (*articulatio atlanto-occipitalis*).—Anterior occipitoatloid (*membrana atlanto-occipitalis anterior*)—two, superficial and deep, connecting the tubercle and upper border of anterior arch of atlas with basilar process and margin of foramen magnum of occiput.

Posterior occipitoatloid, or occipitoatlantal ligament (*membrana atlanto-occipitalis posterior*—membranous), connects the upper border of posterior arch of atlas with posterior margin of foramen magnum.

Lateral ligaments, two bands connecting transverse process of atlas with jugular process of occipital.

Capsular ligaments (*capsulæ articulares*) connect the articular processes of atlas with condyles of occiput.

The *arteries* are from vertebral; *nerves,* from suboccipital.

OCCIPITOAXOID.—*Occipitoaxoid* is a broad band, the continuation of posterior common ligament, extending from the body of the axis to basilar groove of occipital.

Odontoid, or check (*ligamentum alaria*), pass upward and outward from the summit of the odontoid process, to be inserted into the inner side of the occipital condyles.

Ligamentum suspensorium, or central occipito-odontoid (*ligamentum apices dentis*), arises from the center of the transverse ligament at the apex of the odontoid process, and passes upward, to be inserted into the anterior margin of the foramen magnum.

Occipitocervical, or cervicobasilaris (*membrana tectoria, apparatus ligamentosus colli,* posterior occipitoaxoid ligament), arises from the bodies of the third cervical and axis, and is inserted into the basilar groove of occipital.

The *arteries* are from vertebral; the *nerves* from suboccipital.

Capsular Ligaments.—Throughout the spine the articulations between the facets of the articular processes are surrounded by capsular ligaments, making twenty-five pairs in all.

Costovertebral Articulations (*articulationes costovertebrales*).—The *costovertebral* have each a double arthrodia between the head of the rib and the bodies of the two adjacent vertebræ, except the first, tenth, eleventh and twelfth ribs, which have each but a single joint.

Anterior Costovertebral, or Stellate Ligament (*ligamentum capituli costæ radiatum*).—*Origin,* head of the rib; *insertion,* into body of vertebra above and below, and interarticular cartilage between.

Interarticular costovertebral (*ligamentum capituli costæ interarticulare*) is within the capsular ligament, from the crest on the head of the rib to the intervertebral substance.

Capsular ligament (*capsula articularis*) surrounds the articular surfaces.

Costotransverse articulations are united by three ligaments —anterior, middle, and posterior costotransverse ligaments— extending between the tubercles of the ribs to the transverse process below. *Arteries,* the intercostals; *nerves,* anterior branches of spinal.

Costosternal Articulations (*articulationes sternocostales*).—These are connected by arthrodia excepting the first, which is a synarthrodia.

Anterior chondrosternal ligaments (*ligamentum sternocostale radiatum*) connect the chondral and sternal surface in front;

Posterior chondrosternal (*ligamentum sternocostale radiatum*) connect them behind.

Capsular ligaments (*capsula articularis*) surround all, and *synovial membranes* are present in all but the first, while the second has an interarticular cartilage interposed.

The chondroxiphoid (*ligamentum costoxiphoidea*) ligament connects the cartilage of the seventh and sometimes the sixth rib with the xiphoid appendix.

Interchondral and Costochondral Articulations (*articulationes interchondrales*).—The ribs are connected with their cartilages by the periosteum covering them. The cartilages of the sixth, seventh, and eighth ribs, and sometimes the fifth and ninth, are connected by external and internal interchondral ligaments (*ligamenta intercostalia externa et interna*), held together by capsular ligaments and lined with synovial membrane.

Ligaments of Sternum.—The first and second portions of the sternum are articulated by an amphiarthrodial joint, sometimes a diarthrodial joint, connected by the external intersternal and internal intersternal ligaments, and lined with synovial membrane.

The third portion, or ensiform cartilage, is united to the gladiolus by a synarthrodial joint.

THE THORAX.

The thorax is a conical osteocartilaginous framework, formed by the dorsal vertebræ behind, the ribs, intercostal muscles, and costal cartilages laterally, and the sternum in front.

The apex, or superior opening (*apertura thoracis superior*), is bounded behind by the first dorsal vertebra, laterally by the first rib, and in front by the upper border of the sternum.

It transmits the following structures:—

Esophagus, trachea, thoracic duct (on the left side), lymphatic vessels of right side of chest and of surface of liver, innominate artery (right side), left common carotid artery, left subclavian artery, right and left superior intercostal arteries, right and left internal mammary arteries, thyroidea ima artery (if present), right and left inferior thyroid veins, right and left innominate veins, right and left phrenic nerves, right and left pneumogastric nerves and their cardiac branches, left recurrent laryngeal nerve, right and left first dorsal nerves, right and left sympathetic nerves and their cardiac branches, apices of lungs and pleuræ, remains of thymus, and deep cervical fascia passing to pericardium.

The longus colli, sternohyoides and sternothyroides on both sides also pass through it.

The inferior opening (*apertura thoracis inferior*) is formed by the last dorsal vertebra behind, the last rib laterally, and the ensiform cartilage in front. It is filled in by the diaphragm.

The cavity (*cavum thoracis*) of the thorax contains the following structures: the heart and great vessels, trachea, bron-

chi and lungs, azygos and bronchial veins, internal mammary arteries, pneumogastric, phrenic and splanchnic nerves, thoracic duct, esophagus, lymphatic vessels and glands (*vide* mediastinum).

Spine and Pelvis.—*Sacrovertebral articulation.* In addition to those of the spine, given above, there are two ligaments connecting the last lumbar vertebra with the sacrum:—

Lumbosacral ligament, arising from the transverse process of the last lumbar vertebra, and inserted into the base of the sacrum;

Iliolumbar ligament (*ligamentum iliolumbale*), arising from the apex of the transverse process of the last lumbar vertebra, and inserted into the crest of the ilium. The *arteries* are from last lumbar, iliolumbar and lateral sacral. The *nerves* are branches of fourth and fifth lumbar and sympathetic.

Sacroiliac articulation (*articulatio sacroiliaca*), between the articular surfaces of the sacrum and ilium, is an amphiarthrodial joint connected by

The anterior sacroiliac ligament (*ligamenta sacroiliaca anteriora*), crossing between anterior surfaces of the two bones;

Posterior sacroiliac ligament (*ligamentum sacroiliacum posterius*), the stronger, passes in different directions between the posterior surfaces of the two bones, firmly binding them together. One of these, stronger than the others, passes from the posterior superior spinous process to the third sacral transverse process. It is called

The oblique sacroiliac ligament (*ligamentum sacroiliacum posterius longum*).

The *arteries* are from gluteal, sacral, spinal and iliolumbar; the *nerves* from lumbosacral and posterior sacral cords.

Sacroischiatic Articulation.—The os innominatum and sacrum are united by two important ligaments—the *great sacrosciatic* (posterior) ligament, and the *lesser sacrosciatic* (anterior) ligament.

The great sacrosciatic ligament (*ligamentum sacrotuberosum*) arises from the fourth and fifth transverse tubercles of the sacrum, from spine of ilium, sacrum and coccyx, and passes downward, outward and forward, to be inserted into the inner margin of the tuberosity of the ischium, being prolonged forward as the falciform ligament (*processus falciformis*) protecting the internal pudic veins and nerves.

It converts the sacrosciatic notch into the lesser sacrosciatic foramen, transmitting the obturator internus muscle and nerve, the internal pudic vessels and nerves.

The lesser sacrosciatic ligament (*ligamentum sacrospinosum*) arises from the lateral margin of the sacrum and coccyx, and is inserted into the spine of the ischium. It converts the sacrosciatic notch into the greater sacrosciatic foramen (*foramen ischiadicum majus*), transmitting the pyriformis muscle, gluteal vessels, superior gluteal nerve, sciatic vessels and nerves, and the internal pudic vessels and nerves.

Sacrococcygeal articulation (*symphysis sacrococcygea*) is an amphiarthrodial joint, resembling the vertebral, having an interarticular fibrocartilage, and connected together by

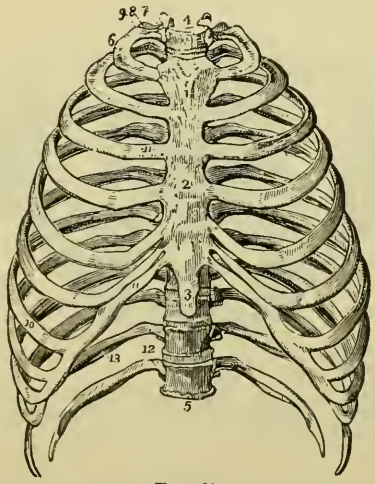

FIG. 61.

1, manubrium; 2, gladiolus; 3, xiphoid appendix; 4, first dorsal vertebra; 5, last dorsal vertebra; 6, first rib.

An anterior sacrococcygeal ligament (*ligamentum sacrococcygeum anterius*), and

A posterior sacrococcygeal ligament (*ligamentum sacrococcygeum posterius*), continuations respectively of the anterior and posterior common ligament.

Lateral sacrococcygeal, intertransverse (*ligamentum sacrococcygeum laterale*), and intercornual ligaments connecting the rudimentary transverse processes and the cornua together.

The *arteries* are from lateral and median sacral;

The *nerve* branches of coccygeal, fifth sacral, and posterior divisions of fourth sacral.

Pubic Articulation.—This is an amphiarthrodial joint, known also as the symphysis pubis (*symphysis ossium pubis*).

It is connected by the

Anterior pubic ligament (*ligamentum pubicum anterius*) in front;

Superior pubic ligament (*ligamentum pubicum superius*) above;

Posterior pubic ligament (*ligamentum pubicum posterius*) behind;

Subpubic ligament (*ligamentum arcuatum pubis*) below, forming the boundary of the pubic arch.

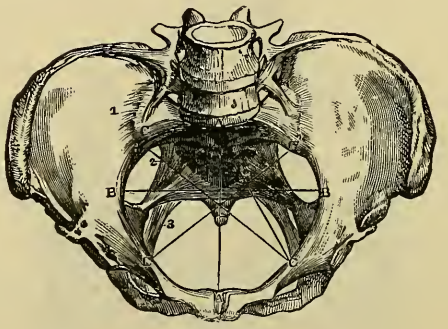

Fig. 62.

A A, anteroposterior diameter; B B, transverse diameter; C C, oblique diameter; 1, sacroiliac ligament; 2, anterior or lesser sacrosciatic ligament; 3, posterior or great sacrosciatic ligament.

Within the joint an interposed fibrocartilage, or interpubic disk (*lamina fibrocartilaginea interpubica*), separates the bones.

The *obturator membrane,* or ligament, closes the obturator foramen, and affords attachment for the external and internal obturator muscles and allows passage at its upper outer part, for the obturator vessels and nerves.

THE PELVIS.

The pelvis is a strong, bony basin, formed at the lower end of the vertebral column by the articulation of the sacrum and coccyx posteriorly with the ossa innominata laterally.

It is divided into a false and true pelvis by the iliopectineal line.

The false pelvis (*pelvis major*) is situated above the iliopectineal line, and corresponds to the expanded iliac fossæ,

being bounded laterally by the ossa ilii, and having in front and behind wide intervals.

The true pelvis (*pelvis minor*) includes all that portion below the linea iliopectinea, and presents a cavity, superior circumference or inlet, and an inferior circumference or outlet.

The inlet (*apertura pelvis superior*) is heart-shaped, being bounded behind by the promontory of the sacrum, laterally by the linea iliopectinea, and in front by the crest and spine of the pubes.

Its principal diameters in the female are:—

Anteroposterior or conjugate (*conjugata*), from symphysis to vertebral angle, four and three-fourths inches; transverse (*diameter transversa*) across the widest part, five and one-fourth inches; and oblique (*diameter obliqua*), from the iliopectineal eminence in front to the sacroiliac symphysis behind, five inches; the anatomical conjugate (*conjugata anatomica*) from the sacrovertebral angle to the top of the symphysis and measures about four and three-fifths inches; the true, available or obstetric conjugate (*conjugata gynæcologica*) is taken from the sacrovertebral angle to the nearest point upon the symphysis, and in the female averages about four and three-eighths inches. In the male, these measurements are about three-fourths of an inch less in every diameter.

It transmits the following structures:—

Viscera and Ducts.

1. Small intestines.
2. Rectum.
3. Vasa deferentia (in male), round ligaments (in female).
4. Ureters.
5. Urachus and obliterated hypogastric arteries.
6. Uterus (pregnant).
7. Bladder (distended).
8. Peritoneal coverings.

Vessels.

1. Superior hemorrhoidal.
2. Internal iliac.
3. Sacra media.
4. Iliolumbar.
5. Branches of vasa intestini tenuis.
6. Obturator (from deep epigastric).
7. Ovarian.
8. Pubic branches from external epigastric arteries.
9. Lymphatic vessels.

Nerves.

1. Sympathetic.
2. Branches from hypogastric plexus.
3. Obturator.
4. Lumbosacral cord.

The *cavity* of the *pelvis* is bounded behind by the sacrum and coccyx, in front by the symphysis, and laterally by the body of the ischium, forming a curved canal, widest in the middle.

It contains, in the recent state, the organs of generation, rectum, bladder, and their vessels, nerves, ducts, etc. Its axis corresponds to the concavity of the sacrum and coccyx.

Its depth in front, at the symphysis, is about one and a half inches in the middle axial line, three and a half behind, in males four and a half to possibly five and a half.

The outlet of the pelvis (*apertura pelvis inferior*) is bounded by three prominences, the tuber ischii laterally and the coccyx behind; separated by three notches, the subpubic arch in front and the sacrosciatic notches posteriorly.

Its principal diameters are: transverse, three and a half inches in male, four and three-fourths in female; anteroposterior, three and three-fourths in male, four and one-half in female.

In the erect position the pelvis is placed at an angle of from sixty to sixty-five degrees with the ground.

Differences of Sex.—The *male pelvis* is characterized by the strength of the bones, by prominent muscular impressions, by the depth and narrowness of the cavity, the large obturator foramen, and the acute angle of the subpubic arch.

The *female pelvis* is characterized by the lightness of the bones, the slight muscular impressions, by the shallow, expanded iliac fossæ, the increased size of the cavity in every diameter, and the obtuse angle of the subpubic arch.

ARTICULATIONS OF THE UPPER EXTREMITY.

The sternoclavicular articulation (*articulatio sternoclavicularis*) is an arthrodial joint, formed between the sternal end of the clavicle and the sternum and first rib, being divided into two cavities by an interarticular fibrocartilage. Its ligaments are:—

Anterior sternoclavicular (*ligementum sternoclaviculare*) is a broad band passing between the articular margins, attached to the interarticular cartilage and two synovial membranes, and forming the front part of the capsular ligament;

Posterior sternoclavicular passes over the posterior aspect of the joint and corresponds to the former;

Interclavicular (*ligamentum interclaviculare*) passes from the sternal end of the clavicle on one side across the suprasternal notch to the clavicle of the opposite side;

Costoclavicular, or rhomboid (*ligamentum costoclaviculare*), passes from the rhomboid impression on the inferior sur-

face of the clavicle to the upper surface of the first costal cartilage.

The *synovial membranes* form two sacs separated by the interarticular cartilage.

The *arteries* are from muscular branch of suprascapular and contiguous muscular branches;

The *nerves,* from descendens noni.

Acromioclavicular articulation (*articulatio acromioclavicularis*) is an arthroidal joint formed between the acromial extremity of the clavicle and the acromial process of the scapula. Its ligaments are:—

Fig. 63.

1, superor acromioclavicular ligaments; 2, coracoclavicular ligaments; 3, coracoacromial ligaments; 4, transverse ligament; 5, capsular ligament; 6, coracohumeral ligament; 7, tendon of biceps.

The superior acromioclavicular (*ligamentum acromioclaviculare*) connect the adjoining parts of the superior surfaces of the clavicle and acromion process;

Inferior acromioclavicular, connecting the inferior surfaces;

Coracoclavicular (*ligamentum coracoclaviculare*) consists of two parts:—

Trapezoid (*ligamentum trapezoideum*), broad, square, arises from upper surface of coracoid process, and is inserted into oblique line on under surface of clavicle; and

Conoid (*ligamentum conoideum*), behind and internal, arises from base of coracoid process, and is inserted into conoid tubercle on under side of clavicle and a line internal to it.

The ligaments surrounding the joint form a *capsule.*

The *arteries* are from anterior circumflex, acromial thoracic and suprascapular.

The *nerves* are anterior circumflex and suprascapular.

The scapula has, also,

The coracoacromial (*ligamentum coracoacromiale*), arising from the outer border of the coracoid process and inserted into the summit of the acromion, and

Transverse (*ligamentum transversum scapulæ superius*), a ligamentous band bridging the suprascapular notch, converting it into a foramen for suprascapular nerve.

The shoulder joint (*articulatio humeri*) is an enarthrodial joint, formed above by the glenoid cavity of the scapula and below by the head of the humerus. Its ligaments are: glenoid, coracohumeral and capsular.

The glenoid (*labrum glenoidale*) surrounds the edge, deepens the glenoid cavity, and is continuous above with the long head of the biceps tendon.

The capsular ligament (*capsula articularis*), extensive and loose, arises above it from circumference of glenoid cavity behind the ligament, is attached below to the anatomical neck of humerus, and is pierced by tendons of two or three muscles.

The coracohumeral, or accesory (*ligamentum coracohumerale*), is a fibrous band which extends obliquely downward and outward from the coracoid process to the anterior part of great tuberosity, strengthening the capsular ligament.

The synovial membrane is extensive and reflected upon the tendon of biceps, which is inclosed in a tubular sheath of synovial membrane (*vagina mucosa intertubercularis*), and upon the infraspinatus, and subscapularis muscles.

Its *arteries* are derived from the subscapular, suprascapular, dorsalis scapulæ, anterior and posterior circumflex;

Its *nerves*, from the subscapular, suprascapular and circumflex.

The elbow joint (*articulatio cubiti*) is a ginglymoid articulation formed above by the lower extremity of humerus, below by upper extremities of ulna and radius. Its ligaments are external and internal lateral, anterior and posterior ligaments.

External lateral (*ligamentum collaterale radiale*) arises from external condyle of humerus and is inserted into outer margin of ulna. Internal lateral (*ligamentum collaterale ulnare*), much stronger, consists of two portions; *anterior* arises from fore part of internal condyle to be inserted into coronoid

process, and *posterior* from back part of condyle to inner margin of olecranon.

Anterior ligament arises above coronoid fossa, and is inserted into coronoid process of ulna and orbicular ligament.

Posterior ligament, attached above olecranon fossa, and below to olecranon process of ulna. The anterior and posterior ligaments become continuous with the lateral to encircle the joint.

The *arteries* are derived from superior and inferior pro-

FIG. 64.

1, anterior ligament; 2 and 2, anterior and posterior portions of internal lateral; 3, orbicular ligament; 4, oblique; 5, interosseous membrane.

funda, anastomotica magna, posterior interosseous recurrent, anterior and posterior ulnar recurrent and radial recurrent.

The *nerves*, from median, ulnar, musculocutaneous and musculospiral.

THE RADIOULNAR ARTICULATIONS (*articulatio radioulnaris*) are three: the superior, middle and inferior.

The superior radioulnar (*articulatio radioulnaris proximalis*) is a diarthrosis rotatoria, formed by the inner side of the head of radius and lesser sigmoid cavity of ulna. Its synovial cavity communicates with the elbow joint, and it is

held together by the orbicular, or annular ligament (*ligamentum annulare radii*), attached in front and behind to the lesser sigmoid cavity and surrounding the head of radius. Its *arteries* and *nerves* are the same as for elbow.

The *middle radioulnar articulation* consists of the oblique, or round ligament (*chorda obliqua*), passing from tubercle of ulna to below tuberosity of radius, and the interosseous (*membrana interossea antibrachii*) passing between the bones, deficient above for passage of posterior interosseous vessels, and perforated below for anterior vessels. Its *arteries* are from *anterior* interosseous; its *nerves,* from *anterior* and *posterior* interosseous.

Inferior radioulnar (*articulatio radioulnaris distalis*) consists of *anterior* and *posterior radioulnar ligaments,* passing from one to the other in front and back of wrist, and triangular interarticular fibrocartilage (*discus articularis*), interposed between head of ulna and cuneiform bone, and binding the radius and ulna firmly together. Its *arteries* are from anterior and posterior interosseous and carpal; its *nerves,* from median and posterior interosseous.

The radiocarpal (*articulatio radiocarpea*), or wrist joint, is a condyloid joint consisting of an elliptical cavity formed by the radius and triangular cartilage, into which fits the convex surfaces of the scaphoid, semilunar and cuneiform below. Its ligaments are external and internal lateral, anterior and posterior radiocarpal.

External lateral (*ligamentum collaterale carpi radiale*) passes from the styloid process of radius to the scaphoid, os magnum and trapezium.

Internal lateral (*ligamentum collaterale carpi ulnare*) passes from the styloid process of ulna to the cuneiform, pisiform and annular ligament.

The anterior radiocarpal, or volar ligament (*ligamentum radiocarpeum volare*), is a broad membrane attached above to the anterior margin of the radius, its styloid process and ulna, and below to cuneiform, semilunar, scaphoid and os magnum, strengthened by a band extending from styloid process of ulna to semilunar and cuneiform.

The posterior radiocarpal, or dorsal ligament (*ligamentum radiocarpeum dorsale*), is attached to dorsal margin of radius, and below to cuneiform, semilunar and scaphoid. The anterior and posterior radiocarpal belong to the annular ligament (*vide* fascias).

Its *arteries* are the anterior and posterior carpal, derived

from the radial and ulnar, anterior and posterior interosseus, and ascending branches from the deep palmar arch.

Its *nerves* are derived from the median, ulnar and posterior interosseous.

The carpal articulations (*articulatio intercarpea*) are arthrodial, and consist of three sets. The first row is held together by two palmar, two dorsal and two interosseous; the second row by three dorsal, three palmar and three interosseous; and the two rows are held together by a palmar, dorsal, internal and external lateral ligament.

First Row.—The palmar, or volar (*ligamenta intercarpea volaria*), and dorsal ligaments (*ligamenta intercarpea dorsalia*), connect the scaphoid and semilunar, and semilunar and cuneiform together on the front and back.

The interosseous (*ligamenta intercarpea interossea*) connect the semilunar with the scaphoid and cuneiform.

The *pisiform* bone has a separate capsular ligament and an interosseous ligament connecting it to the fifth metacarpal bone and cuneiform.

Second Row.—The palmar (*ligamenta intercarpea volaria*), and dorsal ligaments (*ligamenta intercarpea dorsalia*), connect the trapezium with the trapezoid, and the os magnum with the trapezoid and unciform, on the front and back of the wrist.

The interosseus (*ligamenta intercarpea interossea*) connect the adjacent surfaces of the trapezium and trapezoid, and the os magnum with the trapezoid and unciform.

Two Rows Together.—The palmar (*ligamenta intercarpea volaria*) and dorsal (*ligamenta intercarpea dorsalia*) connect the bones of the first with the second rows on the front and back of the wrist. The *internal lateral* passes on the ulnar side between the cuneiform and unciform. The *external lateral*, stronger, passes on the radial side between the scaphoid and trapezium.

The anterior annular ligament (*ligamentum carpi transversum*) contributes strength to these joints.

The *arteries* are: Carpal of anterior interosseus, anterior and posterior carpals of radial and ulnar, carpal of deep palmar arch, interosseous recurrent, and terminal branches of anterior and posterior interosseus.

The *nerves* are from median, ulnar and posterior interosseus.

The carpometacarpal articulations (*articulationes carpometacarpeæ*) are each arthrodial joints, held together by dor-

sal, palmar, interosseous and capsular ligaments, except the thumb, which has only capsular.

The capsular ligament (*capsula articularis*) of the thumb surrounds the margins of the articular surfaces of the first metacarpal and trapezium, and is lined by a separate synovial sac.

The palmar, or volar ligaments (*ligamenta carpometacarpea volaria*), and dorsal carpometacarpal (*ligamenta carpometacarpea dorsalia*), connect the carpus and metacarpus on the palmar and dorsal surface.

The *interosseus* connect the adjoining inferior angles of os magnum and unciform with the contiguous surfaces, fourth and fifth metacarpal bones.

The *synovial membranes* of the wrist consist of five distinct sacs: First, *membrana sacciformis* lines lower end of ulna, sigmoid cavity of radius and upper surface of triangular cartilage; second, lower surface of radius and cartilage and upper surface of first row of carpus; third, between margins of carpus and carpometacarpal joints; fourth, between carpometacarpal joint of thumb; and fifth, between pisiform and cuneiform.

Intermetacarpal Articulation.—The bases of the metacarpal bones, except the thumb, articulate with one another by arthrodial joints, lined by synovial membrane continuous with the carpal sac and connected together by palmar (*ligamenta basium oss. metacarp. volaria*), dorsal (*ligamenta basium oss. metacarp. dorsalia*), and interosseous (*ligamenta basium oss. metacarp. interossea*) ligaments. The digital extremities are connected by a transverse ligament (*ligamentum capitulorum oss. metacarpalium transversum*) across the anterior surface, continuous with anterior metacarpophalangeal ligament.

The METACARPOPHALANGEAL (*articulationes metacarpophalangeæ*) and PHALANGEAL are of the condyloid variety, like the wrist joint, allowing of motion in every direction except laterally. They are each connected by one anterior palmar, or vaginal ligament (glenoid ligament of Cruveilhier, *ligamentum vaginale*), and two lateral, or collateral ligaments (*ligamenta collateralia*), the posterior ligament being substituted by the extensor tendon, which crosses the dorsum of the joint.

The *arteries* and *nerves* are from the digitals.

ARTICULATIONS OF THE LOWER EXTREMITY.

The HIP JOINT (*articulatio coxæ*) is a true enarthrodial articulation, formed above by deep cup-like cavity of acetabu-

lum, below by prominent spherical head of femur. Its ligaments are the capsular, iliofemoral, teres, cotyloid and transverse.

The capsular ligament (*capsula articularis*), dense and strong, is attached above to margin of acetabulum and cotyloid ligament, and below to the spiral line in front and to the neck behind. It is strengthened by several accessory bands, the pubofemoral (*ligamentum pubocapsulare*), iliotrochanteric, ischiocapsular (*ligamentum ischiocapsulare*), and iliofemoral (*ligamentum iliofemorale*). Of these the latter is the most important, arising above from anterior inferior spine, and attached below to spiral line, and has received the name of Y-ligament of Bigelow.

The ligamentum teres (*ligamentum teres femoris*), or round ligament, is a strong triangular band, its base arising from the bottom of acetabulum and margins of cotyloid notch externally, its apex inserted below and behind center of head of femur.

The cotyloid ligament (*labrum glenoidale*) encircles and deepens the acetabulum, and at the inner side, under the name of the transverse ligament (*ligamentum transversum acetabuli*), it bridges over the cotyloid notch, converting it into a foramen for the passage of nutrient vessels to the joint.

There are numerous bursa about the joint, with one of which, beneath the iliopsoas muscle, the synovial membrane often communicates.

Its *arteries* are derived from the sciatic, internal and external circumflex, obturator and gluteal.

Its *nerves* are derived from the great sciatic, obturator, accessory obturator and the sacral plexus.

The knee joint (*articulatio genu*) is a ginglymoid articulation, formed above by condyles of femur, below by head of tibia, and in front by patella.

Its *ligaments* are divided into two sets, the external, consisting of anterior, posterior, internal lateral, two external laterals and capsular; and internal, consisting of anterior, posterior, two semilunar fibrocartilages, transverse, coronary, ligamentum mucosum and ligamenta alaria. Its joint surface is the most extensive in the body.

External Set.—Anterior, or *ligamentum patella,* is the tendinous portion of extensors of thigh between patella and tubercle of tibia. The posterior (*ligamentum popliteum obliquum*), or *ligamentum posticum Winslowii,* derived principally from the tendon of semimembranosus, arises from inner tuber-

osity of tibia, passes upward and outward to be inserted into external condyle of femur.

The internal lateral (*ligamentum collaterale tibiale*) is a flat and broad ligament arising from back part of inner condyle of femur, descends forward to be inserted into inner tuberosity of tibia, covering in its course the inferior internal articular artery and nerve, part of tendon of semimembranosus, and attaching itself to the internal semilunar fibrocartilage.

The long external lateral ligament (*ligamentum collaterale fibulare*), round and strong, arises from tuberosity on outer part of external condyle, and descends forward to the head of fibula. The short external lateral ligament (*ligamentum laterale externum breve seu posticum*) is an accessory, not very constant, band, descending posteriorly to the preceding.

The capsular ligament (*capsula articularis*) fills up the intervals between the preceding ligaments, and is strengthened by bands from fascia lata, vasti, crureus, semimembranosus, biceps and sartorius tendons.

Internal Set.—Crucial ligaments (*ligamenta cruciata genu*) are two strong, short, interosseous, crossing each other from before backward. The anterior, or external (*ligamentum cruciatum anterius*), arises from inner posterior part of condyle of femur, and descends forward and inward to be inserted into front of spine of tibia and internal semilunar cartilage.

The posterior, or internal (*ligamentum cruciatum posterius*), arises from outer fore part of inner condyle of femur, descends downward, backward and outward to spine of tibia.

The *semilunar fibrocartilages* (*menisic*) consist of two crescentic laminæ of interarticular cartilage, resting upon the upper articular surface of tibia, which serve to deepen its surface.

The internal (*meniscus medialis*) is attached by its inner border to internal lateral ligament and to head of tibia by coronary ligaments, its extremities attached in front of anterior crucial ligament and behind the spine.

The external (*meniscus lateralis*), more circular, is connected to edge of tibial head by coronary ligaments, its extremities being inserted behind and in front of the tibial spine.

In other words, the ends of the semilunar cartilages are all, except the anterior end of internal, attached to the tibia between the crucial ligaments.

A band of fibers passing from the anterior margin of external cartilage to the internal has received the name of transverse ligament (*ligamentum transversum genu*).

The knee is lined by the most extensive synovial membrane in the body, covering both surfaces throughout and extending up between quadriceps tendon and surface of femur.

Below the patella in front is a duplicature of synovial membrane, inclosing some adipose tissue, which has received the name of ligamentum mucosum (*plica synovialis patellaris*), and extending from it are two fringes—the ligamenta alaria (*plicæ alares*).

On either side in the popliteal space behind are bursæ, which often communicate with the joint.

There are also bursæ over the patellæ, above and beneath

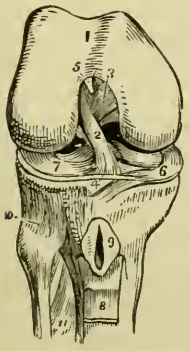

FIG. 65.

2, anterior crucial ligament; 3, posterior crucial ligament; 4, transverse ligament; 6, 7, internal and external semilunar cartilages; 8, ligamenta patellæ; 9, bursa patellæ; 10, anterior superior tibiofibular ligament.

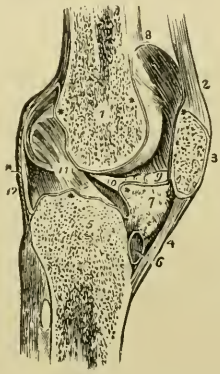

FIG. 66.

2, quadriceps extensor; 3, patella; 4, ligamentum patellæ; 6, bursa; 7, 8, 9, synovial membrane of knee joint; 10, anterior crucial ligament.

the ligamentum patellæ, and between the inner hamstring and head of tibia.

The *arteries* of the knee joint are derived from the anastomotica magna, the articular branches of the popliteal (five), and the recurrent branch of the anterior tibial.

Its *nerves* are derived from the anterior crural, obturator, external and internal popliteal nerves.

THE TIBIOFIBULAR ARTICULATIONS (*articulatio tibiofibularis*) are three—superior, middle and inferior. The *superior* is an arthrodial joint between fibular head and outer tuberosity of tibia, and consists of *anterior superior* and *posterior superior*

ligaments[1] stretching on either side of the outer tuberosity, downward and backward, to the head of the fibula. The *arteries* are same as the knee; the *nerves,* from external popliteal.

The *middle* consists of an interosseous membrane (*membrana interossea cruris*) between the bones, connecting them firmly together, deficient above, for passage forward of anterior tibial artery and below for anterior peroneal vessels.

The inferior (*syndesmosis tibiofibularis*) is an arthrodial joint between contiguous inferior surfaces of tibia and fibula, and consists of four: the *interosseus,* continuous with that above; the anterior inferior tibiofibular (*ligamentum malleoli lateralis anterius*), extending downward and outward between tibia and fibula in front; the posterior inferior tibiofibular (*ligamentum malleoli lateralis posterius*), occupying a similar position behind; and the *transverse,* a long narrow band, passing between external malleolus and tibia. The synovial membrane is continuous with that of ankle-joint. The *arteries* and *nerves* are the same as those to the ankle.

The ankle-joint (*articulatio talocruralis*) is a ginglymoid articulation, formed between the lower extremity and malleolus of tibia on the inner side, the malleolus of the fibula on the outer side, and the astragalus below. Its ligaments are anterior, posterior, external and internal lateral.

The anterior tibiotarsal ligament (*ligamentum talotibiale anterius*) consists of a broad set of irregular fibers, attached above to lower margin of tibia, below to astragalus. The posterior tibiotarsal ligament (*ligamentum talotibiale posterius*) passes transversely between back part of tibia and astragalus.

The internal lateral, or deltoid (*ligamentum calcaneotibiale* or *ligamentum deltoideum*), has two layers—the superficial triangular, its apex arising from malleolus, its base spread out from before backward to be attached to scaphoid and inferior calcaneoscaphoid ligament, the sustentaculum, and inner side of astragalus; and the deep, a short, round cord passing from internal malleolus to astragalus.

The external lateral ligament (*ligamenta talofibularia et calcaneofibulare*) consists of three distinct fasciculi, anterior (*ligamentum talofibulare anterius*), middle (*ligamentum calcaneofibulare*), and posterior (*ligamentum talofibulare posterius*), arising from near summit of external malleolus, and

[1] The new anatomical nomenclature (BNA) [inserted throughout the present edition of this volume] considers the anterior superior and the posterior superior tibiofibular ligaments as one ligament (*ligamentum capituli fibulæ*).

being inserted respectively into the front of astragalus, the outer surface of os calcis, and the back of astragalus.

The *arteries* of the ankle-joint are derived from the malleolar branches of the peroneal and anterior tibial.

Its *nerves* are branches of the anterior and posterior tibial nerves.

The articulations of the tarsal bones (*articulationes intertarseæ*) consist of those of the first row, those of the second row, and of the two rows with each other.

First Row.—The astragalus articulates with the calcaneum by two distinct surfaces separated by the interosseous groove, and firmly connected by the external (*ligamentum talocalcaneum laterale*), and posterior (*ligamentum talocalcaneum posterius*) calcaneoastragaloid ligaments, and the interosseus (*ligamentum talocalcaneum interosseum*). The external calcaneoastragaloid ligament passes vertically downward from the outer surface of astragalus to outer surface of calcaneum. The posterior is a short, narrow, oblique band connecting the posterior border of astragalus to the os calcis.

The interosseus (*ligamentum talocalcaneum interosseum*) is a strong, short ligament passing vertically and obliquely downward between the two bones, the principal bond of union.

The *arteries* of the first row are tarsal from dorsalis pedis, external malleolar from anterior tibial, and branches of peroneal from posterior tibial.

Nerves, from posterior tibial, or plantar.

The second row is firmly held together by *dorsal, plantar* and *interosseous* ligaments. The two former unite the dorsal and plantar surfaces and the interosseous, four strong bands connect the scaphoid and cuboid (*articulatio cubonavicularis*), the internal and middle, the middle and external cuneiform, and the external cuneiform and cuboid.

The *arteries* of the second row are from plantars and metatarsals. *Nerves,* from anterior tibial, and internal and external divisions of posterior tibial nerves.

The two rows of the tarsus (*articulationes intertarseæ*) are connected with each other by three sets of ligaments, first between os calcis and cuboid, consisting of superior (*ligamentum calcaneocuboideum dorsale*) and internal calcaneocuboid (*pars calcaneocuboidea ligamenti bifurcati*), long (*ligamentum plantare longum*), and short calcaneocuboid (*ligamentum calcaneocuboideum plantare*); second, between os calcis and scaphoid, consisting of superior or external, or calcaneonavicular (*pars calcaneonavicularis ligamenti bifurcati*), and inferior

calcaneoscaphoid, or internal or calcaneonavicular (*ligamentum calcaneonaviculare plantare*); and third, between astragalus and scaphoid (*articulatio talonavicularis*), consisting of a single *superior astragaloscaphoid ligament,* a band passing from neck of astragalus to upper surface of scaphoid.

Calcaneocuboid.—The superior (*ligamentum calcaneocuboideum dorsale*) passes between dorsal surfaces of os calcis and cuboid. The internal (*pars calcaneocuboidea ligamenti bifurcati*) passing from os calcis to inner side of cuboid, is one of the main bonds of union between the two rows of tarsus.

The *inferior* firmly connects the bones below, the *ligamentum longæ plantæ* passing from os calcis forward to the plantar surface of the cuboid, and sending fibers forward to bases of second, third and fourth metatarsal bones; the *ligamentum breve plantæ* passing from fore and under surface of os calcis to under surface of cuboid. The two preceding are important in preserving the arch of the foot.

The *superior* and *inferior calcaneoscaphoid* pass above and below these bones, firmly connecting them.

The *arteries* of the mediotarsal joints are derived from the anterior tibial, tarsal, metatarsal, or external plantar.

Nerves, from external branch of anterior tibial.

The tarsometatarsal articulations (*articulationes tarsometatarseæ*) are firmly held together by dorsal (*ligamenta tarsometatarsea dorsalia*) and plantar (*ligamenta tarsometatarsea plantaria*) ligaments, and connected with one another by interosseous bands (*ligamenta cuneometatarsea interossea*), three in number, passing between internal cuneiform and second metatarsal bone, external cuneiform and second metatarsal, and external cuneiform and third metatarsal.

The *arteries* are from metatarsal, dorsalis pedis, and deep plantar arch;

The *nerves* are from anterior tibial and external plantars.

Intermetatarsal Articulations. (*articulationes intermetatarseæ*).—The bases of all except the first are connected by dorsal (*ligamenta basium* [*oss. metatars.*] *dorsalia*), plantar (*ligamentum basium* [*oss. metatars.*] *plantaria*), and the interosseous ligaments (*ligamenta basium* [*oss. metatars.*] *interossea*), and the distal extremities are connected by the transverse metatarsal ligament.

The *synovial membranes* concerned in these articulations are six: (1) between the calcaneoastragaloid articulation, posterior to interosseous membrane; (2) anterior calcaneoastraga-

loid and astragaloscaphoid; (3) calcaneocuboid; (4) between the middle and the external cuneiform, scaphoid and three cuneiform, middle and external cuneiform, and second and third metatarsal, and between the cuboid and the external cuneiform and the scaphoid; (5) between the internal cuneiform and first metatarsal; and (6) between the cuboid and the fourth and fifth metatarsal.

The metatarsophalangeal articulations (*articulationes metatarsophalangeæ*) are each connected by two lateral (*ligamenta collateralia*), and a plantar ligament or glenoid ligaments of Cruveilhier (*ligamenta accessoria plantaria*) and the phalangeal articulations are the same, the extensor tendons acting as dorsal ligaments. They resemble in every respect the articulations in the hand (*vide* Hand).

THE MUSCULAR SYSTEM.

THE *muscles* constitute 45 per cent. of the body weight and are the active agents of locomotion.

They consist of two kinds—the NON-STRIATED or involuntary, and the STRIATED, or voluntary. The latter, being usually under the control of the will (the heart being a notable exception), have also received the name of *voluntary,* and the former, not under the control of the will, *involuntary.*

Microscopically, their *structure* is as follows:—

Non-striated muscular tissue is made up of elongated, contractile, nucleated fiber-cells. They consist of minute fibers in bundles, inclosed in extremely delicate sheaths of connective tissue.

They are held together by an albuminous cement and collected by connective tissue into groups or masses one-tenth to one five-hundredth of an inch in length.

Non-striated muscular tissue is highly vascular and is supplied with nerves from the sympathetic.

Striated muscular tissue is made up of spindle-shaped fibers of from one and a half to two inches in length and one-two-hundredth to one-six-hundredth of an inch in diameter. They are held together in bundles by the *endomysium,* a delicate fibro-connective tissue. These bundles are collected into groups by the *perimysium,* a stronger connective-tissue band, forming the fasciculi of the fully formed muscle. Striated muscular tissue is also highly vascular.

The parts of an individual fiber are—first, the *sarcolemma,* a very delicate, transparent, elastic sheath; second, the *membranes of Krause,* which appear as dark lines stretching across the fiber at regular intervals, forming the third, or the *compartments of Krause,* which contain the muscular substance. The latter contain the multinucleated *muscle-cells.*

The striated muscular fibers of the heart differ somewhat from the preceding, being branched, and dividing and subdividing longitudinally to form an intricate network.

The muscles are connected to cartilages, ligaments, bones and skin, either directly or by aponeuroses or tendons.

Aponeuroses are dense, white, fibrous membranes, serving to connect the muscles with the structures to be acted upon.

Tendons are white, fibrous, glistening cords. They are composed of white, fibrous tissue, arranged into bands or bundles. They are attached to the perichondrium, periosteum, ligaments and subcutaneous tissue by a mutual interlacement of fibers.

Classification.—Muscles are classified according to region of the body, their physiological action, or from their embryological development. The former arrangement is retained here for practical purposes.

Names of Muscles.—They have received their names:—

1. From the arrangement of their fibers they are designated radiated, penniform, bipenniform, etc.
2. From their uses they are called extensors, adductors, etc.
3. From their direction, oblique, rectus, transversalis, etc.
4. From the number of insertions, as triceps, biceps, etc.
5. From their form, as rhomboid, deltoid, etc.
6. From their attachment, as occipitofrontalis, sternohyoid, etc.

The origin refers to the fixed extremity, or head (*caput*); the insertion, to the movable point.

Muscles of the Head.

CRANIAL REGION.

Occipitofrontalis (*m. epicranius*).—*Origin,* by two bellies, one from outer two-thirds of superior curved line of the occipital bone and base of the mastoid process of the temporal, the other from corrugator supercilii, orbicularis palpebrarum and pyramidalis nasi fibers; *insertion,* into fibrous aponeurosis covering the vertex of the skull; *action,* raises the eyebrows and used chiefly as a muscle of facial expression; *nerves,* supraorbital, small occipital, facial and posterior auricular branch of facial.

AURICULAR REGION.

Attollens Aurem (*m. auricularis superior*).—*Origin,* from aponeurosis of occipitofrontalis; *insertion,* into the surface of the pinna; *action,* raises the ear; *nerve,* occipitalis minor.

Attrahens Aurem (*m. auricularis anterior*).—*Origin,* from edge of occipitofrontalis aponeurosis; *insertion,* into anterior part of helix; *action,* draws the ear upward and forward; *nerve,* facial.

Retrahens Aurem (*m. auricularis posterior*).—*Origin,* from mastoid portion of temporal bone; *insertion,* into lower

part of concha; *action,* draws the ear backward; *nerve,* posterior auricular branch of facial.

PALPEBRAL REGION.

ORBICULARIS PALPEBRARUM (*m. orbicularis oculi*).—*Origin,* from nasal process of superior maxilla, internal angular process of frontal, and from front and sides of tendo palpebrarum; *insertion,* into skin of the cheek, eyelids, forehead and temple, blending with the corrugator supercilii and the occipitofrontalis; *action,* sphincter of the eyelids; *nerve,* facial.

TENDO PALPEBRARUM (TENDO OCULI), or internal tarsal ligament (*ligamentum palpebrale mediale*).—*Origin,* nasal process of superior maxilla; *insertion,* inner part of tarsal cartilage.

CORRUGATOR SUPERCILII.—*Origin,* superciliary ridge; *insertion,* into orbicularis about the middle of the orbital arch; *action,* draws eyebrows inward and downward and wrinkles the forehead; *nerve,* facial.

TENSOR TARSI, or Horner's muscle (*pars lacrimalis* of the *orbicularis palpebrarum*).—*Origin,* from crest and orbital surface of lachrymal gland; *insertion,* into tarsal cartilages near the puncta lachrymalia; *action,* draws the lachrymal canals inward and against the globe of the eye; *nerve,* facial.

ORBITAL REGION.

LEVATOR PALPEBRÆ SUPERIORIS.—*Origin,* from lesser wing of the sphenoid, near the optic foramen; *insertion,* superior border of tarsal cartilage; *action,* elevates the upper eyelid; *nerve,* third cranial, or motor oculi.

RECTUS SUPERIOR (*m. rectus superior*).—*Origin,* sheath of the optic nerve and upper margin of optic foramen; *insertion,* into upper surface of sclerotic coat; *action,* rotates the eyeball upward; *nerve,* third cranial.

RECTUS INFERIOR (*m. rectus inferior*).—*Origin,* from lower and inferior part of optic foramen (ligament of Zinn); *insertion,* into lower surface of sclerotic; *action,* rotates the eyeball downward; *nerve,* third cranial.

RECTUS INTERNUS.—*Origin,* same as rectus inferior; *insertion,* into inner surface of sclerotic; *action,* rotates the eyeball inward; *nerve,* third cranial.

RECTUS EXTERNUS (*m. rectus lateralis*).—*Origin,* by two heads—lower from ligament of Zinn and lower margin of sphenoidal fissure, upper from outer margin of optic foramen; *insertion,* into outer surface of sclerotic; *nerve,* abducens, or

sixth cranial. Passing between the two heads are the ophthalmic vein, the third, nasal branch of fifth, and sixth nerves.

Superior Oblique (*m. obliquus superior*).—*Origin,* from inner margin of optic foramen: its tendon passes through a pulley near the internal angular process of the frontal bone; *insertion,* into sclerotic, between external and superior recti, midway between entrance of optic nerve and the cornea; *action,* rotates the eyeball on its axis; *nerve,* fourth, or patheticus.

Inferior Oblique (*m. obliquus inferior*).—*Origin,* orbital plate of superior maxilla; *insertion,* near that of superior oblique, between external and superior recti; *action,* rotates the eyeball on its axis; *nerve,* third cranial.

NASAL REGION.

Pyramidalis Nasi or Procerus.—*Origin,* from the occipitofrontalis; *insertion,* into the compressor nasi; *action,* lowers the inner angle of the eyebrows; *nerve,* facial.

Levator Labii Superioris Alæque Nasi.—*Origin,* nasal process of superior maxilla; *insertion,* the ala of the nose and upper lip, blending with the levator labii oris proprius and orbicularis; *action,* dilates the nostril and elevates the upper lip; *nerve,* facial.

Dilator Naris Posterior.—*Origin,* nasal notch of superior maxilla; *insertion,* into skin at the margin of the nostril.

Dilator Naris Anterior.—*Origin,* from cartilage of the ala; *insertion,* into the skin of nose; *action,* dilates the nostrils; *nerve,* facial.

Compressor Nasi.—*Origin,* superior maxilla, near the incisive fossa; *insertion,* into fibrocartilage of the nose, continuous with the pyramidalis nasi aponeurosis and its fellow; *action,* dilates the nostril; *nerve,* facial.

Compressor Narium Minor.—*Origin,* from alar cartilage; *insertion,* into the skin of the end of the nose; *action,* dilates the nostril; *nerve,* facial.

Depressor Alæ Nasi (*depressor septi*).—*Origin,* incisive fossa of superior maxilla; *insertion,* into the ala of the nose; *action,* contracts the nostril; *nerve,* facial.

MAXILLARY REGION.

Levator Labii Superioris (*proprius*).—*Origin,* above infraorbital foramen to malar and superior maxilla; *insertion,* into the upper lip; *action,* elevates the upper lip; *nerve,* facial.

Levator Anguli Oris (*m. caninus*).—*Origin,* from canine fossa; *insertion,* into the angle of the mouth, blending with the depressor anguli oris, orbicularis, and zygomatici; *action,* draws the angle inward and raises it; *nerve,* facial.

Zygomaticus Major (*m. zygomaticus*).—*Origin,* from malar bone; *insertion,* into angle of mouth, blending with depressor anguli oris and orbicularis.

Zygomaticus Minor.—*Origin,* from malar bone; *insertion,* at the angle of the mouth, blending with the levator superioris; *action,* draws the lip outward and upward; *nerve,* facial.

Levator Labii Inferioris (*m. mentalis*).—*Origin,* from incisive fossa of lower jaw; *insertion,* into the skin of the chin; *action,* raises the lower lip; *nerve,* facial.

Depressor Labii Inferioris, or quadratus menti (*m. quadratus labii inferioris*).—*Origin,* from external oblique line of lower jaw; *insertion,* into skin of lower lip, blending with its fellow and the orbicularis; *action,* lowers the angle of the mouth; *nerve,* facial.

Depressor Anguli Oris, or triangularis menti (*m. triangularis*).—*Origin,* external oblique line of lower jaw; *insertion,* into the angle of the mouth, continuous with the orbicularis and risorius at its insertion and the platysma at its origin; *action,* depresses the angle of the mouth; *nerve,* facial.

Orbicularis Oris.—*Origin,* by accessory fibers (accessorii orbicularis superioris and inferioris and nasolabialis), from superior and inferior maxillary borders and nasal septum; *insertion,* into the buccinator and adjoining muscles, forming the sphincter of the mouth; *action,* closes the lips; *nerve,* facial.

Buccinator.—*Origin,* from pterygomaxillary ligament and the posterior alveolar processes of the upper and lower jaw; *insertion,* into orbicularis oris; *action,* compresses and contracts the cheeks; *nerves,* facial and buccal branch of the inferior maxillary nerve.

Risorius (*m. risorius*) (Santorini).—*Origin,* from fascia of masseter muscle; *insertion,* at angle of the mouth; *action,* draws back the angles of the mouth,—the "smiling" muscle; *nerve,* facial.

Masseter: Superficial Portion.—*Origin,* inner surface of zygoma and malar process of superior maxilla; *insertion,* into the ramus and angle of the lower jaw.

Deep Portion.—*Origin,* posterior border and inner surface of the zygoma; *insertion,* into the ramus and coronoid process of the jaw; *action,* raises the lower jaw, and the super-

ficial portion assists in drawing it forward; *nerve,* inferior maxillary.

Temporal (*m. temporalis*).—*Origin,* from the temporal fascia and the temporal fossa; *insertion,* into the coronoid process of the lower jaw; *action,* raises and draws backward the lower jaw; *nerve,* inferior maxillary.

Internal Pterygoid (*m. pterygoideus internus*).—*Origin,* from pterygoid fossa and the tuberosity of the palate-bone; *insertion,* into the inner side of the ramus and angle of the lower jaw; *action,* draws forward and raises the lower jaw; the accessory triturating muscle of mastication; *nerve,* inferior maxillary.

External Pterygoid (*m. pterygoideus externus*).—*Origin,* by two heads—the lower from the tuberosities of the palate and superior maxilla and from the external pterygoid plate, the upper from the pterygoid ridge on the greater wing of the sphenoid; *insertion,* into the front of the neck of the lower jaw and inner side of interarticular cartilage; *action,* draws the jaw forward; triturating muscle of mastication; *nerve,* inferior maxillary.

Muscles of the Ear (*vide* Ear).

Muscles of the Neck.

SUPERFICIAL CERVICAL REGION.

Platysma Myoides (*m. platysma*).—*Origin,* from the deep fascia over the trapezius, deltoid, and pectoral muscles, and from the clavicle and acromion; *insertion,* into the lower jaw and skin of the face; *action,* wrinkles the skin of the neck and protects the air-passages and blood-vessels from external pressure,—rudimentary in man; *nerves,* branch of superficial cervical plexus and the facial.

Sternocleidomastoid (*m. sternocleidomastoideus*).—*Origin,* by two heads—sternal portion from the fore and upper part of the manubrium sterni, the clavicular portion from the inner third of the upper border of the clavicle, leaving a triangular interval; *insertion,* into the mastoid process and outer two-thirds of the superior curved line of the occipital bone; *action,* rotates and depresses the head; *nerves,* spinal accessory and branches of the cervical plexus.

INFRAHYOID REGION.

Sternohyoid (*m. sternohyoideus*).—*Origin,* from upper and back part of the manubrium sterni and inner extremity of

the clavicle; *insertion,* into the lower border of the os hyoides; *action,* depresses the hyoid bone; *nerve,* branch from the loop of communication between the descendens and communicans noni.

STERNOTHYROID (*m. sternothyroideus*).—*Origin,* posterior surface of manubrium sterni; *insertion,* into oblique line of the surface of the thyroid cartilage; *action,* depresses the larynx; *nerve,* branch from the communicating loop above.

THYROHYOID (*m. thyreohyoideus*).—*Origin,* from the oblique line on the surface of the thyroid cartilage; *insertion,* into the greater cornu and body of the hyoid bone; *action,* elevates the larynx; *nerve,* hypoglossal.

OMOHYOID (*m. omohyoideus*).—*Origin,* from the upper border of the scapula and the transverse ligament; *insertion,* into the lower border of the os hyoides; its center is tendinous and bound down to the cartilage of the first rib by a process of the deep cervical fascia; *action,* depresses the hyoid bone and draws it backward; *nerve,* from the communicating loop above.

SUPRAHYOID REGION.

DIGASTRIC (*m. digastricus*).—*Origin,* by two bellies—posterior from digastric groove of mastoid process of the temporal bone, anterior from a depression in the lower border of the jaw near the symphysis; the tendon is held to the hyoid bone by an aponeurotic loop and pierces the stylohyoid; *action,* raises the tongue and hyoid bone; *nerve,* mylohyoid branch of the inferior dental and facial.

STYLOHYOID (*m. stylohyoideus*).—*Origin,* from outer surface of styloid process; *insertion,* into the body of the hyoid bone; *action,* retracts and elevates the hyoid bone; *nerve,* facial: near its insertion it is perforated by the tendon of the digastric.

MYLOHYOID (*m. mylohyoideus*).—*Origin,* from the mylohyoid ridge of the inferior maxilla from last molar to symphysis; *insertion,* into a fibrous *raphé* in the median line, extending from the hyoid bone to the chin and into the body of the hyoid bone; *action,* draws forward and elevates the hyoid bone and forms part of the floor of the mouth; *nerve,* mylohyoid branch of the inferior dental.

GENIOHYOID (*m. geniohyoideus*).—*Origin,* from inferior genial tubercle of the internal surface of the symphysis of the jaw; *insertion,* into the front of the body of the hyoid bone; *action,* same as the mylohyoid; *nerve,* hypoglossal.

MUSCLES OF THE TONGUE.

Genioiiyoglossus (*m. genioglossus*).—*Origin,* from superior genial tubercle of the internal surface of the symphysis of the jaw; *insertion,* by fanlike expansion into the whole length of the inferior surface of the tongue, the side of the pharynx, and the body of the hyoid bone; *action,* retracts and protrudes the tongue; *nerve,* the hypoglossal.

Hyoglossus (*m. hyoglossus*).—*Origin,* body and greater cornu of the hyoid bone; *insertion,* between the lingualis and styloglossus into the side of the tongue; *action,* renders the tongue convex from side to side; *nerve,* hypoglossal.

Styloglossus (*m. styloglossus*).—*Origin,* from stylomaxillary ligament and styloid process of the temporal: *insertion,* into the side of the tongue, blending with the hyoglossus and lingualis; *action,* retracts and elevates the tongue; *nerve,* hypoglossal.

Lingualis.—Consists of four portions: superior lingualis (*m. longitudinalis superior*), very superficial from base to apex, just beneath the mucosa of the dorsum; inferior lingualis (*m. longitudinalis inferior*), two muscle-bands from base to apex on inferior surface; transverse lingualis (*m. transversus linguæ*), and the vertical lingualis (*m. verticalis linguæ*), as indicated by their names, send transverse fibers between the superior and inferior muscles, the latter sending muscle-fibers from dorsum to mucosa and interlacing with the other muscles. *Action,* renders the tongue convex from before backward; *nerve,* the chorda tympani.

Palatoglossus (Constrictor Isthmi Faucium). *Vide* Palatal Region.

PHARYNGEAL AND PALATAL REGION.

Constrictor Superior (*m. constrictor pharyngis superior*). —*Origin,* from margin of internal pterygoid plate and its hamular process; from pterygomaxillary ligament, part of the alveolar process of the lower jaw and side of the tongue, tendon of the tensor palati, and part of the palate bone; *insertion,* into the median *raphé* and the pharyngeal spine of the basilar process of the occipital bone; *action,* constricts the pharynx; *nerves,* pharyngeal plexus and glossopharyngeal.

Constrictor Medius (*m. constrictor pharyngis medius*). —*Origin,* from the stylohyoid ligament, greater and lesser cornua of the hyoid bone; *insertion,* into the median fibrous *raphé,*

blending with its fellow of opposite side; *action,* constricts the pharynx; *nerves,* pharyngeal plexus and glossopharyngeal.

Constrictor Inferior (*m. constrictor pharyngis inferior*).—*Origin,* from the sides of the thyroid and cricoid cartilages; *insertion,* into the fibrous *raphé* of the pharynx; *action,* contracts the pharyngeal canal; *nerves,* external laryngeal, glossopharyngeal plexus.

Stylopharyngeus (*m. stylopharyngeus*).—*Origin,* from base of the styloid process; *insertion,* into the constrictor muscles, palatopharyngeus, and posterior border of the thyroid cartilage; *nerves,* pharyngeal plexus and glossopharyngeal.

Levator Palati (*m. levator veli palatini*).—*Origin,* cartilaginous portion of Eustachian tube and apex of the petrous portion of the temporal bone; *insertion,* into the back part of the soft palate, blending with its fellow of the opposite side; *action,* elevates the soft palate; *nerve,* descending palatine from Meckel's ganglion, from the facial.

Tensor Palati, or Circumflexus (*m. tensor veli palatini*).—*Origin,* from spine of the sphenoid, vaginal portion of temporal bone, cartilage of Eustachian tube, and scaphoid fossa at base of internal pterygoid plate; *insertion,* into the palate bone and the soft palate; *action,* renders tense the palate; *nerve,* a branch from the otic ganglion.

Azygos Uvulæ (*m. uvulæ*).—*Origin,* from aponeurosis of soft palate and posterior nasal spine; *insertion,* into the uvula; *action,* raises the palate; *nerves,* descending palatine branches and Meckel's ganglion, from the facial.

Palatoglossus (*m. glossopalatinus*)—Constrictor Isthmi Faucium).—*Origin,* from soft palate on either side of the uvula; *insertion,* into the dorsum and side of the tongue, blending with the fibers of the styloglossus—this muscle forms the anterior pillar of the fauces; *action,* constricts the fauces; *nerves,* palatine branches of Meckel's ganglion.

Palatopharyngeus (*m. pharyngopalatinus*).—*Origin,* by two portions, from soft palate; *insertion,* into posterior border of thyroid cartilage and pharynx; this muscle forms the posterior pillar of the fauces; *action,* closes the posterior nares; *nerves,* palatine branches from Meckel's ganglion.

VERTEBRAL REGION.

Rectus Capitis Anticus Major.—*Origin,* by four tendons from transverse processes of the third, fourth, fifth and sixth cervical vertebræ; *insertion,* basilar process of occipital

bone; *action,* flexes the head; *nerves,* suboccipital and deep internal branches of cervical plexus.

Rectus Capitis Anticus Minor.—*Origin,* from root of transverse process and anterior part of the lateral mass of the atlas; *insertion,* basilar process of occipital, behind the former; *action,* flexes the head; *nerves,* suboccipital and deep branches of the cervical plexus.

Rectus Lateralis.—*Origin,* superior surface of the transverse process of the atlas; *insertion,* inferior surface of the jugular process of the occipital; *action,* draws the head laterally; *nerves,* suboccipital and deep internal branches of the cervical plexus.

Longus Colli.—*Origin,* from three portions, superior oblique portion from anterior tubercles of the transverse processes of the third, fourth and fifth cervical; *insertion,* tubercle on the anterior arch of atlas; inferior oblique portion, *origin,* from anterior surface of the bodies of the first two or three dorsal vertebræ; *insertion,* anterior tubercles of the transverse processes of the fifth and sixth cervical; vertical portion, *origin,* from the anterior surface of the bodies of the lower three cervical and upper three dorsal bodies of the second, third and fourth cervical vertebræ; *action,* rotates and flexes the cervical portion of the vertebræ; *nerves,* anterior branches of the lower cervical nerve.

Scalenus Anticus (*m. scalenus anterior*).—*Origin,* from the tubercle of the first rib; *insertion,* into the anterior tubercles of the transverse processes of the third, fourth, fifth and sixth cervical vertebræ; *action,* flexes and rotates the vertebral column; *nerves,* anterior branches of the lower cervical nerve.

Scalenus Medius.—*Origin,* upper surface of the first rib, behind the groove for the subclavian artery; *insertion,* into the transverse processes of the lower six cervical vertebræ; *action,* rotates and flexes the vertebral column; *nerves,* the anterior branches of the lower cervical nerve: the posterior thoracic, long thoracic nerve, or external respiratory nerve of Bell, has its origin in the substance of this muscle, by union of two roots from fifth and sixth cervical nerves.

Scalenus Posticus (*m. scalenus posterior*).—*Origin,* from the outer surface of the second rib, behind the serratus magnus; *insertion,* into the posterior tubercles of the transverse processes of the lower two or three cervical vertebræ; *action,* flexes and rotates the spine; *nerves,* anterior branches of the lower cervical nerves.

Of these muscles the scalenus medius is the longest and largest, and the scalenus posticus the smallest.

Muscles of the Larynx and Epiglottis (*vide* Larynx).

Muscles of the Trunk.

muscles of the back.

First Layer.

Trapezius.—*Origin,* from inner third of superior curved line of the occipital bone, the ligamentum nuchæ, the spinous processes of the seventh cervical, and all the dorsal vertebræ; *insertion,* into the outer third of the posterior border of the clavicle, the inner margin of the acromion process, and the crest of the spine of the scapula; *action,* with head fixed elevates point of shoulder, with shoulders fixed together draws head backward, or singly draws head to corresponding side; adducts, rotates inward and depresses humerus; *nerves,* cervical plexus and spinal accessory.

Ligamentum Nuchæ.—*Origin,* from external occipital protuberance; *insertion,* spinous processes of the cervical vertebræ, from the second to the seventh. This ligament is rudimental in man, and in the lower animals sustains the head.

Latissimus Dorsi.—*Origin,* by an aponeurosis from the spinous processes of the six lower dorsal, the lumbar and sacral vertebræ, the supraspinous ligament, the crest of the ilium, and the three or four lower ribs; *insertion,* into the inner lip of the bicipital groove of the humerus, in front of the teres major, and a little above the pectoralis major; the tendon of this muscle twists completely on itself, so that the superior fibers become the inferior; *action,* draws the arm backward and downward, or, fixing the arm, raises the lower ribs and draws the trunk forward; *nerve,* subscapular.

Second Layer.

Levator Anguli Scapulæ (*m. levator scapulæ*).—*Origin,* from three to five tendons from the posterior tubercles of the transverse processes of the three or five upper cervical vertebræ; *insertion,* into posterior border of the scapula, at the root of the spine; *action,* elevates the angle of the scapula; *nerve,* anterior division of the third and fourth cervical nerves.

Rhomboideus Minor.—*Origin,* from spinous processes of seventh cervical and first dorsal vertebræ and the ligamentum nuchæ; *insertion,* into root of the spine of the scapula; *action,*

draws the inferior angle upward and backward; *nerves*, branches from the fifth cervical nerve.

Rhomboideus Major.—*Origin*, from supraspinous ligament and spinous processes of four or five upper dorsal vertebræ; *insertion*, by a tendinous arch attached above near the

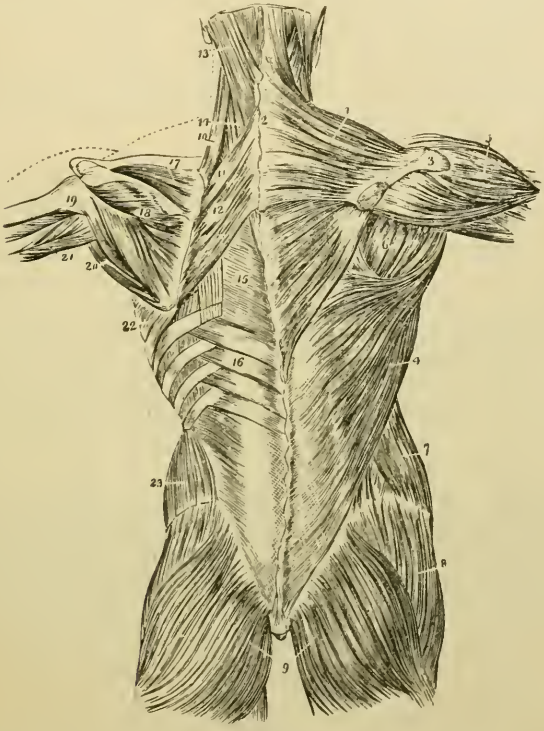

Fig. 67.

Muscles of the back: 1, trapezius; 2, 4, latissimus dorsi; 10, levator anguli scapulæ; 11, rhomboideus minor; 12, rhomboideus major; 13, 14, splenius capitis et colli; 15, vertebral aponeurosis; 16, serratus posticus inferior.

spine and below to the inferior angle of the scapula; *action*, draws the inferior angle upward and backward; *nerves*, branches of the fifth cervical.

Third Layer.

Serratus Posticus Superior (*m. serratus posterior superior*).—*Origin*, from spinous processes of the two or three upper

dorsal and last cervical vertebræ, and from the ligamentum nuchæ; *insertion,* into upper borders of the second to the fifth ribs inclusive; *action,* assists in respiration; *nerves,* external branches of the posterior division of the cervical.

Serratus Posticus Inferior (*m. serratus posterior inferior*).—*Origin,* from spinous processes and interspinous ligaments of two or three upper lumbar and two lower dorsal vertebræ; *insertion,* into lower borders of the four lower ribs, external to their angles; *action,* elevates the ribs; assists in respiration; *nerves,* external branches of the posterior divisions of the lower dorsal.

Splenius.—*Origin,* from spinous processes of last cervical and six upper dorsal vertebræ, the lower half of the ligamentum nuchæ, and the supraspinous ligament; *insertion,* by two heads—splenius capitis (*m. splenius capitis*) into the occipital bone, just below the superior curved line and the mastoid process of the temporal bone; splenius colli (*m. splenius cervicis*) into posterior tubercles of the transverse processes of the three or four upper cervical vertebræ; *action,* separately, rotates the head and draws it to the other side; together, draw the head backward; nerves, external branches of the posterior divisions of the cervical.

Fourth Layer.

Erector Spinæ (*m. sacrospinalis*).—*Origin,* from sacro-iliac groove and from a broad tendon attached internally to the spinous processes of the lumbar and two or three lower dorsal vertebræ and supraspinous ligament; externally, the crest of the ilium and the posterior part of the sacrum; *insertion,* by two parts—(1) sacrolumbalis or iliocostalis (*m. iliocostalis lumborum*), inserted into the angles of the six or seven lower ribs; this muscle has two accessory portions (*a*) musculus accessorius ad iliocostalem (*m. iliocostalis dorsi*): *origin,* from angle of six lower ribs; *insertion,* angles of six upper ribs; (*b*) cervicalis ascendens: *origin,* angles of the four or five upper ribs; *insertion,* into the posterior tubercles of the fourth to the sixth cervical vertebræ, inclusive; (2) longissimus dorsi; *insertion,* into the transverse processes of all the dorsal vertebræ, and from the seventh to the eleventh ribs, inclusive, between their angles and tubercles; *action,* bends the trunk backward and erects the spine; *nerves,* external branches of the posterior divisions of the lumbar and dorsal.

Transversalis Colli, or cervicis (*m. longissimus cervicis*).—*Origin,* transverse processes of six upper dorsal vertebræ;

insertion, into the posterior tubercles of the transverse processes of the second to the sixth cervical vertebræ inclusive; *nerves,* external branches of the posterior divisions of the cervical.

Trachelomastoid (*m. longissimus capitis*).—*Origin,* from articular processes of three or four lower cervical, and from the transverse processes of the third to the sixth dorsal vertebræ; *insertion,* into the posterior margin of the mastoid process, below the sternomastoid and the splenius; *action,* steadies the head; *nerves,* external branches of the posterior divisions of the cervical.

Spinalis Dorsi.—*Origin,* spinous processes of last two dorsal and first two lumbar vertebræ; *insertion,* into spinous processes of the dorsal vertebræ, blending with the semispinalis dorsi; *action,* erects the spinal column; *nerves,* external branches of the posterior divisions of the cervical.

Spinalis Cervicis, or spinalis colli (*m. spinalis cervicis*). —*Origin,* from the spinous processes of the fifth to the seventh cervical vertebræ; *insertion,* into the spinous process of the axis; *action,* steadies the neck; *nerves,* same as above; this muscle is absent in 20 per cent. of the subjects.

Complexus or Semispinalis Capitis (*m. semispinalis capitis*).—*Origin,* by seven tendons from transverse processes of the upper three dorsal and seventh cervical and articular processes of the fourth, fifth and sixth cervical; *insertion,* into the occipital bone, between the curved lines; *action,* separately, rotates and draws the head to one side; together, draw the head directly backward; *nerves,* suboccipital, great occipital, and internal branches of the posterior divisions of the cervical.

Fifth Layer.

Semispinales Dorsi.—*Origin,* from transverse processes from the fifth to eleventh dorsal vertebræ; *insertion,* into the spinous processes of the lower two cervical and upper four dorsal vertebræ; *action,* erects the spinal column; *nerves,* internal branches of the posterior divisions of the cervical.

Semispinalis Cervicis, or Colli (*m. semispinalis cervicis*).—*Origin,* from transverse processes of lower four cervical and upper four dorsal vertebræ; *insertion,* into spinous processes of the second to the fifth cervical vertebræ; *action,* erects the spinal column; *nerves,* same as above.

Multifidus Spinæ (*m. multifidus*).—*Origin,* from the transverse processes in the dorsal region, the articular processes

in the cervical and lumbar region, the posterior superior spine of the ilium, posterior sacroiliac ligaments, and from the aponeurotic arch of the erector spinæ; *insertion,* each fasciculus is attached to the laminæ and spinous process of the vertebræ above; *action,* preserves the erect condition of the spine; *nerves,* internal branches of the posterior divisions of the cervical, dorsal, lumbar and sacral nerves.

Rotatores Spinæ (*mm. rotatores*).—Eleven on either side. *Origin,* from upper part of transverse process; *insertion,* into outer surface and lower border of the laminæ of the vertebræ above, from the first and second dorsal to the eleventh and twelfth; *action,* rotates the spinal column; *nerves,* anterior branches of the posterior divisions of the dorsal.

Supraspinales.—*Origin* and *insertion,* the spinous processes in the cervical region of the vertebræ; *action,* extends cervical spine; *nerves,* internal branches of the posterior divisions of the cervical.

Interspinales.—Consist of muscular bands in pairs between the spinous processes of the adjoining vertebræ: six pairs in the cervical region, three pairs in the dorsal, four or five in the lumbar; *action,* extend the spine; *nerves,* internal branches of the posterior divisions of the cervical dorsal and lumbar.

Extensor Coccygis.—*Origin,* from the first piece of the coccyx, or last bone of the sacrum; *insertion,* into the lower extremity of the coccyx; *action,* rudimental in man.

Intertransversales (*mm. intertransversarii*).—Are small, muscular bands between the transverse processes: in the cervical region seven pairs, in the dorsal twelve pairs, in the lumbar region four pairs; *action,* flex the spine laterally; *nerves,* internal branches of the posterior division of the cervical, dorsal and lumbar.

Rectus Capitis Posticus Major (*m. rectus capitis posterior major*).—*Origin,* from the spinous process of the axis; *insertion,* into inferior curved line of the occipital bone; *action,* rotates the atlas and the cranium; *nerve,* the suboccipital.

Rectus Capitis Posticus Minor (*m. rectus capitis posterior minor*).—*Origin,* from the tubercle of the posterior arch of the atlas; *insertion,* below the inferior curved line of the occipital bone; *action,* draws the head backward; *nerve,* suboccipital.

Obliquus Capitis Inferior.—*Origin,* spinous process of the axis; *insertion,* lower back portion of the transverse process of the atlas; *action,* rotates the atlas and the cranium; *nerves,* suboccipital and great occipital.

Obliquus Capitis Superior.—From upper surface of the transverse process of the atlas; *insertion,* between the curved lines of the occipital bone to the outer side of the complexus; *action,* rotates the atlas; *nerves,* suboccipital and great occipital.

MUSCLES OF THE ABDOMINOTHORACIC REGION.

Obliquus Externus (*m. obliquus externus abdominis*).—*Origin,* lower borders of the eight lower ribs; *insertion,* the lowermost muscular fibers, into the anterior half of the iliac crest; the other muscular fibers, by a broad aponeurosis, which joins the anterior half of the aponeurosis of the internal oblique to form the anterior walls of the sheath of the rectus, above into the ensiform cartilage, below into the symphysis pubis. In the median line it blends with its fellow of the opposite side to form the linea alba. A slit in its lower portion above the pubic spine is called the external abdominal ring. The lower, thickened portion of the aponeurosis stretching between the anterior superior iliac spine and the pubic spine is called Poupart's ligament, or the ligament of Fallopius. A reflection from it to the iliopectineal line is called Gimbernat's ligament; *action,* flexes the pelvis on the thorax, or *vice versâ*, and compresses the viscera; *nerves,* lower intercostal, iliohypogastric and ilioinguinal.

Obliquus Internus, or internal or ascending oblique (*m. obliquus internus abdominis*).—*Origin,* from the outer half of Poupart's ligament, from the anterior two-thirds of the crest of the ilium, and the posterior lamellæ of the lumbar fascia; *insertion,* above to the lower four costal cartilages, below, conjointly with the tendon of the transversalis, into the os pubis and linea iliopectinea, to form the *conjoined tendon* [the outer portion of this tendon being termed the ligament of Hesselbach (*ligamentum interfoveolare;* the inner part, the ligament of Henle], and into the median line (linea alba) by an aponeurosis extending from the sternum and seventh and eighth costal cartilages to the pubis. This aponeurosis at its lower fourth consists of two united laminæ passing in front of the rectus muscle, but in its upper three-fourths it divides, one lamina passing in front of the rectus and joining the aponeurosis of the external oblique, the other passing behind and joining the aponeurosis of the transversalis; *action,* same as the externus; *nerves,* same as externus.

Transversalis (*m. transversus abdominis*).—*Origin,* from outer third of Poupart's ligament and anterior three-fourths of

the crest of the ilium, from the inner surface of the cartilages of the six lower ribs, and from the spinous and transverse processes of the lumbar vertebræ; *insertion,* by the conjoined tendon into the linea iliopectinea and crest of the os pubis; *action* and *nerves,* same as the externus.

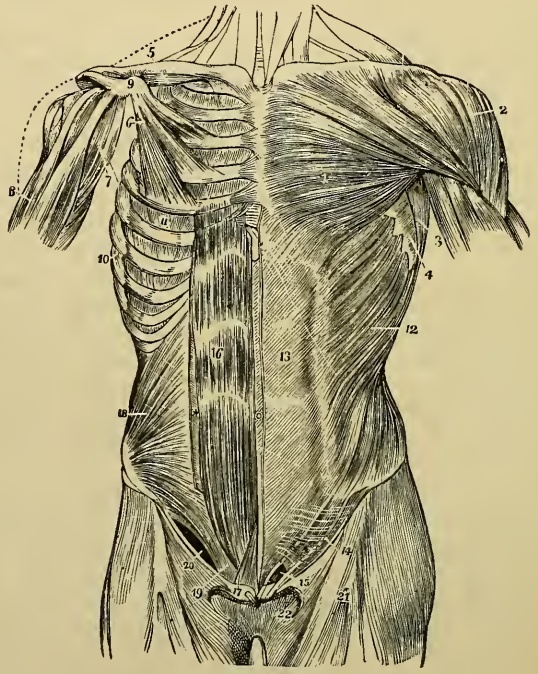

FIG. 68.

Muscles of abdomen: 12, external oblique; 16, rectus abdominis; 18, internal oblique; 17, pyramidalis; 19, quadratus lumborum.

RECTUS ABDOMINIS.—*Origin,* by two tendons—the outer from the crest of the pubis, the inner interlacing with its fellow of the opposite side; *insertion,* into the cartilages of the fifth, sixth and seventh ribs; *action,* depresses the thorax, flexes the vertebral column, and, acting from above, flexes the pelvis upon the vertebral column.

PYRAMIDALIS.—*Origin,* from the os pubis and anterior pubic ligament; *insertion,* into the linea alba, midway between the os pubis and umbilicus.

QUADRATUS LUMBORUM.—*Origin,* by two portions—posterior portion, from crest of the ilium and iliolumbar ligament; *insertion,* into lower border of the last rib and transverse processes of the three lower lumbar vertebræ; *origin,* anterior portion, from upper border of the transverse processes of the lumbar vertebræ, from the third to the fifth; *insertion,* into one-half the lower margin of the last rib and apices of upper four lumbar vertebræ; *action,* draws down and fixes the last rib and assists in inspiration and expiration.

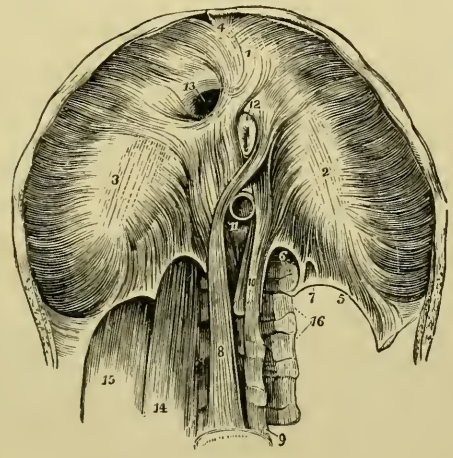

FIG. 69.

Diaphragm: 1, 2, 3, central cordiform tendon; 4, middle leaflet; 5, ligamentum arcuatum externum; 6, ligamentum arcuatum internum; 8, right crus; 10, left crus; 11, aortic opening; 12, esophageal opening; 13, opening for vena cava; 14, psoas magnus; 15, quadratus lumborum.

MUSCLES OF THE THORAX.

INTERCOSTALES EXTERNI (*mm. intercostales externi*).—Eleven pairs on either side. *Origin,* from the outer border of the groove on the lower border of each rib, from the cartilage to the tubercle; *insertion,* into upper border of the rib below; *action,* raises the ribs; *nerve,* intercostal.

INTERCOSTALES INTERNI (*mm. intercostales interni*).—*Origin,* inner lip of the groove on the lower border of each rib; *insertion,* into the upper border of the rib below; *action,* pulls the ribs upward; *nerve,* intercostal.

Infracostales—Subcostales (*mm. subcostales*).—*Origin,* inner surface of rib; *insertion,* into the inner surface, from the first to the third rib below; *action,* inspiratory muscles; *nerve,* intercostal.

Triangularis Sterni (*m. transversus thoracis*).—*Origin,* lower part of the back of the sternum and back of ensiform cartilage and inner surface of sternal end of the costal cartilages of the three or four lower ribs; *insertion,* into the border and inner surfaces of the costal cartilages, from the second to the sixth rib inclusive (it is continuous below with transversalis abdominis muscle); *action,* draws down the costal cartilages; *nerve,* intercostal.

Levatores Costarum.—Twelve on either side. *Origin,* from transverse processes of seventh cervical and eleven upper dorsal vertebræ; *insertion,* into upper surface of the rib below, between the angle and tubercle; *action,* raises the ribs; *nerve,* the intercostal.

DIAPHRAGMATIC REGION.

Diaphragm (*diaphragma*).—*Origin,* inner surface of ensiform cartilage, cartilages and bony portions of six or seven lower ribs in front, and from two aponeurotic arches, the ligamentum arcuatum externum (*arcus lumbocostalis lateralis*) and internum (*arcus lumbocostalis medialis*), and the lumbar vertebræ behind (*pars lumbalis*); *insertion,* into the circumference of the central or cordiform tendon (*centrum tendineum*); *action,* the principal muscle of inspiration and expulsion; *nerves,* the phrenic, and phrenic plexus of the sympathetic.

THE OPENINGS IN THE DIAPHRAGM.

The *aortic opening* is placed posteriorly between the two crura, in front of the spine. It transmits the aorta, thoracic duct, and vena azygos major, and sometimes the left sympathetic nerve.

The *esophageal opening* is in front of the decussation of the crura, a little to the left and in front of the aortic opening (*hiatus aorticus*). It transmits the esophagus and pneumogastric nerves.

The foramen quadratum, or opening (*foramen venæ cavæ*) for the *vena cava,* is placed at the highest part of the central tendon, a little to the right. It transmits the vena cava and maintains its patency. The crus on each side transmits the sympathetic and greater and lesser splanchnic nerves, and in addition the *left* transmits the vena azygos minor.

Muscles of the Perineum (*vide* Perineum).

Muscles of the Upper Extremity.

MUSCLES OF THE SHOULDER.

Pectoralis Major.—*Origin,* from the sternal half of the clavicle (clavicular portion) and anterior surface of the sternum and costal cartilages from the second to the sixth or seventh rib (sternocostal portion); *insertion,* into the anterior bicipital ridge of the humerus; *action,* draws the arm across the chest; *nerves,* external and internal anterior thoracic.

Pectoralis Minor.—*Origin,* upper and outer surface of the third to the fifth rib, inclusive, and the aponeurosis of the intercostal muscles; *insertion,* into anterior border of the coracoid process of the scapula; *action,* draws the scapula inward and downward; *nerve,* the anterior thoracic.

Subclavius.—*Origin,* from cartilage of the first rib; *insertion,* under surface of the clavicle, about its middle third; *action,* depresses the shoulder, and draws clavicle forward and downward; *nerve,* branch from the union of the fifth and sixth cervical.

Serratus Magnus (*m. serratus anterior*).—*Origin,* by nine muscular portions, from the outer surface of the eight upper ribs (two divisions being from the second rib) and from the upper intercostal aponeurosis; *insertion,* by three divisions—upper portion into superior angle of the scapula, middle portion into posterior portion of the scapula between the inferior and superior angles, lower portion into the inferior angle of the scapula; *action,* raises the vertebral border and carries the scapula forward; *nerve,* the posterior thoracic.

Deltoid (*m. deltoideus*).—*Origin,* from the outer third of the clavicle and from the outer part of the acromion process and the lower border of the scapular spine; *insertion,* into the outer side of the shaft of the humerus, about its middle into the deltoid tubercle; *action,* raises the arm; *nerve,* the circumflex.

Subscapularis.—*Origin,* from the internal two-thirds of the subscapular fossa; *insertion,* into the lesser tuberosity of the humerus; *action,* rotates the head of the humerus inward; *nerves,* upper and lower subscapular.

Supraspinatus.—*Origin,* from inner two-thirds of supraspinous fossa; *insertion,* into the uppermost facet of the great tuberosity of the humerus; *action,* assists in raising the arm and fixing the head of the humerus; *nerve,* the suprascapular.

INFRASPINATUS.—*Origin,* from the inner two-thirds of the infraspinous fossa; *insertion,* into the middle facet of the great tuberosity; *action,* rotates the head of the humerus outward; *nerve,* suprascapular.

TERES MINOR.—*Origin,* posterior surface of the upper two-thirds of the axillary border of the scapula; *insertion,* into the lowest facet of the great tuberosity; *action,* rotates the head of the humerus outward; *nerve,* the circumflex.

TERES MAJOR.—*Origin,* posterior surface of the inferior angle of the scapula; *insertion,* into the posterior bicipital ridge of the humerus; *action,* draws the humerus backward and downward, assisting the latissimus dorsi; *nerve,* the lower subscapular.

HUMERAL REGION.

CORACOBRACHIALIS.—*Origin,* from apex of the coracoid process of the scapula; *insertion,* into the inner side of the middle of the shaft of the humerus, between the origin of the brachialis anticus and short humeral head of the triceps; *action,* draws the humerus inward and forward; *nerves,* the musculocutaneous and a branch of the musculospiral.

BICEPS—FLEXOR CUBITI (*m. biceps brachii*).—*Origin,* by two heads; short head from the apex of the coracoid process, along with the coracobrachialis; the long (glenoid) head (*caput longum*) from the upper margin of the glenoid cavity of the scapula; *insertion,* into the posterior part of the tuberosity of the radius; *action,* flexes the forearm; *nerve,* the musculocutaneous.

BRACHIALIS ANTICUS (*m. brachialis*).—*Origin,* inner and outer surfaces of the shaft of the humerus, embracing the insertion of the deltoid; *insertion,* into the anterior surface of the coronoid process of the ulna; *action,* flexes the forearm; *nerve,* the musculocutaneous.

TRICEPS—EXTENSOR CUBITI (*m. triceps brachii*).—*Origin,* by three heads—middle, or scapular head (*caput longum*), below the glenoid cavity of the scapula; external head (*caput laterale*), from the posterior aspect of the shaft of the humerus, between the upper part of the musculospiral groove and the insertion of the teres minor, and from the external intermuscular septum; the internal head (*caput mediale*), from the posterior aspect of the shaft of the humerus, below the insertion of the teres major, and below the groove for the musculospiral nerve; *insertion,* by a common head, into the posterior part of the under surface of

the olecranon process of the ulna; *action,* extends the forearm; *nerve,* the musculospiral.

Subanconeus (*m. anconæus*).—*Origin,* from the posterior surface of the humerus, above the olecranon fossa; *insertion,* into the posterior ligament of the elbow-joint; *action,* draws up the posterior ligament of the elbow-joint during extension of the forearm; *nerve,* the musculospiral.

Fig. 70.

Muscles of shoulder and arm; 4, subscapularis; 5, teres major; 6, coracobrachialis; 7, biceps.

Fig. 71.

Triceps muscle: 1, external head; 2, scapular head; 3, internal head; 4, insertion.

MUSCLES OF THE FOREARM.

Anterior Superficial Layer.

Pronator Radii Teres (*m. pronator teres*).—*Origin,* by two heads—the smaller from the coronoid process of the ulna, the ulnar head (*caput ulnare*), the larger from the humerus, above the internal condyle, the humeral head (*caput humerale*), and from the common tendon of this group of muscles, and intermuscular septum; *insertion,* into the outer aspect of the

shaft of the radius; *action,* pronates the hand; *nerve,* the median.

Flexor Carpi Radialis.—*Origin,* by the common tendon from the inner condyle, and from the intermuscular septum between it and the pronator teres; *insertion,* into the base of the metacarpal bone of the index finger; *action,* flexes the wrist; *nerve,* the median.

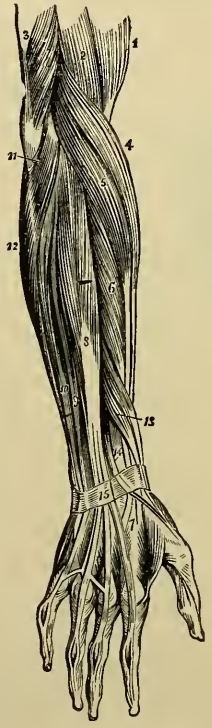

Fig. 72.

Muscles of forearm: 1, biceps; 2, brachialis anticus; 3, triceps; 4, supinator longus; 5, extensor carpi radialis longior; 6, extensor carpi radialis brevior; 8, extensor communis digitorum; 12, extensor carpi ulnaris; 13, 14, extensors of thumb.

Palmaris Longus.—*Origin,* from the inner condyle of the humerus by the common tendon and the intermuscular septum and the deep fascia; *insertion,* into the annular ligament, spreading out in the palmar fascia; *action,* renders tense the palmar fascia; *nerve,* the median.

Flexor Carpi Ulnaris.—*Origin,* by two heads—one by the common tendon from the inner condyle of the humerus, the other from the inner margin of the olecranon, the intermuscular septum, between the ulna and the flexor sublimis digitorum, and from the upper two-thirds of the posterior aspect of the ulna; *insertion,* pisiform bone; *action,* flexes the wrist; *nerve,* the ulnar.

Flexor Sublimis Digitorum—Perforatus (*m. flexor digitorum sublimis*).—*Origin,* by three heads—one from the coronoid process of the ulna, the ulnar head (*caput ulnare*), above the pronator radii teres, another from the common tendon from the internal condyle of the humerus, the humeral head (*caput humerale*), and the third, the radial head (*caput radiale*) from the oblique line of the radius, from the insertion of the pronator radii teres, to the tubercle; each tendon divides at the base of the first phalanges (*chiasma tendinum*) to allow the passage of the tendon of the flexor profundus digitorum; *insertion,* into the lateral margins of the second phalanges by four tendons; *action,* flexes the second phalanges; *nerve,* median.

Anterior Deep Layer.

Flexor Profundus Digitorum—Perforans (*m. flexor digitorum profundus*).—*Origin,* from the inner side of the coronoid process, and from the upper two-thirds of the front and inner aspect of the shaft of the ulna, between the brachialis anticus above and the pronator quadratus below; *insertion,* by four tendons into the bases of the last phalanges, perforating the tendons of the flexor sublimis; *action,* flexes the phalanges; *nerves,* the anterior interosseous and the ulnar.

Flexor Longus Pollicis (*m. flexor pollicis longus*).—*Origin,* from the upper two-thirds of the shaft of the radius and from the interosseous membrane; *insertion,* into the base of the last phalanx of the thumb; *action,* flexes the phalanges; *nerve,* the anterior interosseous.

Pronator Quadratus.—*Origin,* anterior border of the ulna and from the oblique line of the lower fourth of the anterior aspect of the ulna; *insertion,* into the lower fourth of the front and outer border of the shaft of the radius; *action,* pronates the hand; *nerve,* anterior interosseous.

Radial Region.

Supinator Longus (*m. brachioradialis*).—*Origin,* from the upper two-thirds of the external condyloid ridge of the

humerus and the external intermuscular septum; *insertion,* into the base of the styloid process of the radius; *action,* supinates the hand; *nerve,* musculospiral.

Extensor Carpi Radialis Longior (*m. extensor carpi radialis longus*).—*Origin,* from the lower third of the external condyloid ridge of the humerus, from the common tendon of the extensor muscles of the forearm from the external condyle, and the intermuscular septum; *insertion,* into the radial side of the base of the metacarpal bone of the index finger; *action,* extends the wrist; *nerve,* musculospiral.

Extensor Carpi Radialis Brevior (*m. extensor carpi radialis brevis*).—*Origin,* from the common tendon from the external condyle of the humerus, the external lateral ligament, and the intermuscular septum; *insertion,* into the base of the metacarpal bone of the middle finger on its radial side; *action,* extends the wrist; *nerve,* posterior interosseous.

Posterior Superficial Layer.

Extensor Communis Digitorum (*m. extensor communis digitorum*).—*Origin,* from the external condyle of the humerus, the deep fascia, and the intermuscular septa; *insertion,* by four tendons into the second and third phalanges of all the fingers (at the first phalanx they receive the insertion of the lumbricales and interossei); *action,* extends the fingers; *nerve,* posterior interosseous.

Extensor Minimi Digiti (*m. extensor digiti quinti proprius*).—*Origin,* from the common tendon from the external condyle and the intermuscular septum; *insertion,* into the second and third phalanges of the little finger; *action,* extends the little finger; *nerve,* posterior interosseous.

Extensor Carpi Ulnaris.—*Origin,* from the middle third of the posterior border of the ulna, from the common tendon from the external condyle of the humerus, and from the fascia of the forearm; *insertion,* into the base of the metacarpal bone of the little finger, on the ulnar side; *action,* extends the wrist; *nerve,* posterior interosseous.

Anconeus (*m. anconæus*).—*Origin,* from the outer condyle of the humerus; *insertion,* into the upper fourth of the posterior aspect of the shaft of the ulna and the side of the olecranon; *action,* extends the forearm; *nerve,* musculospiral.

Posterior Deep Layer.

Supinator Radii Brevis (*m. supinator*).—*Origin,* from the external lateral ligament of the elbow-joint, from the external condyle of the humerus, from the ulna below the lesser sigmoid cavity, and from the orbicular ligament of the radius; *insertion,* into the neck, bicipital tuberosity and oblique line of radius; the posterior interosseous nerve pierces this muscle; *action,* supinates the hand; *nerve,* posterior interosseous.

Extensor Ossis Metacarpi Pollicis (*m. abductor pollicis longus*).—*Origin,* middle third of posterior surface of radius, posterior surface of lower three-fourths of shaft or ulna, and interosseous ligament; *insertion,* into base of metacarpal of thumb; *action,* extends metacarpal of thumb; *nerve,* posterior interosseous.

Extensor Longus Pollicis (*m. extensor pollicis longus*).—*Origin,* from the interosseous membrane and from the posterior aspect of the shaft of the ulna; *insertion,* into the base of the last or terminal phalanx of the thumb; *action,* extends the thumb; *nerve,* posterior interosseous.

Extensor Brevis Pollicis (*m. extensor pollicis brevis*).—*Origin,* from the posterior aspect of the shaft of the radius and from the interosseous membrane; *insertion,* into the base of the first phalanx of the thumb; *action,* extends the thumb; *nerve,* posterior interosseous.

Extensor Indicis (*m. extensor indicis proprius*).—*Origin,* from the posterior aspect of the ulna and from the interosseous membrane; *insertion,* into the second and third phalanges of the index finger, along with the tendon of the extensor communis; *action,* extends the index finger; *nerve,* posterior interosseous.

MUSCLES OF THE HAND.

These are divided into three groups—the radial region, the ulnar region, and the palmar region.

Radial Region.

Abductor Pollicis (*m. abductor pollicis brevis*).—*Origin,* from the annular ligament and ridge of the trapezium; *insertion,* into base of the first phalanx of the thumb on its radial side; *action,* abducts the thumb from the median line; *nerve,* median.

Opponens Pollicis.—*Origin,* from annular ligament and palmar surface of the trapezium; *insertion,* into metacarpal bone

of the thumb throughout the whole length of its radial side; *action,* flexes the first metacarpal bone; *nerve,* median.

Flexor Brevis Pollicis (*m. flexor pollicis brevis*).—This muscle consists of two portions, divided by tendon of flexor longus pollicis; *origin,* superficial portion from outer two-thirds of annular ligament and trapezium, deeper portion (by some called adductor obliquus pollicis) from sheath of flexor carpi radialis, the trapezoid, os magnum, and base of first, second, and third metacarpal bones; *insertion,* into either side of base of first phalanx of thumb, the inner portion joining the adductor and the outer portion the abductor; each tendon has a sesamoid bone developed in it; *action,* adducts thumb toward median line; *nerves,* ulnar and median.

Adductor Pollicis (Adductor Transversus Pollicis).—*Origin,* from lower two-thirds palmar surface of middle metacarpal bone; *insertion,* into ulnar side of base of first thumb phalanx and internal sesamoid bone; *action,* adducts thumb; *nerve,* ulnar.

Ulnar Region.

Palmaris Brevis.—*Origin,* from palmar fascia and annular ligament; *insertion,* into skin of palm of hand; *action,* wrinkles skin of hand; *nerve,* ulnar.

Abductor Minimi Digiti (*m. abductor digiti quinti*).—*Origin,* from pisiform bone and from tendon of flexor carpi ulnaris; *insertion,* into base of first phalanx of little finger on its ulnar side; *action,* abducts little finger from median line; *nerve,* ulnar.

Flexor Brevis Minimi Digiti (*m. flexor digiti quinti brevis*).—*Origin,* from annular ligament and tip of unciform process of unciform bone; *insertion,* into the first phalanx of little finger; *action,* flexes little finger; *nerve,* ulnar.

Opponens Minimi Digiti (*m. opponens digiti quinti*).—*Origin,* from annular ligament and from unciform process of unciform bone; *insertion,* into ulnar border of whole length of metacarpal bone of little finger; *action,* flexes little finger; *nerve,* ulnar.

Palmar Region.

Lumbricales.—*Origin,* by four fleshy tendons from the tendons of the deep flexors—the first and second from the palmar surface and radial side of the tendons of the index and middle fingers, the third from the adjoining sides of the tendons of the middle and ring fingers, and the fourth from the

adjoining sides of the tendons of the ring and little fingers; *insertion,* on dorsal aspect of each finger into the expansion of the extensor communis digitorum; *action,* abduct the fingers to either side of the median line; *nerves,* ulnar and median.

Interossei muscles consist of two groups, the dorsal and palmar.

Dorsal Interossei (*mm. interossei dorsales*).—*Origin,* from two heads from the adjacent sides of the metacarpal bones, four in number; *insertion,* the first into the radial side of the base of the first phalanx of the index finger, the second into the radial side of the middle finger, the third into the ulnar side of the middle finger, and the fourth into the ulnar side of the ring finger, the middle finger having two, one on either side; *action,* abduct the fingers from the median line; *nerve,* ulnar.

Palmar Interossei (*mm. interossei volares*).—Three in number. *Origin,* the first from the entire length of the metacarpal bone of the index finger on its ulnar side, the second from the ring finger on its radial side, and the third from the little finger on its radial side; *insertion,* into the base of the first phalanx and into the expansion of the extensor communis tendon of the same finger from which they arise; *action,* adduct the fingers toward the median line; *nerve,* ulnar.

Muscles of the Lower Extremity.

Iliac Region.

Psoas Magnus (*m. psoas major*).—*Origin,* from the sides and anterior surfaces of the transverse processes and bodies of the last dorsal and all the lumbar vertebræ and the intervertebral substances between them; *insertion,* into the lesser trochanter of the femur, uniting with the tendon of the iliacus; this muscle is in relation behind with the capsular ligament of the hip, being separated from it by a synovial bursa; *action,* flexes and rotates the femur inward, and also flexes the trunk and pelvis on the thigh; *nerves,* anterior branches of the lumbar nerves.

Psoas Parvus (*m. psoas minor*).—*Origin,* from the lateral surfaces of the bodies of the last dorsal and first lumbar vertebræ and from the intervertebral substances between them; *insertion,* into the iliopectineal eminence, joining the iliac fascia; *action,* assists the psoas magnus and renders tense the iliac fascia; *nerves,* anterior branches of the lumbar.

Iliacus.—*Origin,* from the base of the sacrum and the iliolumbar ligament behind, from the iliac fossa and inner margin

of the crest of the ilium and the anterior superior and anterior inferior spinous processes of the ilium; *insertion,* into the oblique or intertrochanteric line of the femur to the outer side of the insertion of the psoas; *action,* flexes and rotates the femur inward and flexes the trunk and pelvis on the thigh; *nerves,* anterior crural and the anterior branches of the lumbar.

FEMORAL AND GLUTEAL REGION.

Tensor Vaginæ Femoris, or tensor fasciæ femoris (*m. tensor vaginæ femoris,* or *m. tensor fasciæ femoris*).—*Origin,* from the anterior superior spinous process between the sartorius and the gluteus medius, and from the fore part of the outer lip of the crest of the ilium; *insertion,* into the fascia lata, about the upper fourth of the outer side of the thigh; *action,* renders tense the fascia lata; *nerve,* superior gluteal.

Sartorius.—Origin, from the anterior superior spinous process of the ilium and the upper part of the notch below; *insertion,* into the inner and upper part of the shaft of the tibia; *action,* flexes the leg upon the thigh and the thigh upon the pelvis; *nerve,* branches of the anterior crural.

Quadriceps Extensor (*m. quadriceps femoris*).—This extensive muscle covers the front and sides of the femur and consists of four portions—the rectus femoris, the vastus externus, the vastus internus and the crureus.

Rectus Femoris.—*Origin,* by two heads—one, the long head, from the groove above the brim of the acetabulum; the other, the short head, from the anterior inferior spinous process of the ilium; *insertion,* by the common tendon into the patella; *action,* extends the leg upon the thigh; *nerves,* branches of the anterior crural.

Vastus Externus (*m. vastus lateralis*).—Forms the greater part of the quadriceps extensor. *Origin,* by an extensive aponeurosis extending from the tubercle of the femur along the anterior border of the great trochanter and the whole length of the outer lip of the linea aspera; *insertion,* into the outer portion of the patella, joining the common tendon; *action,* extends the leg on the thigh; *nerves,* branches of the anterior crural.

Vastus Internus and Crureus (*m. vastus medialis et m. vastus intermedius*).—*Origin,* by a tendinous aponeurosis extending from the neck of the femur throughout the whole length of the inner lip of the linea aspera; *insertion,* into the common tendon, together with the rectus femoris and the vastus exter-

nus; *action,* extends the leg on the thigh; *nerves,* branches of the anterior crural.

Subcrureus (*m. articularis genu*).—*Origin,* from the anterior aspect of the lower part of the shaft of the femur; *insertion,* into the synovial sac behind the patella.

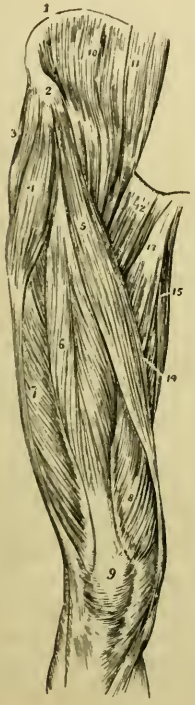

Fig. 73.

Anterior femoral region; 4, tensor vaginæ femoris; 5, sartorius; 6, rectus; 7, vastus externus; 8, vastus internus; 10, iliacus; 11, psoas; 12, pectineus; 13, adductor longus; 14, adductor magnus; 15, gracilis.

Fig. 74.

Posterior femoral region; 1, gluteus medius; 2, gluteus maximus; 3, vastus externus; 4, biceps; 6, semitendinosus; 7, semimembranosus; 8, gracilis.

Gracilis.—*Origin,* from the inner margin of the ramus of the ischium and the pubes; *insertion,* into the inner aspect of the shaft of the tibia, below the tuberosity; *action,* flexes the

leg and draws it inward, assisting the sartorius; *nerve,* the obturator.

Pectineus.—*Origin,* from the tendinous prolongation of Gimbernat's ligament and the linea iliopectinea; *insertion,* into the rough line leading to the linea aspera from the lesser trochanter; *action,* adducts the thigh; *nerves,* obturator, the accessory obturator, and branches of the anterior crural.

Adductor Longus.—*Origin,* from the front of the os pubis below the crest; *insertion,* into the middle third of the linea aspera, between the adductor magnus and the vastus internus; *action,* adducts the thigh; *nerve,* obturator.

Adductor Brevis.—*Origin,* from the outer aspect of the descending ramus of the pubes, between obturator externus and the gracilis; *insertion,* into the upper part of the linea aspera; *action,* adducts the thigh; *nerves,* branches of the obturator.

Adductor Magnus.—*Origin,* from the tuberosity of the ischium, the ascending ramus of the ischium, and from the descending ramus of the pubes; *insertion,* into the rough line leading to the linea aspera from the great trochanter to the inner side of the gluteus maximus and into the adductor tubercle above the inner condyle of the femur (*vide* page 64); *action,* adducts the thigh; *nerves,* the obturator and a branch from the great sciatic.

Gluteus Maximus (*m. glutæus maximus*).—*Origin,* from the superior curved line of the ilium, the posterior aspect of the last segment of the sacrum, the border of the coccyx, and the surface of the great sacrosciatic and posterior sacroiliac ligaments; *insertion,* into the rough line leading to the linea aspera from the great trochanter, between the adductor magnus and the vastus externus, and into the fascia lata; *action,* it is a tensor of the fascia lata, and an external rotator and extensor of the thigh; *nerves,* the inferior gluteal and a branch from the sacral plexus.

Gluteus Medius (*m. glutæus medius*).—*Origin,* from the outer lip of the crest and the outer aspect of the ilium, between the middle and superior curved lines, and from the gluteal aponeurosis; *insertion,* into the oblique line on the outer surface of the great trochanter; *action,* rotates the thigh outward; *nerve,* from the superior gluteal.

Gluteus Minimus (*m. glutæus minimus*).—*Origin,* from the border of the great sacrosciatic notch and between the inferior and middle curved lines of the outer aspect of the ilium; *insertion,* into a depression on the front border of the great

trochanter; *action,* rotates the thigh inward; *nerve,* superior gluteal.

Pyriformis (*m. piriformis*).—*Origin,* from the anterior surface of the sacrum, between the first to the fourth anterior sacral foramen, and from the margin of the great sacrosciatic foramen, and from the anterior aspect of the great sacrosciatic ligament; *insertion,* into the upper border of the great trochanter, with the tendon of the obturator internus; *action,* rotates femur outward; *nerve,* obturator.

Obturator Internus.—*Origin,* from the inner side of the obturator foramen and the internal surface of obturator membrane and the anterior and external wall of the pelvis; it passes out of the pelvis through the lesser sacrosciatic notch and receives the tendons of the gemelli muscles; *insertion,* into the upper border of the great trochanter in front of the pyriformis; *action,* rotates the thigh outward; *nerves,* branches from the sacral plexus.

Gemelli consist of two muscles—gemellus superior and gemellus inferior.

Gemellus Superior.—*Origin,* from the outer aspect of the spine of the ischium; *insertion,* into the tendon of the obturator internus.

Gemellus Inferior.—*Origin,* from the outer border of tuberosity of the ischium; *insertion,* into the lower portion of the tendon of the obturator internus; *action,* rotates the thigh outward; *nerves,* branches of the sacral plexus.

Quadratus Femoris.—*Origin,* from the external border of the tuberosity of the ischium; *insertion,* into the upper part of the linea quadrati, on the posterior aspect of the trochanter major; *action,* rotates the thigh outward; *nerves,* branches of the sacral plexus.

Obturator Externus.—*Origin,* from the inner two-thirds of the anterior aspect of the obturator membrane and the tendinous arch covering the canal for the obturator vessels and nerves, and the descending ramus of the pubis and the ascending ramus of the ischium; *insertion,* into the digital fossa of the femur; *action,* rotates the thigh outward; *nerve,* the obturator.

Biceps, or biceps flexor cruris (*m. biceps femoris*).—*Origin,* arises by two heads—the long head (*caput longum*), from the lower and inner facet of the tuberosity of the ischium by a common tendon to the long head of the semitendinosus; the short head (*caput breve*), from the outer lip of the linea aspera, between the vastus externus and the adductor magnus; *insertion,* outer side of head of fibula, by two portions, on either side of

the external lateral ligament of the knee joint, sending a band forward to the outer tuberosity of the tibia. This tendon forms the outer hamstring; *action,* flexes the leg upon the thigh; *nerve,* the great sciatic.

Semitendinosus.—*Origin,* from a common tendon, together with the long head of the biceps, from the tuberosity of the ischium; *insertion,* into the inner and upper part of the shaft of the tibia; *action,* rotates the leg inward; *nerve,* the great sciatic.

Semimembranosus.—*Origin,* from the outer and upper facet of the tuberosity of the ischium to the outer side and above the origin of the semimembranosus and the biceps; *insertion,* into the posterior inner aspect of the inner tuberosity of the tibia, under the internal lateral ligament by three portions—the internal portion into the inner side of the internal tuberosity, the posterior portion into the posterior part of the outer condyle of the femur, forming the principal part of the posterior ligament of the knee joint, and middle portion into the posterior aspect of the inner tuberosity; *action,* flexes the leg upon the thigh; *nerve,* the great sciatic.

These two tendons (semimembranosus and semitendinosus), together with the gracilis and sartorius, form the inner hamstring.

MUSCLES OF THE LEG.

Anterior Set.

Tibialis Anticus (*m. tibialis anterior*).—*Origin,* from the upper and outer two-thirds of the shaft of the tibia, the interosseous membrane, and the intermuscular septum between it and the extensor longus digitorum; *insertion,* into the lower and inner aspect of the internal cuneiform bone and base of the first metatarsal bone; *action,* flexes the foot; *nerve,* the anterior tibial.

Extensor Proprius Pollicis (*m. extensor hallucis longus*).—*Origin,* from the anterior aspect of the fibula and the interosseous membrane and the intermuscular septum between it and the extensor longus digitorum; *insertion,* into the base of the last phalanx of the great toe; *action,* extends the great toe; *nerve,* the anterior tibial.

Extensor Longus Digitorum (*m. extensor digitorum longus*).—*Origin,* from the upper two-thirds of the anterior aspect of the shaft of the fibula and the outer tuberosity of the tibia, from the deep fascia of the interosseous membrane and the

intermuscular septum, between it and the perinei on the outer and the tibialis anticus on the inner side; *insertion,* by three tendons into the bases of the first and second phalanges of the four lesser toes, the innermost tendon dividing into two; each tendon (except the fourth) is joined opposite the metatarso-

FIG. 75.

Anterior muscles of leg; 3, tibialis anticus; 4, extensor longus digitorum; 5, extensor proprius pollicis; 6, peroneus tertius; 7, peroneus longus; 8, peroneus brevis.

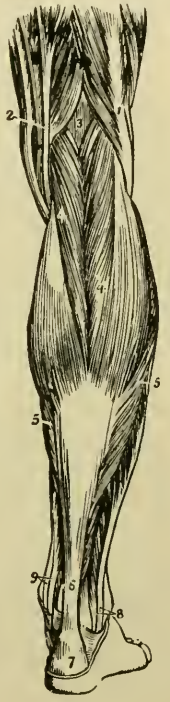

FIG. 76.

Posterior muscles of leg; 4, popliteus; 5, gastrocnemius; 6, tendo Achillis; 8, tendons of peroneus longus and brevis; 9, tibialis posticus and flexors.

phalangeal joint by the tendon of the extensor brevis digitorum, and receives an expansion from the lumbricales and interossei; at the first interphalangeal articulation the tendons divide into three slips—the middle one for insertion into the second phalanx, and the other two uniting to be inserted into the base

of the third; *action,* extends the phalanges and, continuing, flexes the foot upon the leg; *nerve,* the anterior tibial.

Peroneus Tertius (*m. peronæus tertius*).—*Origin,* from the lower front part of the fibula on its outer side, from the interosseous membrane, and the intermuscular septum between it and the peroneus brevis; *insertion,* into the metatarsal bone of the little toe; *action,* flexes the tarsus upon the leg; *nerve,* the anterior tibial.

Posterior Superficial Set.

Gastrocnemius.—*Origin,* from the upper and back part of the external and internal condyles of the femur on either side, above the origin of the popliteus, and from the supracondyloid ridges; *insertion,* by joining with the tendon of the soleus to form the tendo Achillis; *action,* extends the foot; *nerve,* from the internal popliteal.

Soleus.—*Origin,* from the oblique line of the tibia, from the middle third of the internal border, and from the posterior surface of the head of the fibula; *insertion,* by joining with the tendon of the gastrocnemius to form the tendo Achillis; *action,* extends the foot; *nerve,* the internal popliteal.

Tendo Achillis (*tendo calcaneus*).—*Origin,* from the union of the gastrocnemius and soleus; is the largest and strongest tendon in the body; it is inserted into the inferior surface of the posterior tuberosity of the os calcis, having a synovial bursa (*bursa tendinis calcanei* [*Achillis*]) between it and the bone.

Plantaris.—*Origin,* from the posterior ligament of the knee-joint and the lower portion of the outer division of the linea aspera; *insertion,* into the posterior part of the os calcis to the inner side of the tendo Achillis; *action,* the rudiment of a muscle intended to render tense the plantar fascia; *nerve,* the internal popliteal.

Posterior Deep Set.

Popliteus.—*Origin,* from the outer side of the external condyle, from the posterior ligament of the knee-joint; *insertion,* above the oblique line on the posterior aspect of the shaft of the tibia; *action,* assists in flexing the leg; *nerve,* the internal popliteal.

Flexor Longus Hallucis (*m. flexor hallucis*).—*Origin,* from the lower two-thirds of the internal surface of the fibula, from the lower part of the interosseous membrane, fascia cov-

ering tibialis posticus, and from the intermuscular septum; it passes behind the internal malleolus; *insertion,* into the base of the last phalanx of the great toe; *nerve,* posterior tibial.

Flexor Longus Digitorum—Perforans (*m. flexor digitorum longus*).—*Origin,* from the posterior aspect of the tibia, below the oblique line; it passes behind the internal malleolus; *insertion,* into the bases of the last phalanges of the four lesser toes, passing through the division in the tendons of the flexor brevis digitorum; *action,* flexes the phalanges and, continuing, extends the foot on the leg; *nerve,* the posterior tibial.

Tibialis Posticus (*m. tibialis posterior*).—*Origin,* from the posterior aspect of the shaft of the tibia, and from the upper two-thirds of the shaft of the fibula, and from the whole length of the interosseous membrane and the intermuscular septa on either side of it; it passes behind the inner malleolus; *insertion,* into the internal cuneiform bone and the tuberosity of the scaphoid; it contains a sesamoid bone in its tendon; *action,* extends the tarsus upon the leg; *nerve,* the posterior tibial.

Fibular Region.

Peroneus Longus (*m. peronæus longus*).—*Origin,* from the upper two-thirds of the shaft of the fibula, the head of the fibula, the intermuscular septa, and the deep fascia; it passes behind the outer malleolus along with the peroneus brevis; *insertion,* into the base of the metatarsal bone of the great toe; this tendon changes its course twice, first at the external malleolus, second at the cuboid bone, and usually has a sesamoid bone developed in its tendon; *action,* extends and everts the foot upon the leg; *nerve,* musculocutaneous branch of the external popliteal.

Peroneus Brevis (*m. peronæus brevis*).—*Origin,* from the outer and middle third of the fibula and the intermuscular septa on either side; *insertion,* into the upper surface of the base of the metatarsal bone of the little toe; *action,* extends the foot upon the leg; *nerve,* musculocutaneous branch of the external popliteal.

MUSCLES OF THE FOOT.

Dorsal Region.

Extensor Brevis Digitorum (*m. extensor digitorum brevis*).—*Origin,* from the external calcaneoastragaloid ligament, from the annular ligament, and from the outer side of

the os calcis; *insertion,* by four tendons—the first one into the first phalanx of the great toe, the other three into the long extensor tendons of the second, third, and fourth toes on their outer sides; *action,* extends the phalanges of the four inner toes and the first phalanx of the great toe; *nerve,* the anterior tibial.

Plantar Region.

The muscles of this region are divided into four sets.

First Set.

Abductor Hallucis.—*Origin,* from the internal annular ligament, from the inner tubercle of the os calcis, from the intermuscular septum on its outer side and plantar fascia; *insertion,* into the base of the first phalanx of the great toe on its inner side; *action,* abducts the great toe; *nerve,* branch of the internal plantar.

Flexor Brevis Digitorum—Perforatus (*m. flexor digitorum brevis*).—*Origin,* from the inner tubercle of the os calcis, from the plantar fascia and the intermuscular septa between it and the muscles on either side; *insertion,* into the second phalanges by a process on either side, allowing the passage of the tendon of the flexor longus digitorum; *action,* flexes second phalanges upon first and continuing may flex first phalanges bringing toes together; *nerve,* from the internal plantar.

Abductor Minimi Digiti (*m. abductor digiti quinti*).—*Origin,* from the plantar fascia, from the os calcis in front of the tubercle, and from the intermuscular septum on its inner side; *insertion,* into the first phalanx of the little toe on its outer side; *action,* abducts little toe; *nerve,* external plantar.

Second Set.

Flexor Accessorius (*m. quadratus plantæ*).—*Origin,* by two heads, one from the os calcis in front of the outer tubercle, the other from the inner surface of the os calcis and the calcaneoscaphoid ligament; *insertion,* by a common tendon into the tendon of the flexor longus digitorum; *action,* accessory to the long flexor; *nerve,* external plantar.

Lumbricales.—Four small muscles. *Origin,* from the tendons of the flexor longus digitorum, after their division, each one arising from two tendons; *insertion,* into the base of the first phalanx of the same toe and the tendinous expansion of the extensor longus digitorum; *nerves,* the external plantar nerve supplies the two external, the internal plantar nerve the two internal, muscles.

Third Set.

Flexor Brevis Hallucis (*m. flexor hallucis obliquus*).—*Origin,* from the external cuneiform bone, and the internal border of the cuboid bone, and the tendinous expansion of the tibialis posticus; *insertion,* into the first phalanx of the great toe on either side; *action,* flexes first phalanx of great toe; *nerves,* the internal plantar and sometimes a branch from the external plantar.

Adductor Hallucis.—*Origin,* from the bases of the second, third, and fourth metatarsal bones and from the sheath of the tendon of the peroneus longus; *insertion,* into the base of the first phalanx of the great toe on the outer side; *nerve,* external plantar.

Flexor Brevis Minimi Digiti (*m. flexor digiti quinti brevis*).—*Origin,* from the sheath of the peroneus longus and the base of the metatarsal bone of the little toe; *insertion,* into the outer side of the base of the little toe; *nerve,* external plantar.

Adductor Transversus Hallucis (*m. transversus pedis*). —*Origin,* from the inferior metatarsophalangeal ligaments of the three outer toes, or at other times from the third and fourth, and also from the transverse ligament of the metatarsus; *insertion,* into the outer side of the first phalanx of the great toe; *nerve,* external plantar.

Fourth Set.

Dorsal Interossei (*m. interossei dorsales*).—Four in number. *Origin,* by two heads from the adjoining bases of the metatarsal bones; *insertion,* into the bases of the first phalanges of the second, third and fourth toes, the second having two, one on either side, and the third and fourth on their outer side; *action,* abduct the toes from the middle line of the second toe; *nerve,* external plantar.

Plantar Interossei (*m. interossei plantares*).—Three in number. *Origin,* from the bases of inner side of the third, fourth and fifth metatarsal bones; *insertion,* into the bases of the first phalanges on the same side; *action,* adduct the toes toward a middle line, which would pass through the second toe; *nerve,* the external plantar.

The Fascias (Fasciæ).

The fascias are strong, fibrous (fibroareolar) investments protecting and binding together the muscles, and in places form-

ing ligaments and intermuscular septa. They consist, for the most part, of two layers, a superficial and a deep.

Fascias of the Cranium and Face.—The *superficial fascia* of the *head* and *face* is everywhere intimately connected to the skin, except over the temporal region, where it forms a distinct lamina, inclosing the superficial temporal vessels and auricular muscles.

The deep temporal fascia (*fascia temporalis*) is a dense, fibrous membrane, attached to the margins of the temporal fossa and zygoma, and from which, in part, the temporal muscle arises.

Fascias of the Neck.—The *superficial fascia* is continuous below with that covering the pectoral muscles and deltoid, and blends above with the superficial facial muscles and fascia.

The deep fascia (*fascia colli*) adheres below to the clavicle and sternum, and is continuous with the thoracic fascia. As it ascends the neck it ensheathes the great vessels of the neck, sends processes to the larynx, trachea, pharynx and esophagus, and above ensheathes the submaxillary and parotid glands, and forms the stylomaxillary, or stylomandibular ligament (*ligamentum stylomandibulare*).

Fascias of the Trunk.—The *superficial fascia* may consist of two or more layers in places. It is continuous above with the fascias of the neck and upper extremity, and below with the thigh. Over the pectoral region the mammary glands are inclosed between its layers (*ligamenta suspensoria*); below the level of the umbilicus it again divides into two layers, the superficial of which is continuous with the superficial layer of the superficial fascia in the thigh, while the deep layer is attached to the crest of the ilium and Poupart's ligament.

The *deep fascia* forms intermuscular septa and aponeuroses.

The lumbar fascia divides into three layers, inclosing the quadratus lumborum, multifidus spinæ and erector spinæ muscles, and gives attachment to the internal oblique and transversalis muscles. Its anterior and middle layers are attached to the transverse processes, and its posterior layer to the spinous processes. Above, its anterior layer is attached to the lower border of the last rib, forming the ligamentum arcuatum externum (*arcus lumbocostalis lateralis*). The ligamentum arcuatum internum (*arcus lumbocostalis medialis*) extends from the body of the first or second lumbar vertebra to the transverse process, inclosing the psoas magnus muscle.

Abdominal and Pelvic Fascia.—The transversalis fascia is a thin aponeurosis between the peritoneum and transversalis

muscle. It is attached below to the pubes, pectineal line, Poupart's ligament and the femoral vessels, and becomes continuous with the iliac and pelvic fascia. The pelvic fascia (*fascia pelvis*) lines the pelvic cavity throughout, attached to the symphysis pubis, margin of obturator foramen, and the sacrum and becomes continuous with the iliac and transversalis fascias. Below it forms the *arcus tendineæ*, for the origin of muscles and the division into the rectovesical and obturator fascias (*vide* Perineum).

The iliac fascia (*fascia iliaca*) is a thin, fibrous membrane investing the psoas and iliacus muscles. Above it is attached to the ligamentum arcuatum internum, laterally, with the bodies of the vertebræ and sacrum, and below it is attached to Poupart's ligament, the femoral vessels, pectineal eminence, and the capsule of the hip-joint.

Upper Extremity.—The *superficial fascia* is a thin membrane, inclosing the parts throughout, and adherent to the deep fascia beneath.

The *deep fascia* is very dense and strong. It gives off numerous intermuscular septa, and is attached to the olecranon and back part of ulna, and becomes continuous below with the anterior and posterior annular ligaments of the wrist-joint, both of which it forms.

The anterior annular ligament (*ligamentum carpi transversum*) is attached to the ridge of the trapezium, the tuberosity of the scaphoid, the unciform process of the unciform, and the pisiform bone, forming a strong, fibrous arch, under which the flexor tendons of the fingers pass.

The posterior annular ligament (*ligamentum carpi dorsale*) is attached to the radius, ulna, cuneiform and pisiform bones, and the palmar fascia, forming a fibrous arch for the passage of the extensors of the fingers.

The palmar fascia (*aponeurosis palmaris*) is an exceedingly dense, triangular mass of adipose and fibrous tissue, attached behind to the anterior annular ligament, and in front divides into four fasiculi, each of which subdivides into two, inserted into the lateral ligaments of the metacarpophalangeal articulations. These digitations allow the passage of the flexor digitorum tendons, the digital vessels and nerves. It is attached above to the skin, and laterally gives off vertical septa, which separate the middle from the lateral groups of palmar muscles.

FASCIAS OF THE LOWER EXTREMITY.

The *superficial fascia* resembles that in other localities, except that, in the front of the thigh, it consists of two or more layers between which are found the superficial vessels, nerves and lymphatic glands. The under layer is attached to the margins of the saphenous opening, where it is perforated by numerous lymphatic vessels and blood-vessels; hence its name, cribriform fascia (*fascia cribrosa*).

The *deep fascia* of the thigh, or *fascia lata,* is a dense fibrous aponeurosis attached to the pubes, Poupart's ligament, crest of the ilium, sacrum and coccyx, inclosing the gluteus maximus and tensor vaginæ femoris between its layers, attached to the linea aspera, and below to all the bony points about the knee joint, being attached to the head of the fibula and tuberosities of the tibia by the iliotibial band (*tractus iliotibialis* [*Maissiati*]).

The saphenous opening (*fossa ovalis*) is a large opening in the fascia lata at its upper and inner part closed by the cribriform fascia. Through it pass the internal or long saphenous vein, the superficial epigastric and external pudic arteries, and lymphatics. It is formed by the *iliac* and *pubic portions* of the *fascia lata.* The iliac portion becomes continuous at the pectineal line with Gimbernat's ligament, and its free border forms the *falciform border* (*vide* Femoral Hernia).

The pubic portion is continuous behind the femoral vessels with the femoral sheath and the iliac and psoas fascia. At the lower border of the saphenous opening it is continuous with the iliac portion of the fascia lata.

The deep fascia of the leg (*fascia cruris*) is attached above to the bony points about the knee, continuous with the fascia lata, invests the leg completely, except the inner surface of the tibia, sends in a *deep transverse fascia* between the superficial and deep muscles on the posterior aspect of the leg, and below becomes continuous with the annular ligament of the ankle-joint.

The *annular ligament* of the *ankle joint* consists of three portions—the *internal, external* and *anterior.* It is attached to the bony points about the ankle joint, the external and internal malleoli, surfaces of the os calcis, and allows the passage of the muscles to the foot.

The dorsal aponeurosis of the foot (*fascia dorsalis pedis*) covers the back of the foot, uniting with the plantar fascia at

the sides, and terminating anteriorly at the heads of the metatarsal bones.

The plantar aponeurosis (*aponeurosis plantaris*) consists of three portions, a central and two lateral portions.

The *middle* portion commences at the inner tubercle of the os calcis and proceeds, gradually becoming broader, to the heads of the metatarsal bones, where it divides into four branches, each of which nearly surrounds the corresponding flexor tendon to which it gives passage, and is inserted into the edges of the dorsal expansion of the first phalanges.

The *inner portion* arises from the internal annular ligament, covers the abductor pollicis muscle, and joins the dorsal aponeurosis internally and the internal septum externally.

The *outer portion*, much stronger, arises from the os calcis, covers the abductor minimi digiti muscle, and joins the external plantar septum internally and dorsal aponeurosis externally, and is firmly attached to the base of the fifth metatarsal bone.

Numerous septa pass from the upper surface of the plantar fascia between the plantar muscles and tendons to be inserted into the metatarsal and tarsal bones.

THE HEART AND VASCULAR SYSTEM.

The pericardium is a conical, membranous, closed sac, surrounding the heart and the roots of the great vessels. It occupies the greater part of the middle mediastinum, its apex upward, its base downward and attached to the central tendon of the diaphragm. It is a fibroserous membrane, consisting of an outer fibrous coat and an inner serous coat. The latter is composed of a visceral layer (*epicardium*) reflected over the heart and vessels, and a *parietal layer* lining the inner surface of the fibrous sac. It secretes a thin, serous fluid.

The fibrous coat becomes continuous above with the deep layer of the cervical fascia, being prolonged upward on the outer surfaces of all the great vessels, except the inferior vena cava.

The Heart (Cor).

The heart is a hollow, muscular organ, placed obliquely within the chest, and inclosed within the pericardium. Its base (*basis cordis*) is directed upward and backward, opposite the fifth to eighth dorsal vertebræ; its apex (*apex cordis*) downward to the left, opposite the interspace between the fifth and sixth costal cartilages. Its weight is about ten to twelve ounces in male, eight to ten in female; length five inches, breadth three and a half inches, thickness two and a half inches.

It is divided into four parts:—

Right auricle,	Left auricle,
Right ventricle,	Left ventricle,

an auricle and ventricle on each side. This division is indicated on both surfaces of the organ by two grooves crossing each other and named, from their position, the longitudinal or the interventricular (*sulci longitudinalis*), the transverse or the auriculoventricular (*sulcus coronarius*) grooves.

Right Auricle.—The right auricle (*atrium dextrum*) consists of two portions—a *sinus* or *atrium* and an *appendix auriculæ*, which projects to the right side of the origin of the aorta. The walls at the fore and outer part and in the auricular appendage are thickened by musculi pectinati. The mus-

cular tissue of the auricles is connected with that of the ventricles by a small band of fibers, the *auriculoventricular fasciculus*, or "bundle of His."

This smooth ridge is known inside the auricle as the *crista terminalis of His*, and outside the groove is called the *sulcus terminalis of His*. Its interior presents the following parts:—

Openings of the *superior* and *inferior venæ cavæ*, neither of which are protected by valves:

Opening of coronary sinus (*sinus coronarius*), protected by a valve of two unequal segments—the coronary valve;

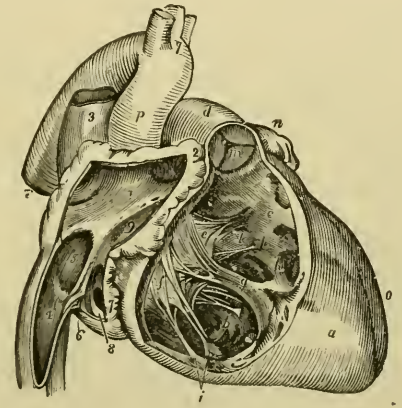

FIG. 77.

Right side of heart; *a*, apex; *b*, right ventricle; *d*, pulmonary artery; *e*, *f*, chordæ tendineæ; *p*, aorta; 3, superior vena cava; 5, inferior vena cava.

Foramina Thebesii (*foramina venarum minimarum*), minute foramina returning the blood from the heart-muscle;

Eustachian valve (*valvula venæ cavæ inferioris* [*Eustachii*]), the remains of a fetal structure, extending from the right of the orifice of the inferior vena cava to the outer border of the oval foramen;

Fossa ovalis, the obliterated foramen ovale of fetal life;

Annulus ovalis (*limbus fossæ ovalis* [*Vieussenii*]), the oval margin of the preceding structure;

Tubercle of Lower (*tuberculum intervenosum* [*Loweri*]), a small rudimental projection on the right wall, directing the blood toward the auriculoventricular opening;

Musculi pectinati, elevated muscular columns before referred to;

Auriculoventricular opening (*ostium venosum dextrum*), an oval aperture about one inch in diameter, surrounded by a fibrous ring, and protected by the *tricuspid* valve.

The Left Auricle (*atrium sinistrum*).—The left auricle is smaller, and its walls somewhat thicker than the right, and consists of a cuboidal sinus and an elongated appendix auriculæ. Its interior surface is smooth, except the auricular appendage, which is provided with musculi pectinati, and presents the following openings:—

Pulmonary veins, four in number, two on either side; they are without valves;

Auriculoventricular opening (*ostium venosum ventriculi sinistri*), an oval aperture, rather smaller than the right, and protected by the bicuspid or mitral valve.

The Right Ventricle (*ventriculus dexter*).—The right ventricle is triangular, with thick walls (one-quarter inch), and occupies the anterior part of the organ. Its capacity is about three fluidounces. It presents the following:—

Infundibulum (*conus arteriosus*), a conical pouch, from which the pulmonary artery arises;

Columnæ carneæ (*trabeculæ carneæ*), muscular columns projecting from the inner surface, three or four of which (*musculi papillares*) give attachment to the chordæ tendineæ;

Chordæ tendineæ, delicate tendinous cords, connecting the margins and central portions of the tricuspid valve with the columnæ carneæ;

Tricuspid valve (*valvula tricuspidalis*), consists of three segments or cusps (*cuspides*) which consist of triangular duplications of endocardium, strengthened by fibrous tissue; they are attached by their bases to the auriculoventricular orifice (*annulus fibrosis dexter*) and their free margins give attachment to the chordæ tendineæ (*ostium venosum ventriculi dextri*).

Semilunar valves (*valvulæ semilunares a. pulmonalis*) consist of three semicircular folds, guarding the orifice of the pulmonary artery; their free margins are thickened by nodules, the corpora Arantii (*nodulus valvulæ semilunaris* [*Arantii*]);

Opening of the pulmonary artery (*ostium arteriosum*), at the apex of the conus arteriosus, is circular in outline and protected by the semilunar valves;

Sinuses of Valsalva, three pouches, situated one behind each semilunar valve.

The Left Ventricle (*ventriculus sinister*).—The left ventricle is longer, more conical, and its walls three times as thick as the right. It forms the apex (*apex cordis*) and most of the posterior and inferior (*facies diaphragmatica*) portion of the heart. It presents the following parts in its interior:—

Columnæ carneæ, and

Chordæ tendineæ, much the same as the right;

Auriculoventricular opening (*ostium venosum ventriculi sinistri*), a little smaller than the corresponding orifice on the right side, similarly formed, and protected by the mitral valve;

The mitral valve (*valvula bicuspidalis*) consists of two unequal segments, attached the same as the tricuspid, and also affording attachment to the chordæ tendineæ;

Aortic opening (*ostium arteriosum*), a circular opening to the right of the auriculoventricular opening;

The semilunar valves (*valvulæ semilunares aortæ*), three in number, surround the aorta, and are larger and stronger than those on the right side;

Sinus aortici (sinuses of Valsalva) are depressions situated behind each valve.

Structure of the Heart.—The heart is composed of finely striated muscular walls, with external serous covering from the pericardium and internal serous lining the *endocardium*, the latter continuous with that of blood vessels. The endocardium is a thin, translucent membrane, consisting of endothelium and a fine basement membrane, beneath which is a fibroelastic layer. The doublings of these layers constitute the valves. The tricuspid and mitral valves, as well as the aortic and pulmonary, are surrounded by a fibroelastic ring (*annulus fibrosus*), which furnishes a "punctum fixum" for the varying musculature of the heart.

The *muscular structure* consists of an intricate interlacement of fibrous bands. Of these there are two groups—those of the auricles and those of the ventricles.

The former consist of a superficial transverse set and the internal or deep set, of which there are the looped and the circular.

The fibers of the ventricles consist of seven layers in a general oblique and circular manner, and terminating in a *whorl* or *vortex* at the apex, some of the fibers terminating in the columnæ carneæ, musculi pectinati, while others ascend, forming in their course a twisted loop like the figure 8. The *arteries* of the heart are the right and left coronary. The *veins* are the anterior or great, middle or posterior cardiac, the left auricular,

the right auricular and venæ Thebesii. The *lymphatics* end in thoracic and right lymphatic ducts. The *nerves* are derived from the cardiac plexus of pneumogastric, spinal and great sympathetic.

The Vascular System.

The vascular system consists of four sets of vessels—arteries, capillaries, veins and lymphatics. Anastomoses are common.

The vessels that convey blood to and from the tissues of the body generally constitute the *general system.*

Those that carry blood to and from the lungs form the *pulmonary system.*

The vessels passing to the liver form the *portal system.*

The arteries, for the most part, are composed of three coats:—

Tunica adventitia, or external coat, consists of fibrous tissue, thinnest on the largest trunks, and disappears in those which merge into capillaries.

The *tunica media,* or middle coat, is thickest in the large trunks, and consists mainly of elastic tissue, together with some unstriated muscle and some connective tissue; in smallest arteries it consists alone of muscular tissue.

The *tunica intima,* or internal coat, thinnest, most transparent and elastic, is composed of lining endothelium, basement membrane, and layers of elastic tissue. The elastic tissue in layers forms nets, constituting so-called *perforated or fenestrated membrane.* It becomes continuous with capillaries. The walls of larger arteries are supplied by blood vessels from neighboring arteries. Nutrient arteries form a network of capillaries, and returning veins empty into contiguous veins. The nerves are both medullated and non-medullated and chiefly pass to the muscle-fibers.

Arteries dilate and contract with the action of the heart, constituting the *pulse.*

The veins.—Larger, more numerous, and more capacious than the arteries, with one exception (the portal vein) they convey blood to the heart. The large veins emptying into the heart are:—

Four pulmonary;

Superior and inferior venæ cavæ;

Coronary veins from walls of the heart through the coronary sinus.

The larger arteries have, each, one companion vein, the medium arteries two. In some positions they form venous plexuses, corresponding to arterial anastomoses.

Many large veins have valves, usually in pairs, attached by convex border.

There are, however, no valves in the pulmonary, superior and inferior cavæ, azygos, portal vein and branches, hepatic, renal, uterine, and spinal, and most of those of head or neck.

In certain membranes and organs channels exist, lined by internal coat of blood vessel, termed venous sinuses, as in the dura mater, bones and uterus.

The coats of the veins are similar to those of the arteries, and differ chiefly in the weakness of the middle or muscular coat, which allows them to remain open.

The *external* fibrous coat has also longitudinal, unstriated muscular tissue in veins of abdominal cavity:—

The *middle,* unstriated muscular and fibrous tissue;

The *internal,* no fenestrated membrane.

The walls have nutritive vessels, and are well supplied with non-medullated and medullated nerves, which pass to the muscular coat.

Both arteries and veins are insensitive in health.

The capillaries communicate with the terminations of the arteries and veins, and do not communicate with tissue proper, which is supplied by imbibition. They vary in size in different organs from $\frac{1}{2000}$ to $\frac{1}{3000}$ inch in diameter, but all permit the passage of blood corpuscles. Their form is dependent on the form of tissue supplied.

Composition of the Blood.—Blood within the vessels is a perfect fluid, alkaline reaction, saline taste, average specific gravity 1060, and of feeble, peculiar odor. Within the arterial vessels it is bright red in color, becoming in the veins (particularly the venæ portæ and pulmonary arteries) a deep maroon or reddish-black color.

It constitutes about $\frac{1}{12}$ or $\frac{1}{14}$ of the body-weight, and consists of the liquor sanguinis and the corpuscles, red, white, etc.

The *red corpuscles* or *erythrocytes* are elastic, specific gravity 1088, non-nucleated, and average about $\frac{1}{3000}$ line in diameter. A cubic millimeter of blood contains, in the male, 5,000,000 red blood-cells, and, in the female, 4,500,000. On evaporation they become stellate, and swell up with water. They vary much in size and shape in different animals, and contain hemoglobin, which carries oxygen to the tissues, and CO_2 to the lungs.

The *colorless corpuscles* or *leucocytes* are free nucleated protoplasmic masses, capable of ameboid movement. They contain fat-corpuscles, myosin, cholesterin, protagon, glycogen and nuclein. There is about 1 white corpuscle to every 600 red corpuscles, or in 1 cubic millimeter of blood there are present about from 5000 to 10,000 white corpuscles, an average of 7500. According to Ehrlich and others, by means of a "tri-acid stain," five varieties of colorless cells may be distinguished as follows:—

1. Small lymphocytes,
2. Large lymphocytes or mononuclear leucocytes,
3. Transitional leucocytes,
4. Polymorphonuclear leucocytes, and
5. Eosinophiles.

The *liquor sanguinis* is a pale, amber-colored fluid, holding the corpuscles in suspension, and very prone to coagulate. The coagulation of the blood results in the formation of a clot, or crassamentum, and the serum, in the following manner:—

Fluid blood ..... { Corpuscles. { White corpuscles. / Red corpuscles. } } Clot.
{ Plasma or Liquor Sanguinis { Fibrin. / Serum. } } Serum.

THE CIRCULATION OF THE BLOOD.

Fetal Circulation.—The fresh arterial blood returning from the placenta through the umbilical vein enters the fetus at the umbilicus, passes along the suspensory ligament to the under surface of the liver, where a portion passes directly into the inferior vena cava by the junction of the ductus venosus with the left hepatic vein, a portion enters the liver and reaches the inferior vena cava through the hepatic veins, and the larger portion mixes with the portal venous blood before reaching the vena cava through the hepatic veins. It ascends in the inferior vena cava along with the venous blood from the trunk and lower extremities to enter the right auricle of the heart (Fig. 78). Here it is directed by the Eustachian valve through the foramen ovale into the left auricle, into the left ventricle, and so through the aorta, chiefly to the head and upper extremities, a small portion only entering the descending aorta. It is returned by the superior vena cava to the right auricle, passes over the Eustachian valve to the right ventricle, and so through the pulmonary artery toward the lungs, but (the lungs being almost

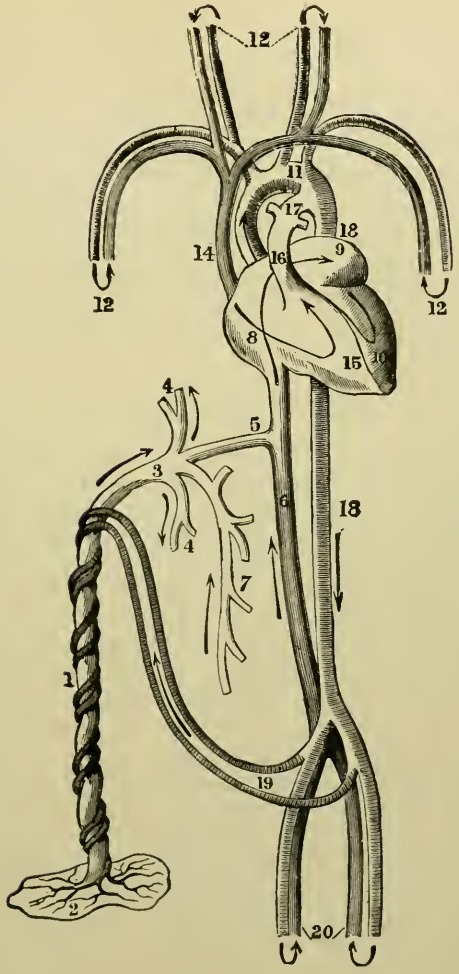

FIG. 78.

Diagram of the fetal circulation: 1, umbilical cord, with veins and arteries; 2, placenta; 3, divisions of umbilical vein; 4, hepatic branches; 5, ductus venosus; 6, inferior vena cava; 7, portal vein; 8, right auricle; 9, left auricle; 10, left ventricle; 11, arch of aorta; 14, superior vena cava; 15, right ventricle; 16, pulmonary artery; 17, ductus arteriosus; 18, descending aorta; 19, umbilical arteries.

impervious) most of it passes through the ductus arteriosus into the descending aorta (mixing with the small quantity from the left ventricle before mentioned) to supply the lower extremities, abdominal and pelvic viscera, and as venous blood to return through the umbilical arteries to the placenta.

Circulation After Birth and in Adult.—The dark venous blood from the entire body is received through the superior and inferior venæ cavæ and coronary sinus into the right auricle, whence it passes into the right ventricle, to be sent through the pulmonary artery into the lungs. Here it becomes oxygenated, and as bright arterial blood it returns to the left auricle by the pulmonary veins, and passes into the left ventricle, whence it is distributed through the aorta and its branches to the entire body.

AORTA (ARTERIA MAGNA).

This is the main trunk of the systemic arteries. Commencing at the upper part of the left ventricle, it ascends for a short distance, arches backward over the right pulmonary artery, the root of the left lung, to the left side of the body of the fourth dorsal vertebra, where it passes downward through the diaphragm and becomes the abdominal aorta. It then descends to the lower border of the fourth lumbar vertebra, where it terminates by dividing into the left and right common iliac arteries. In its course it is divided into the arch, the thoracic aorta, and the abdominal aorta, the arch being subdivided into the ascending, transverse and descending portion.

Relations.—The *ascending portion* of the arch is in relation on the right side with the superior cava and right auricle; on the left side with the pulmonary artery; in front, with the pulmonary artery, the pericardium, the right appendix auriculæ and the thymus gland; and behind, with the root of the right lung and the right pulmonary vessels.

The *transverse portion* of the arch is in relation in front with the left lung and pleura, the left pneumogastric and phrenic nerves, the superficial cardiac nerves, the left superior intercostal vein, and the thymus gland; behind, with the trachea, the esophagus, the thoracic duct, the deep cardiac plexus, and the left recurrent nerve; above, with the arteria innominata, the left innominate vein, the left subclavian, and the left carotid; and below, with the left bronchus, the bifurcation of the pulmonary artery, the left recurrent nerve, and the remains of the ductus arteriosus.

The *descending portion* of the arch is in relation in front with the root of the left lung and the pleura; behind, with the left side of the body of the fifth dorsal vertebra; on the right side with the thoracic duct and esophagus; and on the left side with the pleura.

The branches of the aorta are, from the arch:—

Two coronary,	Left common carotid,
Innominate,	Left subclavian.

THE CORONARY ARTERIES supply the heart and are two in number—the right and the left (*a. coronaria cordis dextra et sinistra*). The right arises from the aorta, above the right semilunar valve, and passes downward in a groove between the right auricle and ventricle on its posterior surface, dividing into two branches, one of which anastomoses with the left coronary. The left coronary arises above the left semilunar valve and descends in the anterior interventricular groove, where it divides into two branches, one of which anastomoses with the right coronary.

ARTERIA INNOMINATA (*a. anonyma*).—This is the largest branch from the arch of the aorta. It ascends to the upper border of the right sternoclavicular articulation, where it divides into the right common carotid and the right subclavian arteries. It is a short vessel, from one and a half to two inches long.

Relations.—It is in relation in front with the sternum, the sternohyoid and sternothyroid muscles, the left innominate and right inferior thyroid veins, the thymus gland, and the cardiac branch from the right pneumogastric; behind, with the trachea; on the right side, with the pleura and right vena innominata and right pneumogastric nerve; on the left side, with the left carotid and the thymus gland.

THE COMMON CAROTID ARTERIES (*a. carotis communis*).—The left common carotid, arising directly from the arch of the aorta, is longer and ascends more obliquely and is more deeply placed than the right.

From the sternoclavicular articulation to their division at the upper border of the thyroid cartilage the common carotid on either side pursues the same course. At the lower part of the neck the two vessels are separated by a very short interval, which is occupied by the trachea, but at the upper part they diverge widely; the larynx, pharynx, thyroid body, and several muscles being interposed between them. It ascends the neck in a direction indicated by a line drawn from the sternoclavicular articulation to midway between the mastoid process and the angle of the lower jaw.

Relations.—It is in relation in front with the sternomastoid, sternothyroid, sternohyoid and omohyoid muscles, the anterior jugular and the superior and middle thyroid veins, the sternohyoid artery, and the descendens and communicans noni nerves; behind it rests upon the longus colli and rectus capitis anticus major muscles and is in relation with the sympathetic nerve, the recurrent laryngeal nerve, and the inferior thyroid artery; on the outer side, with the pneumogastric and

the internal jugular vein; to the inner side, the larynx, trachea, pharynx, thyroid gland, inferior thyroid artery and the recurrent laryngeal nerve.

THE EXTERNAL CAROTID ARTERY (A. CAROTIS EXTERNA).

From its commencement at the superior border of the thyroid cartilage it passes upward and forward and then backward, beneath the anterior margin of the sternomastoid muscle, in a direction indicated by an imaginary line drawn from the superior border of the thyroid cartilage to a point midway between the meatus and the neck of the condyle of the lower jaw. It ascends through the space known as the *superior triangle of the neck.*

Relations.—It is in relation in front with the parotid gland and the facial nerve and temporomaxillary vein passing through it, covered by the skin, superficial fascia, platysma, and deep fascia, and is crossed by the digastric and stylohyoid muscles, hypoglossal nerve, lingual and facial veins; behind it is separated from the internal carotid by the parotid gland, styloglossus and stylopharyngeus muscles, and the glossopharyngeal nerve, and at its lower part the superior laryngeal nerve ascends behind it; to its inner side it is in relation with the pharynx, hyoid bone, superior laryngeal nerve, and the ramus of the lower jaw, from which it is separated by the parotid gland.

The branches of the external carotid are eight:—

1. Superior thyroid,
2. Lingual,
3. Facial,
4. Occipital,
5. Posterior auricular,
6. Ascending pharyngeal,
7. Temporal,
8. Internal maxillary.

1. SUPERIOR THYROID (*a. thyreoidea superior*) arises below the great cornu of the hyoid bone, passes beneath the sternohyoid, omohyoid and sternothyroid muscles to the upper part of the thyroid gland, where its terminal branches anastomose with its fellow of the opposite side. Its branches are:—

(*a*) Hyoid (*ramus hyoideus*), to the lower border of the hyoid bone;

(*b*) Superficial descending branch (*ramus sternocleidomastoideus*), crosses the common carotid artery to supply the skin and sternomastoid muscle;

(*c*) Superior laryngeal (*a. laryngea superior*), passes beneath the thyrohyoid muscle with the superior laryngeal nerve;

(*d*) Cricothyroid (*ramus cricothyreoideus*), crosses the cricothyroid membrane.

2. The LINGUAL ARTERY (*a. lingualis*) arises from the anterior part of the external carotid, between the superior thyroid and the facial. It passes inward and upward to the greater

cornu of the hyoid bone, and, descending, reaches the under surface of the tongue and runs along its under surface as far as its tip, where it terminates as the ranine.

In its course it passes through a triangle bounded on two sides below by the two bellies of the digastric, and above by the hypoglossal nerve, passing under the hyoglossus muscle. Its branches are:—

Hyoid (*ramus hyoideus*), to the hyoid bone;
Dorsalis linguæ (*ramus dorsalis linguæ*), supplies the epiglottis, soft palate, tonsil, and the mucous membrane of tongue;
Sublingual (*a. sublingualis*), supplies mylohyoid and geniohyoglossus muscles and sublingual gland;
Ranine (*a. profunda linguæ*), the terminal branch, ends at the tip of the tongue.

3. The FACIAL ARTERY (*a. maxillaris externa*) arises from the anterior portion of the external carotid artery above the lingual. It ascends forward through the submaxillary gland, crosses the lower jaw at the anterior border of the masseter muscle, and crosses the cheek to the angle of the mouth and the side of the nose, where it terminates as the angular artery (*a. angularis*). Its branches in the neck are:—

Inferior or ascending palatine (*a. palatine ascendens*), supplies the soft palate, palatine glands, tonsil and Eustachian tube;
Tonsillar (*ramus tonsillaris*), supplies the root of the tongue and tonsil;
Submaxillary (*rami glandulares*), supplies the submaxillary gland and neighboring lymphatics, muscles, and skin;
Submental (*a. submentalis*), supplies the chin, lower lip and neighboring structures;
Muscular, to the buccinator, masseter and internal pterygoid muscles.

In the face:—

Muscular, to the same muscles as given above;
Inferior labial (*a. labialis inferior*), to the skin of the lower lip;
Inferior coronary, to the mucous membrane, muscles and glands of the lower lip;
Superior coronary (*a. labialis superior*), to the structures of the upper lip and nasal septum;
Lateralis nasi, to the skin of the nostrils, anastomoses with the nasal branch of ophthalmic;
Angular (*a. angularis*), supplies lachrymal sac and skin. All of these branches anastomose freely with the neighboring arteries.

4. The OCCIPITAL ARTERY (*a. arteria occipitalis*) arises from the posterior portion of the external carotid, about the lower border of the digastric muscle. It passes beneath the stylohyoid muscle, the digastric muscle, and part of the parotid

gland, and, ascending, grooves the internal surface of the mastoid portion of the temporal bone and distributes itself over the occiput as high as the vertex. Its branches are:—

Muscular (*rami musculares*), to splenius, digastric, stylohyoid, etc;

Sternomastoid (*a. sternocleidomastoidea*), crosses the hypoglossal to the sternomastoid muscle;

Auricular (*ramus auricularis*), is distributed to the back part of the concha;

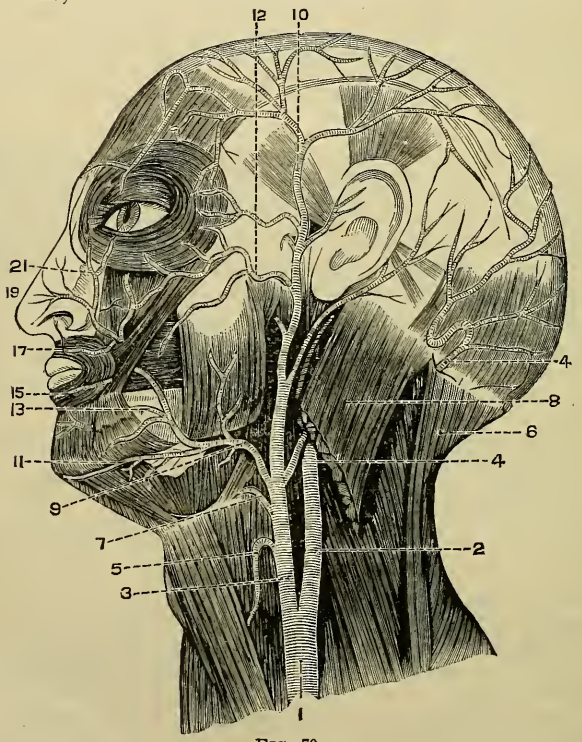

FIG. 79.

Arteries of face and head: 1, common carotid; 2, internal carotid; 3, external carotid; 4, occipital; 5, superior thyroid; 7, lingual; 9, facial; 10, temporal; 11, submental; 12, transverse facial; 13, inferior labial; 15, 17, inferior and superior coronary; 19, lateral nasal; 21, angular.

Meningeal (*ramus meningeus*), passes through the foramen lacerum posterius to the dura mater;

Arteria princeps cervicis (*ramus descendens*). Its superficial branch anastomoses with the superficial cervical, and its deep branch with the deep cervical branch from the superor intercostal.

Cranial branches are distributed to the scalp over the occiput.

5. The POSTERIOR AURICULAR ARTERY (*a. auricularis posterior*) arises from the posterior portion of the external carotid, on a level with the apex of the styloid process. It ascends beneath the parotid gland to a point between the mastoid process and the cartilage of the ear, where it divides into two branches, one going to the ear and the other to the occiput. Its branches are:—

Stylomastoid (*a. stylomastoidea*), supplies the mastoid cells, tympanum and semicircular canals, entering the cranium through the stylomastoid foramen;

Auricular (*ramus auricularis*), supplies the cartilage of the ear;

Muscular, supply the sternomastoid, digastric and stylohyoid muscles;

Glandular, to parotid gland.

6. The ASCENDING PHARYNGEAL ARTERY (*a. pharyngea ascendens*) arises about the commencement of the external carotid artery and ascends to the base of the skull upon the rectus capitis anticus major. Its branches are:—

Pharyngeal (*rami pharyngei*), supplies the three constrictors of the pharynx and the stylopharyngeus muscles;

External, to the neighboring muscles, glands, and hypoglossal and pneumogastric nerves;

Meningeal, enter the skull through the posterior and middle lacerated foramina and the anterior condyloid foramen.

7. The SUPERFICIAL TEMPORAL ARTERY (*a. temporalis superficialis*) is the smaller of the two terminal branches. It arises in the parotid gland, crosses the root of the zygoma, ascends forward a couple of inches, and divides into the anterior temporal and the posterior temporal. Its branches are:—

Transverse facial (*a. transversa faciei*), supplies the masseter muscle, parotid gland and skin;

Middle temporal (*a. temporalis media*), crosses the face to supply the temporal muscle and fascia;

Anterior auricular (*rami auriculares anteriores*), supplies the lobule, external meatus and front part of pinna.

8. The INTERNAL MAXILLARY (*a. maxillaris interna*) is the larger of the two terminal branches of the external carotid. It arises in the parotid gland about the level of the lower part of the lobe of the ear, passing close to the inner side of the neck of the condyle of the lower jaw to be distributed to the deep structures of the face. Its course is divided into three portions: the *maxillary portion*, passing inward and forward between the

internal lateral ligament and the ramus of the jaw; the *pterygoid portion,* passing upward and forward upon the external pterygoid muscle; and the third part, or *sphenomaxillary,* enters the sphenomaxillary fossa. Its branches are, from the maxillary portion:—

Tympanic (anterior) (*a. tympanica anterior*), supplies the tympanum through the Glaserian fissure, forming a capillary plexus on the tympanic membrane;

Middle meningeal (*a. meningea media*), enters the cranium through the foramen spinosum, supplies the dura mater, and gives off

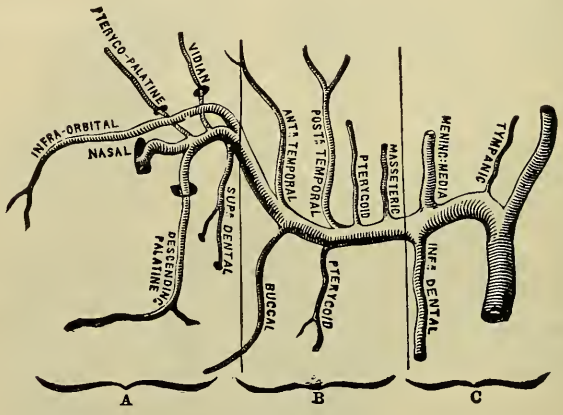

FIG. 80.

Internal maxillary artery: A, third portion; B, second portion; C, first portion.

a petrosal branch (*ramus petrosus superficialis*) to facial nerve in hiatus Fallopii;

Small meningeal (*ramus meningeus accessorius*), or meningea parva, enters foramen ovale to supply dura mater and Gasserian ganglion;

Inferior dental (*a. alveolaris inferior*), accompanies the dental nerve through the inferior dental canal to the mental foramen, supplying the jawbone, teeth, chin and mouth.

The pterygoid portion:—

Deep temporal (*aa. temporalis profunda anterior et posterior*), supply the temporal muscle;

Pterygoid (*rami pterygoidei*), to pterygoid muscles;

Masseteric (*a. masseterica*), to the masseter muscle;

Buccal (*a. buccinatoria*), to the buccinator muscle.

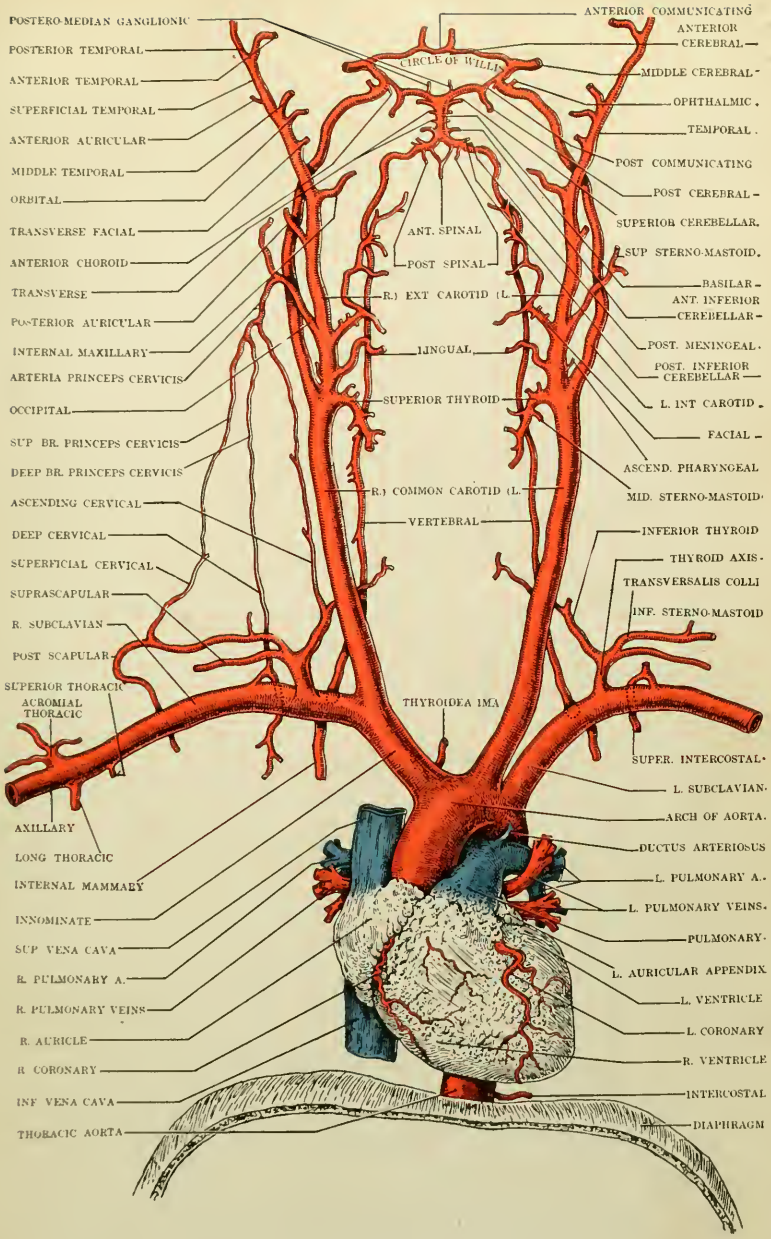

FIG. 81.

The arteries of the head and neck.

Sphenomaxillary portion:—

Alveolar or posterior dental branch (*a. alveolaris superior posterior*), supplies the upper molar and bicuspid teeth, antrum and gums; its principal branch is the superior dental;

Infraorbital (*a. infraorbitalis*), passes through infraorbital canal to face;

Posterior or descending palatine (*a. palatina descendens*), descends posterior palatine canal and runs forward to foramen of Stenson:

Vidian (*a. canalis pterygoidea*), accompanies the Vidian nerve;

Pterygopalatine, supplies Eustachian tube and pharynx;

Nasal, or sphenopalatine (*a. sphenopalatina*), descends through sphenopalatine foramen to antrum, sphenoidal and ethmoidal cells.

THE INTERNAL CAROTID ARTERY (A. CAROTIS INTERNA)

arises about the upper border of the thyroid cartilage from the bifurcation of the common carotid. It ascends in front of the transverse processes of the cervical vertebræ to the carotid foramen in the petrous portion of the temporal bone to supply the anterior part of the brain, the eye with its appendages, and send branches to the nose and forehead. It gives no branches until it passes through the carotid canal, where, after piercing the dura mater at the anterior clinoid process, it divides into its terminal branches—the anterior and middle cerebral.

Relations.—The internal carotid artery in the neck is in relation in front with the parotid gland, the glossopharyngeal nerve, the styloglossus and stylopharyngeal muscles, and is covered by the skin, superficial and deep fascia; behind it rests upon the rectus capitis anticus major and has resting upon it the superior laryngeal nerve and the sympathetic; internally it is in relation with the pharynx, tonsil, superior laryngeal nerve and descending pharyngeal artery; externally it is in relation with the internal jugular vein and the pneumogastric nerve.

Its branches are, from the petrous portion:—

Tympanic, internal or deep (*ramus caroticotympanicus*), supplies tympanum.

From the cavernous portion:—

Arteriæ receptaculi, supply the Gasserian ganglion and pituitary body;

Anterior meningeal (*a. meningea anterior*), a branch from the preceding vessel to the dura.

Ophthalmic (*a. ophthalmica*) arises about the position of the anterior clinoid process and passes through the optic foramen to the outer side of the optic nerve to reach the orbit. At the inner angle of the eye it divides into its two terminal

branches—the frontal and the nasal. It supplies the muscles and the globe of the eye, and its branches may be divided into two groups—the orbital and the ocular.

Orbital group:—

Lachrymal (*a. lachrimalis*), supplies the lachrymal gland and gives off a malar branch which passes through the malar bone to the temporal fossa;

Supraorbital (*a. supraorbitalis*), passes out through the supraorbital foramen to supply the surrounding structures;

Posterior ethmoidal (*a. ethmoidalis posterior*), descends through the posterior ethmoidal foramen to the cells and adjacent parts;

Anterior ethmoidal (*a. ethmoidalis anterior*), through the anterior ethmoidal foramen to the nose;

Internal palpebral (*aa. palpebrales mediales*), supply the eyelids.

Frontal (*a. frontalis*), supplies the skin and muscles of the forehead.

Nasal (*a. dorsalis nasi*), supplies the lachrymal sac and bridge of the nose.

Ocular group:—

Muscular, supply the muscles of the eye;

Anterior ciliary (*aa. ciliares anteriores*), supply the iris, piercing the sclerotic near the cornea;

Short ciliary (*aa. ciliaris posteriores breves*), supply the choroid and ciliary processes, piercing the sclerotic near the optic nerve;

Long ciliary (*aa. ciliares posteriores longæ*), enter with the short ciliary, but run forward to the iris;

Arteria centralis retinæ, supplies the optic nerve and the retina.

From the cerebral portion:—

Anterior cerebral (*a. cerebri anterior*), supplies the anterior part of the cerebrum, the optic and olfactory nerves, and communicates with its fellow by the anterior communicating;

Middle cerebral, or Sylvian artery (*a. cerebri media*), ascends in the Sylvian fissure, and supplies the middle lobes of the cerebrum;

Posterior communicating (*a. communicans posterior*), runs backward to join the posterior cerebral;

Anterior choroid (*a. choroidea*), supplies the choroid plexus.

THE CIRCLE OF WILLIS (CIRCULUS ARTERIOSUS [WILLISI])

is an anastomotic circle formed at the base of the brain about the pituitary body, between the branches of the internal carotid and the vertebral arteries, for the purpose of equalizing the cerebral circulation. The anterior cerebrals, from the internal carotids, pass forward and are united in front by a short trunk, the anterior communicating. The posterior communicating unites the internal carotid with the posterior cerebral, the latter being the terminal branches of the basilar, which in its turn is formed by the union of the two vertebrals.

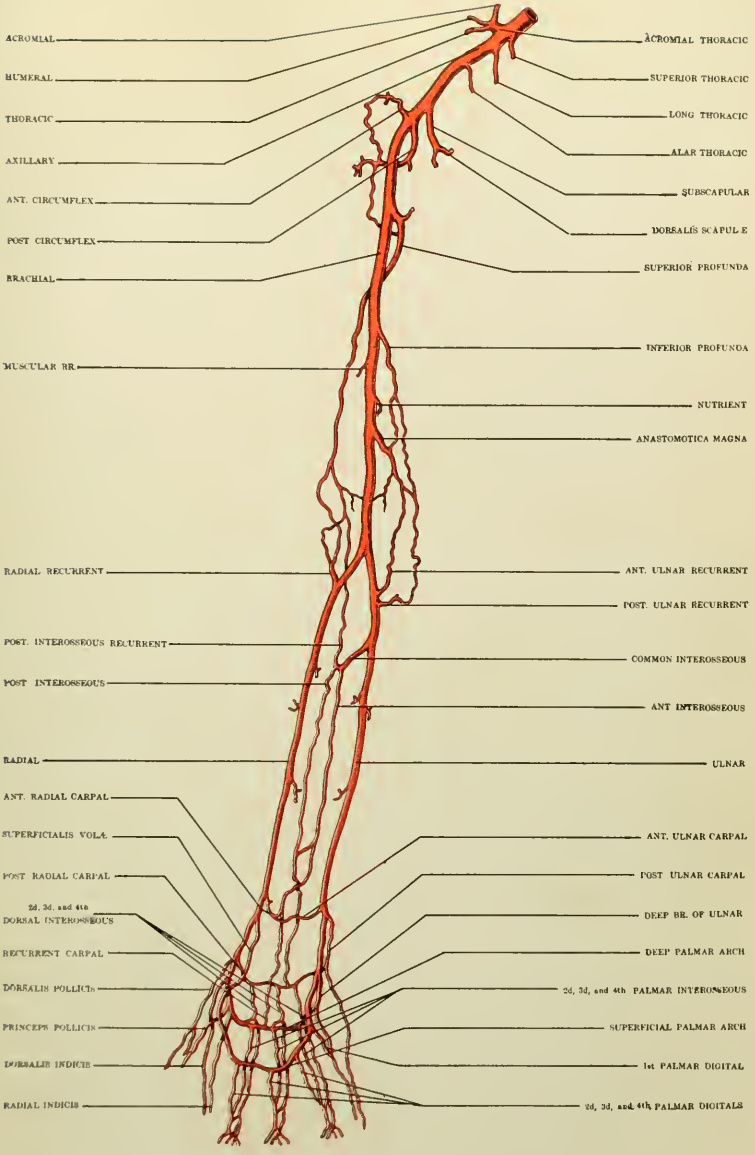

FIG. 82.

The arteries of the upper extremity.

THE SUBCLAVIAN ARTERY (A. SUBCLAVIA)

on the right side arises from the arteria innominata, behind the right sternoclavicular articulation, and on the left side directly from the arch of the aorta. They pass outward to the outer margin of the first rib, where they become the axillary, being divided in their course by the scalenus anticus muscle into three portions—the first portion to the inner side of the muscle, second portion behind it, and the third portion between its outer margin and the lower border of the first rib. The vessels differ only in their first portions, the left ascending more vertically.

Relation.—The first portion of the right subclavian is in relation in front to the internal jugular and vertebral veins, the sternohyoid and sternothyroid and the clavicular portion of the sternomastoid muscles and the pneumogastric, phrenic, and cardiac nerves; behind it is in relation with the longus colli muscle, the transverse process of the first dorsal or seventh cervical vertebræ, the sympathetic nerve, and the recurrent laryngeal nerve beneath with the pleura.

The first portion of the left subclavian artery is in relation in front with the left internal jugular and innominate veins, the left carotid artery, the sternothyroid, sternohyoid, and sternomastoid muscles, the pleura and left lung, the pneumogastric, phrenic and cardiac nerves; behind, with the vertebral column and longus colli muscle, the esophagus, thoracic duct, and the inferior cervical ganglion of the sympathetic; on the inner side with the esophagus, thoracic duct, and trachea, and on the outer side with the pleura. The second portion of the subclavian artery on either side is in relation with the subclavian vein, the scalenus anticus muscle and the phrenic nerve; behind with the middle scalenus muscle and pleura; above by brachial plexus, and below by the pleura. The third portion of the subclavian artery on either side is in relation in front with the external jugular vein and its branches, the clavicle, subclavius muscle and suprascapular artery, the descending branches of the cervical plexus and the cervical fascia; behind with the scalenus medius, above with the omohyoid muscle and the brachial plexus, and below with the first rib.

Its branches are:—

1. Vertebral (*a. vertebralis*).
2. Thyroid axis (*truncus thyrocervicalis*).
3. Inferior thyroid (*a. thyreoidea inferior*).
4. Suprascapular (*a. transversa scapulæ*).
5. Transverse cervical, or transversalis colli (*a. transversa colli*).
6. Internal mammary (*a. mammaria interna*).
7. Superior intercostal (*truncus costocervicalis*).

These branches are all given off from the first portion, except the superior intercostal, which arises on the right side, from the second portion.

1. The vertebral artery (*a. vertebralis*) passes upward, enters the foramen in the transverse process of the sixth cervical vertebra, and ascends through the foramina until it reaches the atlas, when it runs backward, pierces the posterior occipito-atloid ligament and dura mater to enter the skull through the foramen magnum. After entering the cranium it passes forward to the lower border of the pons Varolii where it unites with its fellow of the opposite side to form the basilar artery. Its branches are—

Cervical branches:—

Lateral spinal (*rami spinales*), supply the spinal cord and its membranes, entering the spinal canal through the intervertebral foramina;

Muscular, supply the deep muscles of the neck.

Cranial branches:—

Posterior meningeal (*ramus meningeus*) supply the falx cerebelli;

Anterior spinal (*a. spinalis anterior*), supplies the cord; uniting with branches from the inferior thyroid, intercostals, and lateral sacral, descend to the cauda equina;

Posterior spinal (*a. spinalis posterior*), descends in the same manner as the anterior;

Posterior inferior cerebellar (*a. cerebelli inferior posterior*), supplies the inferior surface of the cerebellum and the choroid plexus of the fourth ventricle.

The branches of the basilar artery (*a. basilaris*) are:—

Transverse (*rami ad pontem*), to the pons Varolii and inferior surface of the cerebellum;

Anterior inferior cerebellar (*a. cerebelli inferior anterior*), a branch of the transverse;

Superior cerebellar (*a. cerebelli superior*), supplies pia mater, pineal gland and velum interpositum.

Posterior cerebral (*a. cerebri posterior*), to posterior lobes of cerebrum and choroid plexus.

2. The thyroid axis (*truncus thyreocervicalis*) consists of three branches—the inferior thyroid, the suprascapular and the transversalis colli.

3. The inferior thyroid artery (*a. thyreoidea inferior*) is distributed to the thyroid gland, its branches being:—

Inferior laryngeal (*a. laryngea inferior*), to muscles and mucous membrane of larynx;

Tracheal (*rami tracheales*), to the trachea, anastomosing with the bronchial arteries;

Esophageal (*rami œsophagei*), to esophagus;

Ascending cervical (*a. cervicalis ascendens*), supplies the spinal cord and membranes, vertebræ, and muscles of neighborhood;

Muscular (*rami musculares*), to inferior constrictor of pharynx, scalenus anticus, and other muscles.

4. The suprascapular artery—transversalis humeri (*a. transversa scapulæ*) passes beneath the posterior belly of the omohyoid to the upper border of the scapula, passing over the transverse ligament of the scapula to the supraspinous fossa, where it is distributed to the supraspinatus, sternomastoid, and other muscles, and by means of the supra-acromial branch to the skin over the acromion, anastomosing with the posterior circumflex and acromial thoracic arteries.

In about 50 per cent. of bodies this artery will be found to arise from the third portion of the subclavian.

5. The transversalis colli (*a. transversa colli*) passes outward to the trapezius muscle, where it divides into

The (*a*) superficial cervical (*ramus ascendens*), an important branch passing beneath the trapezius to anastomose with the superficial branch of the arteria princeps cervicis;

And the (*b*) superficial posterior scapular (*ramus descendens*), the larger passing to and along the upper and posterior border of the scapula, beneath the levator anguli scapulæ, rhomboidei, latissimus dorsi and trapezius, to anastomose with the subscapular, suprascapular, and posterior branches of the intercostals.

6. The internal mammary (*a. mammaria interna*) arises from the subclavian, opposite the thyroid axis, and descends upon the internal surfaces of the costal cartilages to a point in the sixth intercostal space, where it divides into the musculophrenic and the superior epigastric. Its branches are:—

Comes nervi phrenici—superior phrenic (*a. pericardiacophrenica*), supplies diaphragm, passing between the pleura and pericardium;

Mediastinal (*aa. mediastinales anteriores*), to the anterior mediastinum;

Pericardiac, to upper portion of pericardium;

Sternal (*rami sternales*), to posterior surface of sternum;

Anterior intercostal (*rami intercostales*), to fifth or sixth upper intercostal spaces;

Perforating (*rami perforantes*), perforate the intercostal spaces to supply the mammary gland;

Musculophrenic (*a. musculophrenica*), supplies lower part of pericardium, diaphragm, and upper part of abdominal muscles;

Superior epigastric (*a. epigastrica superior*), supplies the rectus muscle, and anastomoses with the deep epigastric from the external iliac.

7. The superior intercostal artery (*truncus costocervicalis*) arises from the subclavian, behind the anterior scalenus muscle, and descends behind the pleura and anastomoses with the first aortic intercostal artery. It gives off branches in the intercostal

spaces to the spinal cord and its membranes and the posterior spinal muscles. Its principal branch is the deep cervical (profunda cervicis).

THE AXILLARY ARTERY (A. AXILLARIS)

is the continuation of the subclavian, extending outward from the lower edge of the first rib to the lower margin of latissimus dorsi and teres major muscles, where it becomes the brachial. It is divided by the pectoralis minor into three parts—the first portion above, the second portion behind, and the third portion below that muscle. It passes through the space known as the axilla (*vide* Regions).

Relations.—First portion: The first portion of the axillary is in relation in front with the subclavius and pectoralis major muscles, costocoracoid membrane, acromial thoracic and cephalic veins and the external anterior thoracic nerve; the axillary vein to its inner side, the brachial plexus to its outer side, and the posterior thoracic nerve and serratus magnus behind. Second portion: The relations of the second portion are much the same as the first, with the addition of the pectoralis minor in front and the division of the brachial plexus surrounding the vessels. Third portion: The third portion is in relation in front with the inner head of the median nerve and the pectoralis major muscle; to the inner side with the axillary vein, internal cutaneous and ulnar nerves; to the outer side, the median and musculocutaneous nerves and coracobrachialis muscle; and, behind, the circumflex and musculospiral nerves and the subscapularis, latissimus dorsi and teres major muscles.

Its branches are:—

Superior thoracic (*a. thoracalis suprema*), supplies the pectoralis major and minor muscles;

Acromial thoracic (*a. thoracoacromialis*), gives off three branches—acromial, thoracic and descending, supplying the pectoralis major and minor, serratus and deltoid;

Long thoracic (*a. thoracalis lateralis*), follows the lower border of the pectoralis minor to supply the serratus, pectoralis major and minor, and mammary glands;

Alar thoracic supplies the axillary glands;

Subscapular (*a. subscapularis*), arises from the axillary artery about the level of the lower border of the subscapularis muscle. It passes backward and downward to the inferior dorsum of the scapula. Its branches anastomose with the posterior scapular and the suprascapular. They are:—

Subscapular (*a. subscapularis*), supplies the subscapularis muscle;

Dorsalis scapulæ (*a. circumflexa scapulæ*), is distributed to the infraspinous fossa, anastomosing with the posterior scapular and suprascapular arteries;

Median branch, descends the axillary border of the scapula to supply teres muscles.

Posterior circumflex (*a. circumflexa humeri posterior*), encircles the neck of the humerus to supply the shoulder joint and the deltoid muscle;

Anterior circumflex (*a. circumflexa humeri anterior*), descends beneath the short head of biceps and coracobrachialis muscles to supply the shoulder joint.

THE BRACHIAL ARTERY (A. BRACHIALIS)

commences at the lower border of the latissimus dorsi and teres major muscles and descends on the front and inner aspect of the arm to half an inch below the middle of a line drawn through the condyles of the humerus, where it terminates by dividing into the radial and ulnar artery.

Relations.—It is covered in front by the skin, superficial and deep fascia, and is crossed by the median nerve; behind it rests upon the triceps, brachialis anticus and coracobrachialis muscles;

And is in relation with the musculospiral nerve and the superior profunda artery; to the outer side above it is in relation with the biceps and coracobrachialis muscles and the median nerve; and on the inner side with the internal cutaneous and ulnar nerve, and the basilic vein and median nerve below.

At the bend of the elbow it is crossed by the bicipital fascia. Its branches are:—

Superior profunda (*a. profunda brachii*), accompanies the musculospiral nerve to supply the triceps, deltoid and coracobrachialis muscles;

Nutrient artery (*a. nutricia humeri*), supplies the shaft of the humerus;

Inferior profunda (*a. collateralis ulnaris superior*), accompanies the ulnar nerve to supply the triceps muscle and structures about the internal condyle;

Anastomotica magna (*a. collateralis ulnaris inferior*), forms an anastomosis on the lower posterior aspect of the arm, with branches from the inferior profunda and recurrent ulnar vessels. It supplies the triceps;

Muscular (*rami musculares*), supply the muscles on the anterior aspect of the arm.

THE RADIAL ARTERY (A. RADIALIS)

descends from the bifurcation of the brachial below the bend of the elbow to the wrist, where it winds around the carpus

beneath the extensor tendons of the thumb, passes between the two heads of the first dorsal interosseous muscle and into the palm of the hand, where it forms the deep palmar arch, anastomosing with the deep branch of the ulnar artery. Its branches are, in the forearm:—

Radial recurrent (*a. recurrens radialis*), supplies the brachialis anticus and supinator longus and brevis;

Muscular (*rami musculares*), supply the radial muscles;

Superficialis volæ (*ramus volaris superficialis*), supplies the muscles of the thumb and anastomoses with the ulnar to form the superficial palmar arch;

Anterior radial carpal (*ramus carpeus volaris*), supplies the wrist-joint.

In the wrist:—

Posterior radial carpal (*ramus carpeus dorsalis*), supplies the wrist-joint, forms the posterior carpal arch, and gives off the dorsal interosseous arteries;

Metacarpal, is called the first dorsal interosseous; it supplies the index and middle finger;

Dorsales pollicis, supply the back of the thumb;

Dorsalis indicis, supplies the outer and dorsal side of the index finger.

In the hand:—

Princeps pollicis (*a. princeps pollicis*), supplies the sides of the palmar aspect of the thumb;

Radialis indicis (*a. volaris indicis radialis*), supplies the radial side of index finger;

Perforating (*rami perforantes*), anastomose with dorsal interosseous arteries;

Interosseous (*aa. metacarpeæ volares*), anastomose with digital branches of superficial palmar arch.

THE ULNAR ARTERY (A. ULNARIS)

descends from the bifurcation of the brachial below the bend of the elbow to the ulnar border of the wrist, passing beneath all the superficial flexors excepting the flexor carpi ulnaris, crosses over the annular ligament at the radial side of pisiform bone, and enters the palm to form the superficial palmar arch, anastomosing with the superficialis volæ from the radial. Its branches are, in the forearm:—

Anterior ulnar recurrent (*a. recurrentes ulnaris anterior*), supplies the pronator radii teres and brachialis anticus muscles;

Posterior ulnar recurrent (*a. recurrentes ulnaris posterior*), supplies the joint and neighboring muscles, and anastomoses freely;

Interosseous (*a. interossea communis*), passes backward to the upper border of the interosseous membrane, where it divides into

Anterior branch (*a. interossea volaris*), descends on the front of the interosseous membrane;

Posterior (*a. interossea dorsalis*), descends on the posterior aspect of the foramen and gives off a recurrent interosseous branch;

Muscular (*rami musculares*), to muscles on ulnar side of forearm.

In the wrist:—

Anterior carpal (*ramus carpeus volaris*), supplies the front of wrist and anastomoses with the carpal branches of radial artery;

Posterior carpal (*ramus carpeus dorsalis*), passes beneath the tendon of flexor carpi ulnaris and forms posterior carpal branch.

In the hand:—

Deep, or communicating branch (*ramus volaris profundus*), passes between the flexor and abductor minimi digiti to form part of deep palmar arch;

Digital, supply the ulnar side of the little finger and adjoining sides of the little, ring, middle and index fingers.

THE DESCENDING AORTA.

The thoracic aorta (*aorta thoracalis*) extends from the lower border of the fifth dorsal vertebra on the left side to about the last dorsal vertebra, where by passing through the aortic opening in the diaphragm it becomes the abdominal aorta.

Relations.—It is in relation in front with the left bronchus, esophagus, pericardium and left pulmonary artery; behind it rests upon the vertebral column and is in relation with the vena azygos minor; on the right side it is in relation with the thoracic duct, the esophagus, at its upper part, and the vena azygos major; on the left side with the left lung, the pleura, and the esophagus below.

The branches of the thoracic aorta are:—

Pericardiac (*rami pericardiaci*), supply the pericardium;

Bronchial (*aa. bronchiales*), two or three in number, supply the bronchi;

Esophageal (*aa. œsophageæ*), supply the esophagus;

Posterior mediastinal (*rami mediastinales*), supply the neighboring pleura and lymphatic glands;

Intercostal (*aa. intercostales*), ten on each side, supply the intercostal spaces. They divide into—anterior branch, to intercostal and pectoral muscles; posterior branch, to spinal column and dorsal muscles.

THE ABDOMINAL AORTA (AORTA ABDOMINALIS)

descends from the last dorsal vertebra at the aortic opening of the diaphragm, to opposite the fourth lumbar vertebra, a little

to the left of the median line, where it divides into the two common iliac arteries.

Relations.—The abdominal aorta is in relation in front with the pancreas, transverse duodenum, stomach, and lesser omentum, the mesentery, splenic vein, left renal vein, celiac, solar and aortic plexuses; behind, it is in relation with the vertebral column, the thoracic duct, the left lumbar veins and the receptaculum chyli; on the right side with the inferior vena cava, vena azygos, thoracic duct, the right crus of the diaphragm above, and the right semilunar ganglion; on the left side with the left semilunar ganglion and the sympathetic nerve.

The branches of the abdominal aorta are:—

Phrenic, two in number, supply the diaphragm;

Celiac axis (*a. cœliaca*), divides into three large branches, the gastric, hepatic and splenic;

1. Gastric, or coronaria ventriculi (*a. gastrica sinistra*), is the smallest, and supplies the lesser curvature of the stomach;

2. Hepatic (*a. hepatica*), enters the transverse fissure of the liver, and divides into two branches to supply the lobes of the liver. It gives off:—

Pyloric (*a. gastrica dextra*), to lesser curvature of stomach;

Gastroduodenalis, which descends behind the pylorus, and divides into

Pancreaticoduodenalis superior branch to supply the pancreas and duodenum;

Gastroepiploica dextra, along the greater curvature of the stomach from right to left.

Cystic (*a. cystica*), supplies the gall-bladder.

3. Splenic (*a. lienalis*), the largest of the three, supplies the spleen and gives off the

(*a*) Pancreatic (*rami pancreatici*)—to the pancreas;

(*b*) Gastroepiploica sinistra, runs from left to right, along the greater curvature, to join the gastroepiploica dextra;

(*c*) Gastric—vasa brevia (*aa. gastricæ brevis*), supply the fundus of the stomach.

Superior mesenteric (*a. mesenterica superior*), supplies the small intestine (except first part of the duodenum) and the large intestine as far as the splenic flexure, and part of the descending colon. It gives off:—

(*a*) Inferior pancreaticoduodenal (*a. pancreaticoduodenalis inferior*), supplies duodenum and pancreas;

(*b*) Vasa intestini tenuis (*aa. intestinales*), supply nearly the whole length of the small intestine (ileum and jejunum);

(*c*) Ileocolic (*a. ileocolica*), descends to the right iliac fossa, between the layers of the mesentery, and divides into two branches;

(*d*) Right colic artery (*colica dextra*), passes to the middle of the ascending colon, to divide into two branches;

(*e*) Middle colic artery (*colica media*), ascends in the layers of the transverse mesocolon, to divide into two branches.

Suprarenal (*a. suparenalis media*), supply the suprarenal bodies;

Renal (*aa. renales*), supply the kidneys, a large trunk on each side springing directly from the aorta;

Spermatic (*aa. spermaticæ internæ*), descend to supply the testicles, and in their passage form one of the constituents of the spermatic cord;

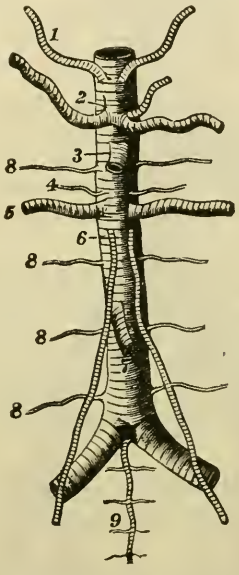

FIG. 83.

Abdominal aorta: 1, phrenic; 2, celiac axis; 3, superior mesenteric; 4, suprarenal; 5, renal; 6, spermatic; 7, inferior mesenteric; 8, lumbar; 9, sacra media.

Inferior mesenteric (*aa. mesenterica inferior*), gives off:—

(*a*) Left colic (*colica sinistra*), supplies the descending colon;

(*b*) Sigmoid (*aa. sigmoideæ*), supplies the sigmoid flexure of the colon;

(*c*) Superior hemorrhoidal (*a. hæmorrhoidalis superior*), the continuation of the inferior mesenteric, supplies the mucous and muscular coats of the rectum on its posterior aspect.

Lumbar branches (*aa. lumbales*), four or five on each side, pass backward and outward and divide into the

Dorsal branches (*rami dorsales*), supply the spinal cord, muscles, and skin of back;

Spinal branches (*rami spinales*), divide within the spinal canal, ascend and descend, and form an arterial network throughout the whole length of the spinal canal;

Abdominal branches (*rami parietales*), supply the abdominal walls;

Middle sacral (*a. sacralis media*), is the continuation of the abdominal aorta, descending in the middle of the sacrum to the upper part of the coccyx.

THE COMMON ILIAC ARTERIES (AA. ILIACÆ COMMUNES)

descend from the bifurcation of the abdominal aorta, opposite the body of the fourth lumbar vertebra, to a point midway between the last lumbar vertebra and the sacrum, where they divide into the external and internal iliac arteries. The right common iliac is a little larger than the left, and passes more obliquely outward.

Relations.—The right common iliac is in relation in front with the small intestine, the ureter, the peritoneum and the sympathetic nerves; behind, with the left and right common iliac veins, and to its outer side it rests upon the psoas muscle, and is in relation with the vena cava and the right common iliac vein. The left common iliac is in relation in front with the ureter, the peritoneum, the superior hemorrhoidal artery and the sympathetic nerves; behind, with the left common iliac vein, to its outer side the psoas muscle, and to its inner side the left common iliac vein.

The common iliac arteries give off a few unimportant branches to the ureters, peritoneum, etc.

THE INTERNAL ILIAC OR HYPOGASTRIC ARTERY (A. HYPOGASTRICA)

is about an inch and a half in length, extending from the bifurcation of the common iliac, about the sacrolumbar junction, to the upper border of the great sacrosciatic foramen, where it divides into the anterior and posterior trunks.

The branches from the anterior trunk are:—

Superior vesical (*a. vesiculis superior*), is the pervious remains of the fetal hypogastric artery. It supplies the apex and body of bladder, ureter and vas deferens;

Middle vesical (*a. vesiculis medialis*), supplies the base of the bladder and part of vesiculæ seminales; it may be given off from the superior vesical;

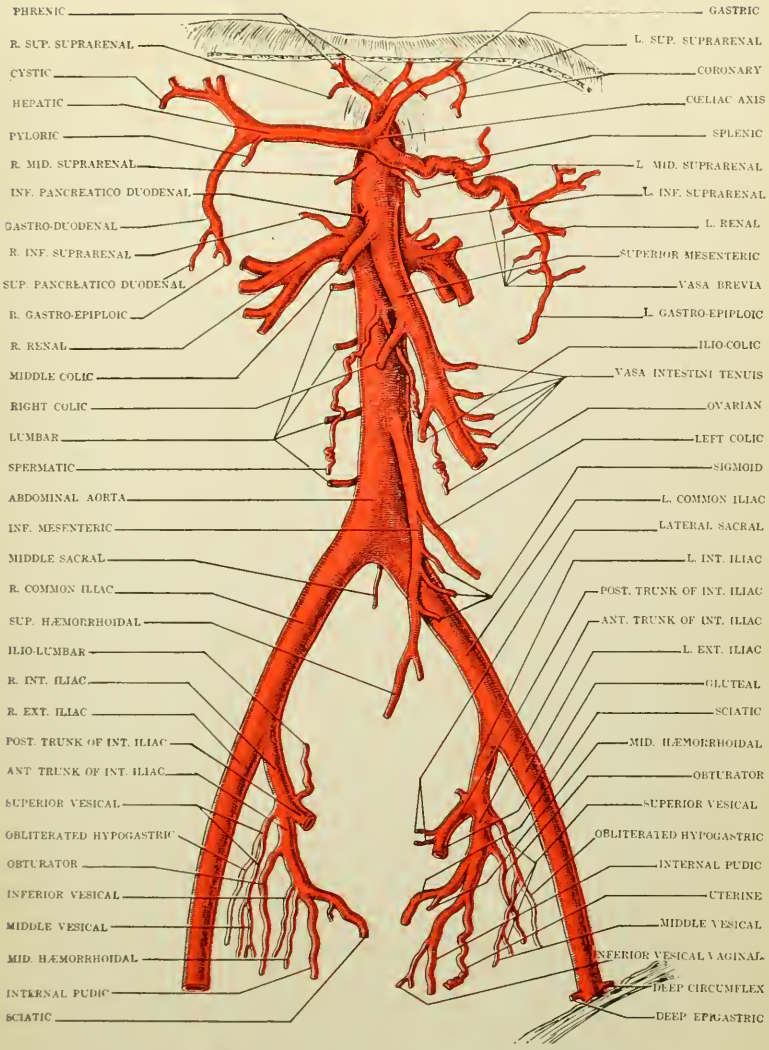

FIG. 84.

The arteries of the trunk.

Inferior vesical (*a. vesicalis inferior*), supplies the prostate gland, base of bladder and vesiculæ seminales;

Middle hemorrhoidal (*a. hæmorrhoidalis media*), supplies part of the rectum;

Obturator (*a. obturatoria*), passes along the side of the pelvis to the obturator foramen, through which it passes. It gives off within the pelvis the iliac (*ramus iliacus*), vesical (*ramus vesicalis*), and pubic (*ramus pubicus*) branch;

Internal pudic (*a. pudenda interna*), supplies the external organs of generation. It passes out of the pelvis through the great sacrosciatic foramen, winds around the ischial spine, and re-enters the pelvis through the lesser sacrosciatic foramen.

It gives off the following branches in the perineum:—

(*a*) Inferior hemorrhoidal (*a. hæmorrhoidalis inferior*), supplies the muscles and skin of the anus;

(*b*) Superficial perineal (*a. perinei*), supplies the erector penis and accelerator urinæ muscles and the scrotum;

(*c*) Transverse perineal, crosses the perineum on the transversus muscle, which, together with the structures between the bulb and anus, it supplies;

(*d*) Bulbourethral, artery of the bulb (*a. bulbi urethræ*), supplies the bulb of the spongy body and Cowper's gland;

(*e*) Cavernous (*a. profunda penis*), supplies the corpus cavernosum, and is one of the terminal branches;

(*f*) Dorsal artery of penis, or clitoris (*a. dorsalis penis*), runs forward on the dorsum and supplies the glans and prepuce.

In the female the internal pudic artery is of smaller size, but its course and distribution is quite analogous to its study in the male subject, *i.e.*, the superficial perineal artery supplies the labia pudendi; the artery of the bulb, the vestibule, and the vaginal erectile tissue, the artery of the corpus cavernosum, the clitoris; the arteria dorsalis clitoridis, the dorsal surface of the clitoris, being distributed to the membranous fold in the glans clitoris, the analogue of the male prepuce.

Sciatic artery supplies the muscles at the back of the pelvis, coccygeus, pyriformis and levator ani, and passes out of the great sacrosciatic foramen to follow the course of the sciatic nerve. Its branches external to the pelvis are:—

Coccygeal, supplies back part of coccyx;

Inferior gluteal (*a. glutæa inferior*), to the gluteus maximus muscle;

Comes nervi ischiadici (*a. comitans n. ischiadici*), runs in the substance of the great sciatic nerve;

Muscular, to the back part of the hip;

Articular, to supply the capsule of the hip-joint.

Uterine (*a. uterina*), is distributed to body of uterus, giving branches to the ureter and bladder;

Vaginal (*a. vaginalis*), supplies the mucous membrane of the vagina, giving branches to the rectum and neck of the bladder. It is analogous to the inferior vesical, in the male.

From the posterior trunk

Iliolumbar (*a. iliolumbalis*) gives off two branches:—

Lumbar (*ramus lumbalis*), supplies quadratus lumborum and psoas muscles;

Iliac (*ramus iliacus*), supplies iliacus, gluteal and abdominal muscles.

Lateral sacral (*a. sacralis lateralis*), are two in number—the superior and inferior, supplying the contents of the sacral canal;

Gluteal (*a. gluteæ superior*), gives a superficial and deep branch to supply the gluteus maximus, medius and minimus muscles.

THE EXTERNAL ILIAC ARTERY (A. ILIACA EXTERNA)

extends from the bifurcation of the common iliac to Poupart's ligament, under which it passes to become the femoral.

Relations.—It is in relation in front with the peritoneum and intestines, circumflex iliac vein, spermatic vessels, genitocrural nerve and the lymphatic vessels and nerves; behind, it rests upon the psoas muscle, and is in relation with the external iliac vein, which, together with the vas deferens, is also in relation to it, on its inner side, beneath Poupart's ligament. On its outer side it is in relation with the psoas magnus and iliac fascia.

Its branches are:—

The deep epigastric (*a. epigastrica inferior*), arises above Poupart's ligament and ascends obliquely inward between the transversalis fascia and peritoneum to the rectus muscle, in which it ascends to anastomose with the termination of the internal mammary artery. It gives off:—

Cremasteric (*a. spermatica externa* [male]; *a. ligamenti teretis uteri* [female]) branch, to supply the cremasteric muscle;

Pubic (*ramus pubicus*), crossing Poupart's ligament to descend to the inner side of the femoral ring, and

Muscular, to supply abdominal muscles and the peritoneum.

The deep circumflex iliac (*a. circumflexa ilium profunda*) ascends outwardly behind Poupart's ligament to the crest of the ilium, where it gives off:—

Muscular branches, to supply the abdominal muscles.

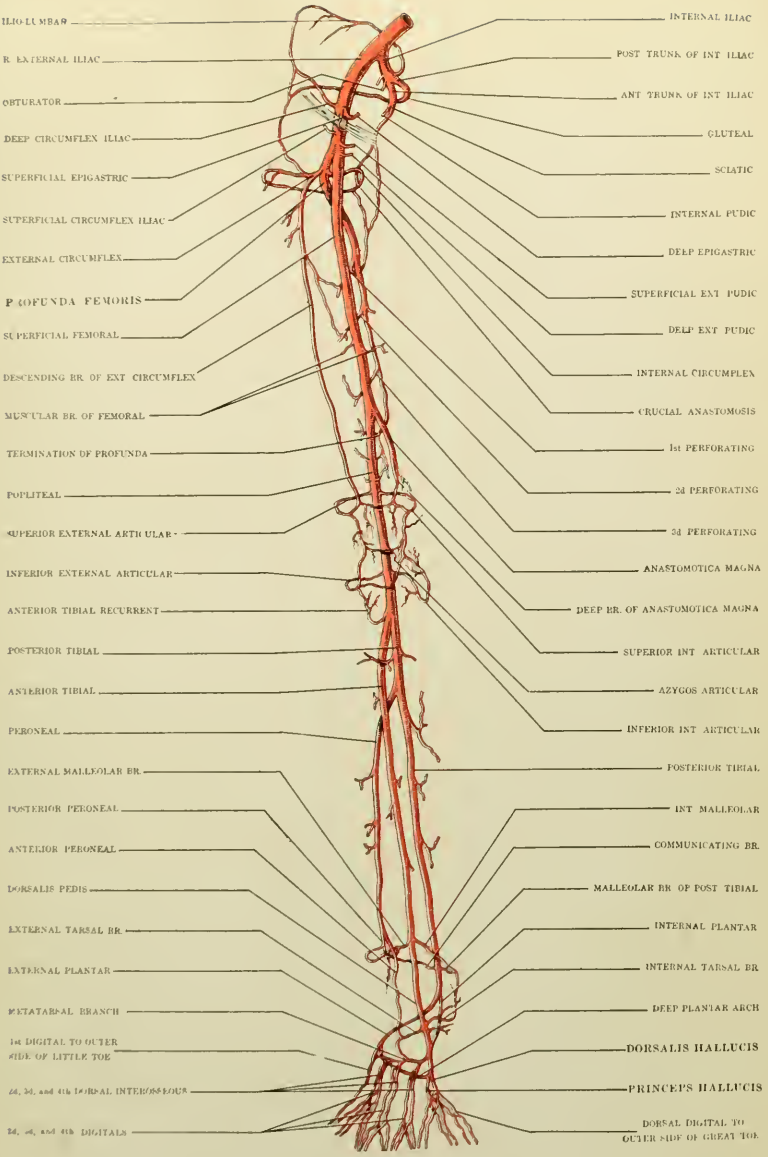

FIG. 85.

The arteries of the lower extremity.

THE FEMORAL ARTERY (A. FEMORALIS)

extends from Poupart's ligament down the inner side of the thigh to the opening in the adductor magnus—Hunter's canal (*canalis adductorius* [*Hunteri*]), where it becomes the popliteal. Its course corresponds to a line drawn from a point midway between the anterior superior spine of the ilium and the symphysis pubis to the inner tuberosity of the internal condyle. In the upper part of its course it is superficial, where it passes through Scarpa's triangle (*trigonum femorale*), but in the lower part it passes backward and becomes very deep. Where it passes under Poupart's ligament the femoral vein is to the inner side, and the anterior crural nerve to the outer side; thus, from within outward, V. A. N.

Relations.—It is in relation in front with the sartorius, the long saphenous nerve, a branch of the anterior crural nerve, and is covered by the fascia lata; behind, it is in relation with the psoas magnus, adductor longus, adductor magnus and pectineus and the profunda vein, and about the middle with the femoral vein; at its inner side it is in relation with the sartorius and adductor longus muscles, and at its upper part with femoral vein; on the outer side, with the vastus internus, and at its lower part, the femoral vein.

The branches of the femoral artery are:—

Superficial epigastric (*a. epigastrica superficialis*), descends through the saphenous opening in the fascia lata, and ascends in abdomen, supplying the skin, inguinal glands and superficial fascia;

Superficial circumflex iliac (*a. circumflexa ilium superficialis*), passes outward to the skin of the groin and over crest of ilium;

Superficial external pudic (*a. pudenda externa superficialis*), supplies the skin on the lower part of the abdomen;

Deep external pudic (*a. pudenda externa profunda*), supplies the scrotum in the male, the labia pudendi in the female;

Profunda femoris, arises about two inches below Poupart's ligament, and passes beneath the adductor longus, giving off the following:—

External circumflex (*a. circumflexa femoris lateralis*), gives off ascending, transverse and descending branches, supplying the muscles on the front of the thigh as low as the knee;

Internal circumflex (*a. circumflexa femoris medialis*), passes internally, supplying the adductor muscles and the hip joint;

Three perforating (*aa. perforans prima, secunda, tertia*), pierce the adductor magnus and brevis, and supply the flexor

muscles of the thigh, and give off the medullary nutrient artery (*a. nutricia femoris*). The vessel terminates by a fourth perforating.

Muscular (*rami musculares*), vary in number, and supply the sartorius and vastus internus;

Anastomotica magna (*a. genu suprema*), gives off two branches—superficial, accompanying the long saphenous nerve, and deep branch, to the inner side of knee, and supplies knee joint.

THE POPLITEAL ARTERY (A. POPLITEA)

descends from the opening in the adductor magnus to the lower border of the popliteus muscle, passing behind the knee joint, where it divides into the anterior and posterior tibial arteries. Its branches are:—

Muscular, gives off two principal branches:—

Superior, to flexors of thigh and vastus externus muscles;

Inferior, or sural (*aa. surales*), to heads of gastrocnemius and plantaris.

Cutaneous, supplies the skin of the calf;

Superior external articular (*a. genu superior lateralis*), supplies knee joint and vastus externus;

Superior internal articular (*a. genu superior medialis*), supplies knee joint and vastus internus;

Azygos articular (*a. genu media*), supplies the synovial membrane and ligaments of joints;

Inferior external articular (*a. genu inferior lateralis*), supplies knee joint and fibular head;

Inferior internal articular (*a. genu inferior medialis*), supplies knee joint and head of tibia.

THE ANTERIOR TIBIAL ARTERY (A. TIBIALIS ANTERIOR)

descends from the bifurcation of the popliteal at the lower border of the popliteus muscle; passes over the upper border of the interosseous membrane, between the two heads of the tibialis posticus, and descends on the anterior part of the interosseous membrane and lower part of the tibia to the ankle joint, where it terminates as the dorsalis pedis.

In the upper third of its course it lies between the tibialis anticus and extensor longus digitorum, resting upon the interosseous membrane, in the middle third, between the tibialis anticus and extensor proprius pollicis, and at the lower third it becomes more superficial, and lies between the extensor proprius and extensor longus digitorum tendons.

Its branches are:—

Anterior recurrent tibial (*a. recurrens tibialis anterior*), ascends to supply the front and sides of the knee joint and anastomose with the anastomotica magna and popliteal;

Posterior recurrent tibial (*a. recurrens tibialis posterior*), is an inconstant artery that is given off from the anterior tibial, before the latter passes through the interosseous space. It supplies the popliteus muscle, and anastomoses with some of the articular filaments of the popliteal artery;

Muscular, supplying the muscles and skin of the neighboring parts;

Internal malleolar (*a. malleolaris anterior medialis*), arises two inches above the ankle joint, and supplies it and the structures on its inner side;

External malleolar (*a. malleolaris anterior lateralis*), supplies the outer side of the ankle.

The dorsalis pedis artery (*a. dorsalis pedis*) extends from the bend of the ankle, where it is continuous with the anterior tibial, to the first interosseous space, where it divides into the dorsalis hallucis and the communicating. Its branches are:—

Tarsal (*a. tarsea lateralis*), supplies the tarsal articulations and the extensor brevis digitorum muscle;

Metatarsal (*a. arcuata*), passes to the outer side of the foot, and gives off three interosseous branches to supply the adjacent sides of the toes;

Dorsalis pollicis (*a. dorsalis hallucis*), passes along the outer border of the great toe, supplying it;

Communicating (*ramus plantaris profundus*), descends between the two heads of the first dorsal interosseous to complete, with the external plantar, the plantar arch;

Interosseous, branches of the tarsal branch, three in number.

THE POSTERIOR TIBIAL ARTERY (A. TIBIALIS POSTERIOR)

begins at the lower border of the popliteus muscle and descends along the posterior and tibial side of the leg to the space between the heel and the inner ankle, where it passes beneath the abductor pollicis and divides into the internal and external plantar arteries.

Relations.—In the upper part of its course it lies deeply, being covered by the gastrocnemius and soleus muscle, but in the lower part it becomes more superficial, being covered only by the skin and the fascia.

Its branches are:—

Peroneal (*a. peronæa*), descends the inner border of the fibula, supplying the muscles and skin of that region and the back of the ankle;

Anterior peroneal (*ramus perforans*), a branch of the peroneal, pierces the lower part of the interosseous membrane to supply the dorsum and outer side of the tarsus;

Muscular, supplies the posterior muscles;

Nutrient (*a. nutritia fibulæ*), supplies the tibia, being the largest nutrient artery in the body;

Communicating (*ramus communicans*), passes to the peroneal;

Internal calcanean (*rami calcanei mediales*), supplies the inner side of the sole and heel.

The internal plantar artery (*a. plantaris medialis*), the smaller of the two, passes along the inner side of the foot between the abductor pollicis and the flexor brevis digitorum to the inner border of the great toe, anastomosing with its digital branch.

The external plantar artery (*a. plantaris lateralis*) passes across the foot to the base of the fifth metatarsal bone, where it turns inward and crosses the foot to the first interosseous space, where it anastomoses with the communicating branch of the dorsalis pedis to form the plantar arch. Its branches are:—

Posterior perforating (*rami perforantes posteriores*), are three branches which pass between the heads of the dorsal interossei muscles;

Digital branches (*aa. metatarseæ plantares*)—these are four branches which supply the adjacent sides of the three outer toes, and the outer sides of the second and little toes.

TABLE OF THE ARTERIAL SYSTEM.

Aorta.

- Arch of aorta,
  - Right coronary.
  - Left coronary.
  - Innominate,
    - Right common carotid,
      - External carotid,
      - Internal carotid.
    - Right subclavian.
  - Left common carotid,
    - External carotid,
    - Internal carotid.
  - Left subclavian.

- External carotid,
  - Superior thyroid,
    - Hyoid,
    - Superficial descending branch,
    - Superior laryngeal,
    - Cricothyroid.
  - Lingual,
    - Hyoid,
    - Dorsalis linguæ,
    - Sublingual,
    - Ranine.
  - Facial,
    - In the neck,
      - Inferior or ascending palatine,
      - tonsillar,
      - submaxillary,
      - submental,
      - muscular.
    - On the face,
      - Muscular,
      - inferior labial,
      - inferior coronary,
      - superior coronary,
      - lateralis nasi,
      - angular.
  - Occipital,
    - Muscular,
    - Sternomastoid,
    - Auricular,
    - Meningeal,
    - Arteria princeps cervicis,
    - Cranial branches.
- External carotid continued,
  - Posterior auricular,
    - Stylomastoid,
    - Auricular,
    - Muscular,
    - Glandular.
  - Ascending pharyngeal, — Pharyngeal, external meningeal.
  - Temporal,
    - Transverse facial,
    - Middle temporal,
    - Auricular,
    - Anterior temporal,
    - Posterior temporal.
  - Internal maxillary,
    - Maxillary portion,
      - Tympanic (anterior),
      - Deep auricular,
      - Middle meningeal,
      - Small meningeal,
      - Inferior dental.
    - Pterygoid portion,
      - Deep temporal,
      - Pterygoid,
      - Masseteric,
      - Buccal.
    - Spheno-maxillary portion,
      - Alveolar,
      - Infraorbital,
      - Post. or ascending palatine,
      - Vidian,
      - Pterygopalatine,
      - Nasal or sphenopalatal.

- **Internal carotid,**
  - Petrous portion, } Tympanic (internal, or deep).
  - Cavernous portion,
    - Arteriæ receptaculi,
    - Anterior meningeal.
    - Ophthalmic,
      - Orbital group,
        - Lachrymal,
        - Supraorbital,
        - Post. ethmoidal,
        - Ant. ethmoidal,
        - Palpebral,
        - Frontal,
        - Nasal.
      - Ocular group,
        - Muscular,
        - Ant. ciliary,
        - Short ciliary,
        - Long ciliary,
        - Arteria centralis retinæ.
  - Cerebral portion,
    - Anterior cerebral,
    - Middle cerebral,
    - Anterior choroid,
    - Posterior communicating.
- **Subclavian,**
  - Vertebral,
    - *Cervical Branches,*
      - Lateral spinal,
      - Muscular.
    - *Cranial Branches,*
      - Posterior meningeal,
      - Anterior spinal,
      - Posterior spinal.
    - Basilar,
      - Transverse,
      - Anterior inferior cerebellar,
      - Sup. cerebellar,
      - Post. cerebral.
  - Thyroid axis,
    - Inferior thyroid,
      - Laryngeal,
      - Tracheal,
      - Esophageal,
      - Ascend. cervical,
      - Muscular.
    - Superior scapular, (Transversalis humeri),
      - Muscular,
      - Supraacromial,
    - Transversalis colli,
      - Superfic. cervical,
      - Post. scapular.
  - Internal mammary,
    - Comes nervi phrenici (superior phrenic),
    - Mediastinal,
    - Pericardiac,
    - Sternal,
    - Anterior intercostal,
    - Perforating,
    - Musculophrenic,
    - Superior epigastric.
  - Superior intercostal } Deep cervical branch (profunda cervicis).

- **Axillary,**
  - Acromiothoracic,
  - Superior thoracic,
  - Thoracica longa,
  - Thoracica alaris.
  - Subscapular,
    - Dorsalis scapulæ,
    - Median branch.
  - Anterior circumflex,
  - Posterior circumflex.

- **Brachial,**
  - Superior profunda,
  - Nutrient artery,
  - Inferior profunda,
  - Anastomotica magna,
  - Muscular,
  - Radial,
  - Ulnar.

- **Radial,**
  - In foramen,
    - Radial recurrent,
    - Muscular,
    - Superficialis volæ,
    - Anterior carpal.
  - In the wrist,
    - Posterior carpal,
    - Metacarpal,
    - Dorsalis pollicis,
    - Dorsalis indicis.
  - In the hand,
    - Princeps pollicis,
    - Radialis indicis,
    - Perforating,
    - Interosseous.

- **Ulnar.**
  - In the forearm,
    - Anterior ulnar recurrent,
    - Posterior ulnar recurrent,
    - Interosseous,
    - Muscular.
  - In the wrist,
    - Anterior carpal,
    - Posterior carpal.
  - In the hand,
    - Deep, or communicating branch,
    - Digital.

Descending Aorta.

- **Thoracic aorta,**
  - Pericardiac,
  - Bronchial,
  - Esophageal,
  - Posterior mediastinal,
  - Intercostal.

- **Abdominal aorta**
  - Two phrenic.
  - **Celiac axis,**
    - Gastric.
    - **Hepatic,**
      - Pyloric.
      - **Gastro-duodenalis,**
        - Pancreatico-duodenalis superior,
        - Gastro-epiploica dextra.
      - Cystic.
    - **Splenic,**
      - Pancreatic,
      - Gastroepiploica sinistra,
      - Gastric (vasa brevia).
  - **Superior mesenteric, Suprarenal, Renal,**
    - Pancreaticoduodenalis inferior,
    - Vasa intestinalis tenuis,
    - Ileocolic,
    - Colica dextra,
    - Colica media.
  - Spermatic.
  - **Inferior mesenteric,**
    - Colica sinistra,
    - Sigmoid,
    - Superior hemorrhoidal.
  - Lumbar (four or five branches),
  - Dorsal branch,
  - Spinal branch,
  - Abdominal branches,
  - Middle sacral,

- Common iliac,
  - Branches to ureter, peritoneum etc.
  - Internal iliac, (Bifurcation.)
    - Anterior trunk,
      - Superior vesical,
      - Middle vesical,
      - Inferior vesical,
      - Middle hemorrhoidal.
      - Obturator,
        - Within pelvis,
          - Iliac,
          - Vesical,
          - Pubic.
        - Without pelvis,
          - External and internal branches.
      - Internal pudic,
        - Inferior hemorrhoidal,
        - Superficial perineal,
        - Transverse perineal,
        - Bulbourethral,
        - Cavernous,
        - Dorsal art'y of the penis.
      - Sciatic,
        - Coccygeal,
        - Inferior gluteal,
        - Comitans nervi ischiadici,
        - Muscular,
        - Articular.
      - In the female,
        - Uterine,
        - Vaginal.
    - Posterior trunk,
      - Iliolumbar,
      - Lateral sacral,
      - Gluteal.
  - External iliac,
    - Deep epigastric
      - Cremasteric,
      - Pubic,
      - Muscular.
    - Deep circumflex iliac,
      - Muscular branches.
- Femoral (continuation),
  - Superficial epigastric,
  - Superficial circumflex iliac,
  - Superficial external pudic,
  - Deep external pudic.
  - Profunda,
    - External circumflex,
    - Internal circumflex,
    - Three perforating.
  - Muscular,
  - Anastomotica magna.
  - Popliteal (continuation).

- **Popliteal,**
  - Muscular, { Superior, Inferior.
  - Cutaneous,
  - Superior external articular,
  - Superior internal articular,
  - Azygos articular,
  - Inferior external articular,
  - Inferior internal articular,
  - Anterior tibial, } Bifurcation.
  - Posterior tibial, }
- **Anterior tibial,**
  - Recurrent tibial,
  - Muscular,
  - Internal malleolar,
  - External malleolar.
  - Dorsalis pedis (continuation),
    - Tarsal, } Three
    - Metatarsal, } interosseous.
    - Dorsalis pollicis or hallucis,
    - Communicating,
    - Interosseous.
- **Posterior tibial,**
  - Peroneal, Anterior peroneal.
  - Muscular,
  - Nutrient,
  - Communicating,
  - Internal calcanean,
  - Internal plantar, } Bifurcation.
  - External plantar, }
- **Plantar arch (from external plantar),**
  - Three posterior perforating,
  - Four digital.

Pulmonary Artery (*a. pulmonalis*).—The pulmonary artery carries venous blood from the right ventricle to the lungs. It is about two inches in length, passes upward and backward to the left side to the under surface of the transverse portion of the arch of the aorta, where it divides into the right and left pulmonary arteries. It is attached to the under portion of the arch by a fibrous cord, the remains of the ductus arteriosus of fetal life (*ligamentum arteriosum*). The right pulmonary artery (*ramus dexter a. pulmonalis*) is larger and longer than the left (*ramus sinister a. pulmonalis*), and passes behind the ascending aorta and superior vena cava to the root of the right lung, where it divides into two branches. The left pulmonary artery passes in front of the descending aorta and left bronchus to the root of the left lung, where it divides into two branches.

THE VENOUS SYSTEM.

The venous system, like the arterial, consists of two distinct sets, the *systemic* and *pulmonary*. It is composed of seven (7) main trunks and their branches:—

Systemic.	*Pulmonary.*
1. Coronary vein;	Four pulmonary veins.
2. Superior vena cava;	
3. Inferior vena cava.	

The systemic veins return the venous blood from the body, head and extremities to the right auricle.

The portal vein, with its branches and capillaries, is an appendage to the systemic set, collecting the venous blood from the organs of digestion, *i.e.*, stomach, intestines and the pancreas; and also from the spleen, and carrying it to the liver, where it breaks into capillaries, and finally reaches the inferior vena cava by means of the hepatic veins.

The pulmonary veins (*v. pulmonales*) are peculiar in carrying arterial blood from the lungs to the left auricle.

Systemic Veins.—The coronary sinus (*sinus coronarius*) returns all the blood from the substance of the heart, except that returned directly from the walls of the right auricle by the vena Thebesii (*venæ cordis minimæ*). It is a dilatation of the great cardiac vein, about one inch in length, situated in the posterior part of the left auriculoventricular groove. It opens into the right auricle, its orifice being protected by the coronary valves, and receives the following:—

Great cardiac, or left coronary vein (*v. cordis magna*);
Anterior cardiac (*vv. cordis anteriores*);
Middle cardiac or posterior (*v. cordis media*);
Right cardiac or small coronary vein (*v. cordis parva*);
Left cardiac vein (*v. posterior ventriculi sinistri*);
Oblique vein of Marshall (*v. obliqua atrii sinistri*).

The superior vena cava (*v. cava superior*) is a short trunk formed by the union of the right and left innominate veins. It receives the vena azygos major (*v. azygos*), has no valves, and is smaller in size than the aorta. It ends in the right auricle, receiving the blood from the whole upper half of the body and the right lymphatic and thoracic ducts. The left innominate (*v. anonyma sinistra*) passes to join the superior cava in front of the great arteries of the arch. The inferior thyroid, the internal mammary and vertebral veins follow closely the courses of the corresponding arteries, and terminate in the innominate vein.

The internal jugular vein (*v. jugularis interna*) is formed by the lateral and the superior petrosal sinuses, descends at the outer side of the common carotid behind the anterior border of the sternomastoid muscle, and joins the subclavian vein to form the innominate. At its junction with the subclavian the left internal jugular vein receives the thoracic duct and the right internal jugular vein the right lymphatic duct.

The Sinuses of the Dura Mater (*sinus duræ matris*).—These are venous channels analogous to veins between the layers of the dura mater. They are destitute of valves, follow no vessels, and their inner coat is continuous with the lining membrane of the veins. They are divided into two sets; those at the back and upper part of the skull are:—

Superior longitudinal,	Lateral sinuses (2),
Inferior longitudinal,	Occipital sinus.
Straight sinus,	

And those of the base:—

Cavernous (2),	Superior petrosal (2),
Circular,	Transverse (anterior occipital, Leidy).
Inferior petrosal (2),	

The superior longitudinal sinus (*sinus sagittalis superior*) arises at the foramen cecum, passes backward along the margin of the falx cerebri to the crucial ridge of the occipital bone, where it terminates in the torcular Herophili or confluence of the sinuses.

The inferior longitudinal sinus (*sinus sagittalis inferior*) passes in the free margin of the falx cerebri.

The straight sinus (*sinus rectus*) passes backward from the junction of the tentorium with the falx cerebri to enter the confluence of the sinuses.

The lateral sinuses (*sinus transversus*) pass horizontally outward from the torcular Herophili, along the temporal bone to the jugular foramen, where they terminate in the internal jugular vein.

The occipital sinus (*sinus occipitalis*), the smallest of all the sinuses, commences at the margin of the foramen magnum on either side and passes backward to the torcular Herophili.

The cavernous sinuses (*sinus cavernosus*) pass from the sphenoidal fissure along either side of the sella turcica to the apex of the petrous portion of the temporal bone, where they join the petrosal sinuses. They are crossed by fibrous bands or offsets of the dura mater, and inclose the pathetic, motor oculi,

abducens and ophthalmic nerves, and the internal carotid artery, from which they are separated by the lining membrane.

The circular sinus (*sinus circularis*) is formed by two small vessels (*sinus intercavernous anterior et sinus intercavernous posterior*) passing in front of and behind the pituitary body, and connecting the cavernous sinuses.

The inferior petrosal sinus (*sinus petrosus inferior*), on each side, runs in a groove between the petrous portion of the temporal bone and the basilar portion of the occipital, connecting the cavernous sinuses with the lateral sinuses.

The superior petrosal sinus (*sinus petrosus superior*), on each side, passes along the upper border of the petrous portion of the temporal bone, connecting the cavernous with the lateral sinuses above.

The transverse or basilar (*plexus basilaris*) is a small, straight sinus, connecting the inferior petrosal and cavernous sinuses.

Sphenoparietal sinus (*sinus sphenoparietalis*) runs in a groove on the under surface of the lesser wing of the sphenoid. It takes origin from the middle meningeal veins, runs inward, passes through a fold of dura mater, and usually receives the anterior temporal veins from the diploë.

Cerebral Veins (*venæ cerebri*).—The cerebral veins consist of two sets—the superficial, on the surface, and the deep, within the substance. They include:—

Superficial (*venæ cerebri externa*)—

Superior cerebral veins (*vv. cerebri superiores*),

Inferior cerebral veins (*vv. cerebri inferiores*).

Deep—

Ventricular veins, or venæ Galeni (*vv. Galeni; vv. cerebri internæ*),

Veni corporis striati and choroid vein (*v. choroidea*).

The *cerebellar veins* consist of the superior superficial cerebellar veins (*vv. cerebelli superiores*), and the inferior superficial cerebellar veins (*vv. cerebelli inferiores*); blood is brought from the interior to these superficial veins through the deep cerebellar veins.

Diploic and Meningeal Veins.—The diploic veins (*venæ diploicæ*), five in number,—frontal (*v. diploica frontalis*), anterior temporal (*v. diploica temporalis anterior*), posterior temporal (*v. diploica temporalis posterior*), occipital (*v. diploica occipitalis superior*)—communicate with the sinuses of the brain and with the veins of the dura mater, the scalp and orbit.

The meningeal veins (*vv. meningeæ*) follow the course of the corresponding arteries, two accompanying each vessel through its course, and open into the sinuses of the dura mater.

The *great meningeal veins* terminate either in the cavernous sinuses or by emptying into the internal maxillary vein.

The ophthalmic superior vein (*v. ophthalmica superior*) commences at the internal canthus of the eye in an anastomosis with the facial, passes backward along the inner part of the orbit, through the sphenoidal fissure, to empty into the cavernous sinuses.

The inferior ophthalmic vein (*v. ophthalmica inferior*) arises from the veins of the eyelids and the lachrymal sac. It runs backward along the floor of the orbit and joins the superior to form a common trunk, or else it enters the cavernous sinus by a single opening.

The external jugular vein (*v. jugularis externa*), smaller than the internal jugular, is formed by the union of the posterior auricular with the temporomaxillary veins; or it may be formed by union with the facial. It descends beneath the platysma muscle from the angle of the jaw to the middle of the clavicle, where it terminates by emptying into the subclavian. It receives the following veins:—

Anterior jugular,	Suprascapular,
Posterior jugular,	Transverse cervical.

The anterior facial vein (*v. facialis anterior*) commences as the angular at the internal canthus of the eye, where it anastomoses with the ophthalmic vein, and receives the frontal vein. About the angle of the jaw it usually ends in the internal jugular, but sometimes empties into the external jugular or unites with the temporomaxillary (*v. facialis posterior*), to form the common facial vein.

The common facial vein (*v. facialis communis*), formed by the union of anterior facial and the anterior division of the temporomaxillary vein, runs backward beneath the sternomastoid muscle, crosses the external carotid artery, and empties into the internal jugular. It receives:—

Supraorbital (*v. supraorbitalis*) and superior palpebral,	Labial,
Nasal veins,	Submental,
Inferior palpebral,	Submaxillary,
Buccal and masseteric,	Palatine.

The *temporal vein*, which is known, as far as the zygoma, as the superficial temporal vein (*vv. temporales superficiales*), is

formed by the anterior temporal, which anastomoses with the frontal, and the posterior temporal, which anastomoses with the occipital. It penetrates the parotid gland and forms the temporomaxillary vein by uniting with the internal maxillary. It receives:—

Articular veins,
Anterior auricular,
Middle temporal (*v. temporalis media*),
Transverse facial,
Parotid.

The *internal maxillary vein* follows the course of the corresponding artery, and receives veins corresponding to the branches of that vessel. Some of these branches form the pterygoid plexus. It passes backward and unites with the temporal vein to form the temporomaxillary.

The temporomaxillary vein (*v. facialis posterior*), formed by the junction of the internal maxillary in part or whole with the temporal, passes through the parotid gland and receives the posterior auricular, to form the external jugular vein.

The occipital vein (*v. occipitalis*) follows the course of the artery, and terminates, usually, in the internal jugular; occasionally, in the external jugular. The mastoid vein, passing through a foramen in the mastoid portion, connects it with the lateral sinus.

Veins of the Tongue and Throat.—The veins of the tongue empty into the internal jugular. The lingual veins (*vv. linguales*) begin near the tip of the tongue under the name of the *ranine;* they commence on the dorsum, sides and under surface, and pass backward, receiving the dorsal lingual vein, and also the sublingual vein, as well as two small veins (*venæ comites*), and terminate in the internal jugular.

The pharyngeal (*vv. pharyngeæ*), commencing in the pharyngeal plexus (*plexus pharyngeus*), receives branches from the brain, and terminates about on a level with the hyoid bone in the internal jugular.

The superior thyroid (*v. thyreoidea superioris*) conveys the blood from the larynx, trachea and thyroid gland to the internal jugular.

Veins of the Upper Extremity.—Superficial and deep.

The subclavian vein (*v. subclavia*), the continuation of the axillary, unites with the internal jugular to form the innominate. In its passage over the first rib it is separated from the artery by the scalenus anticus muscle.

Deep Set.—The deep veins accompany the corresponding arteries and form the venæ comites, one on either side, except the axillary, which has a single vein. The valves are more numerous in the deep set. About the middle of the arm one of the brachial veins receives the basilic vein, one of the larger veins of the superficial set. The two brachial veins unite with the basilic to form the axillary vein, which in turn becomes the subclavian vein, receiving in its course beneath the clavicle the cephalic vein, a branch of the superficial set.

Superficial Set.—The anterior ulnar vein (*v. ulnaris anterior*) commences on the inner surface of the hand and wrist, and terminates by uniting with the posterior ulnar (*v. ulnaris posterior*) or the median vein. The posterior ulnar vein commences on the inner back portion of the hand, anastomosing with the radial cutaneous vein, and ascends to the bend of the elbow, where it becomes the basilic vein;

The basilic vein (*v. basilica*), from its formation at the bend of the elbow, ascends the inner side of the biceps, pierces the fascia, to join the brachial vein.

The radial (*v. radialis*) commences on the radial, dorsal aspect of the hand, and at the bend of the elbow unites with the median cephalic, to become the cephalic.

The cephalic vein (*v. cephalica*) ascends along the outer border of the biceps, and above in the groove between the deltoid and pectoralis major, and passes beneath the clavicle, to end in the axillary.

The median vein (*v. mediana cubiti*) receives the blood from the palmar surface of the hand and the front of the forearm, and usually divides into two branches—the median cephalic, passing outward to join the cephalic, and the median basilic, passing inward to join the basilic. The median basilic vein, the larger, is the one usually selected for phlebotomy.

Veins of the Trunk.—The vena azygos major (*v. azygos*) commences in the abdomen, opposite the first or second lumbar vertebra, as a continuation upward of the right ascending lumbar vein. It communicates with the right renal and the inferior vena cava. Through the lumbar veins it establishes communication with the right common iliac vein. It passes through the aortic opening of the diaphragm, or through an aperture in the right crus, ascends on the dorsal vertebræ, arches over the root of the right lung, and empties into the superior vena cava. It is in relation on its left side with the aorta, thoracic duct and esophagus. It receives

Vena azygos minor (*v. hemiazygos*),
Left upper azygos vein (*vena hemiazygos accessoria*),
Lower end of left superior intercostal vein,
Lower 8 or 9 intercostal veins,
Right superior intercostal vein,
Right subcostal vein,
Esophageal (*vv. œsophageæ*),
Right bronchial.

The hemiazygos veins are two in number:—

The vena azygos minor (*v. hemiazygos*) arises on the left side, similarly to the azygos major, and passes through the left crus of the diaphragm and about the eighth dorsal vertebra crosses beneath the aorta to join the vena azygos major;

Left upper azygos vein (*vena hemiazygos accessoria*) communicates with the upper left intercostal vein, and terminates either in the vena azygos minor or the azygos major.

The ascending or inferior cava (*v. cava inferior*), formed by the junction of the common iliac veins, at the sides of the fourth lumbar vertebra, ascends on the right of the aorta, grooves the posterior border of the liver, and passes through the quadrate foramen in the central tendon of the diaphragm, and ends in the right auricle, where it is provided with the Eustachian valve (*valvula v. cavæ inferioris* [*Eustachii*]). It receives

Middle sacral,
Lumbar (*vv. lumbales*),
Spermatic (*vv. spermaticæ*), from spermatic plexus (*plexus pampiniformis*),
Ovarian (*vv. ovaricæ*), from ovarian plexus (*plexus arteriæ ovaricæ*).
Renal veins (*vv. renales*)—the left, the longer, crosses in front of the aorta,
Suprarenal (*vv. suprarenales*),
Phrenic (*vv. phrenicæ*),
Hepatic (2 or 3) (*vv. hepaticæ*).

The portal vein (*vena portæ*), about three inches in length, is formed by the inferior and superior mesenteric, the gastric, splenic and pancreatic veins. It ascends in the right border of the lesser omentum to the transverse fissure of the liver, where it divides into the right and left. Its blood is distributed through the liver, mixing with the arterial blood from the hepatic artery, to be returned to the inferior cava by the hepatic veins. It receives

The superior mesenteric (*v. mesenterica superior*),
Splenic (*v. lienalis*),
Coronary (*v. coronaria ventriculi*).
Cystic (*v. cystica*),
Inferior mesentery (*v. mesenterica inferior*),
Right gastroepiploic.

The portal vein and its branches are destitute of valves.

Veins of the Vertebral Column.—1. The dorsi-spinal veins (*plexus venosi vertebrales externi*) commence in an intricate network surrounding the vertebral arches and their processes. They communicate with the intercostal, vertebral, intraspinal plexus, lumbar, sacral and the superficial veins of the back.

2. The intraspinal or meningorachidian veins (*plexus venosi vertebrales interni*) form an intricate plexus between the vertebræ and dura mater within the spinal canal. They consist of four longitudinal veins—two in front and two behind. The anterior longitudinal spinal veins (*sinus vertebrales longtudinales*), two in number, extend along the sides of the vertebral bodies and opposite the bodies communicate by transverse trunks, which, in their passage beneath the vertebral ligament, receive the diploic veins, or venæ basis vertebræ (*v. basivertebralis*), from the interior of the body. The *posterior longitudinal veins,* also two in number, smaller than the anterior, extend down the vertebral arches and are connected by transverse branches opposite the latter.

They receive the veins from the spinal cord and its membranes.

3. The venæ basis vertebræ (*v. basivertebralis*) return the blood from the bodies of the vertebræ into the anterior intraspinal plexuses.

The venæ medulli spinalis (*vv. spinales*) are the essential veins of the cord, situated between the arachnoid and pia mater.

Common Iliac Veins (*v. iliaca communis*).

Formed by the internal and external iliac veins uniting opposite the sacroiliac articulation, pass beneath the right common iliac artery to a point a little to the left of the body of the last lumbar vertebra, where they unite to form the inferior vena cava. The right is shorter and more vertical in its course, and both are without valves.

The internal iliac or hypogastric vein (*v. iliaca interna* or *v. hypogastrica*) corresponds to the distribution of the corresponding artery.

It receives the following venæ comites:—

Gluteal (*vv. gluteæ*),
Sciatic,
Obturator (*v. obturatoriæ*),
Internal pudic (*vv. pudendæ internæ*),
Lateral sacral (*vv. sacrales laterales*) and
Middle sacral;

and the following plexuses:—

Vesicoprostatic, Hemorrhoidal,	in male;	Uterine and Vaginal,	in female.

The lateral and middle sacral form a small plexus—the plexus sacralis.

The veins of the rectum, bladder, and generative organs anastomose freely and form three plexuses:—

1. Hemorrhoidal plexus (*plexus hæmorrhoidalis*) encircles the lower part of the rectum, communicates with the sacral and prostatic plexuses, and veins from it join the inferior mesenteric, internal iliac and pudic veins.

2. *Vesicoprostatic plexus* surrounds the membranous portion of the urethra, neck of bladder, prostate body and seminal vesicles. It communicates behind with the hemorrhoidal.

3. Uterovaginal plexuses (*plexus uterovaginalis*).—These correspond in the female with the prostatic, and communicate with the vesical and hemorrhoidal plexuses, the ovarian, pudic, and through the *uterine veins* join the internal iliac veins.

During pregnancy these veins or plexuses become greatly distended and enlarged, forming the uterine sinuses, but retain a straight course.

The *pudic vein* follows the same course as the artery, communicates with the prostatic and hemorrhoidal plexuses, and terminates in the internal iliac vein.

In the female it originates from the clitoris and perineum, and communicates with the vaginal plexus.

The dorsal vein of the penis (*v. dorsalis penis*) returns the blood from the body of that organ. It commences as two venæ comites of the dorsal artery, which unite on the dorsal surface of the root of the penis, perforates the triangular ligament, and again divides to terminate in the prostatic plexus.

The *veins* of the *corpus cavernosum* emerge at the lower groove, and turn round their outer side to join the dorsal vein.

The *dorsal vein* of the *clitoris* has a corresponding origin and course, and empties into the vaginal plexus.

The EXTERNAL ILIAC VEIN (*v. iliaca externa*), the continuation of the femoral, lies internal to the artery beneath Poupart's ligament, and joins the internal iliac opposite the sacroiliac symphysis, to form the common iliac vein. It runs along the brim of the pelvis. It receives at its commencement the venæ comites of the epigastric artery and the circumflex iliac.

Lower Extremity.—The deep veins of the lower extremity pursue the exact course of the corresponding arteries, anastomosing across the vessels they accompany, except the femoral, which has but one vein.

The popliteal vein (*v. poplitea*), formed by the junction of the anterior and posterior tibial veins, ascends to the lower margin of Hunter's canal, where it becomes the femoral. It receives the articular veins, sural veins and the external saphenous. At its commencement it lies internal and superficial, at the middle of the space directly behind, and, in the upper part of its course, external to the artery.

The femoral vein (*v. femoralis*), at first behind the artery, inclines to the inner side as it ascends, and at Poupart's ligament becomes the external iliac. It receives the profunda femoris, the internal saphenous vein, and numerous muscular veins.

The *superficial veins* of the lower extremity consist of two principal trunks: the external short saphenous (*v. saphena parva*) commences on the dorsum of the foot, passes behind the outer malleolus, ascends the leg, and pierces the deep fascia in the popliteal space, to terminate in the popliteal vein. The long saphenous vein (*v. saphena magna*), the larger, arises from the dorsum and inner side of the foot, ascends the front and inner side of the leg and thigh, and passes through the saphenous opening to join the femoral vein.

The Pulmonary Veins (*v. pulmonales*).—The pulmonary veins are four short, venous trunks, two from the base of each lung passing to the left auricle, returning arterial blood.

They differ from other veins in the following respects:—

1. They are without valves;
2. They carry arterial blood;
3. They accompany the arteries singly;
4. They are a little larger than their arteries.

The right are longer than the left, and pass from the root of the lung, on a lower level than the artery, behind the aorta, superior cava and right auricle, to enter the left auricle.

The Lymphatic System.

The lymphatic system includes the lymphatic vessels, glands and the lacteals, and forms an important accessory to the blood-vascular system, collecting the transuded, unappro-

priated fluids of the body, and the nutritive material derived from the food, and conveying it into the venous system.

It consists of two main trunks:—

(*a*) Thoracic duct (*ductus thoracicus*); (*b*) Right lymphatic duct (*ductus lymphaticus dexter*);

and five smaller trunks:—

1. Jugular lymphatic trunk;
2. Subclavian lymphatic trunk;
3. Bronchomediastinal lymphatic trunk;
4. Lumbar lymphatic trunk;
5. Intestinal lymphatic trunk.

Lymphatics have been found in nearly every organ and texture in the body except the brain, the spinal cord, cartilage, tendon, eyeball, placenta, umbilical cord, membranes of the ovum, hair, cutis and the labyrinth of the ear. They appear to originate as a fine capillary network interwoven among the blood vessels and proper elements of the tissues, or, more minutely, in the lymph, perivascular, and perineural spaces. In the villi they commence as closed, club-like tubes.

The *lymphatic capillaries* are somewhat larger than the vascular capillaries and destitute of valves. Their main trunks pass through lymphatic glands lying in their course; before doing which, however, they divide into afferent vessels, which, on emerging, unite into a smaller number of large vessels, the efferent.

In structure, they are composed of three coats—the external fibroareolar, middle muscular, and internal or endothelial and elastic.

The lymphatic glands (*lymphoglandulæ*) are generally situated in the course of the blood vessels, lymphatic vessels, or lacteal vessels, being accumulated together in certain localities, as the neck, abdomen, axilla, etc.

The lymphatic glands and vessels are named from the regions they occupy or the vessels they accompany, and consist usually of a superficial and deep set. Thus, we have cervical, axillary, mediastinal, lumbar, inguinal, etc., and the lymphatic vessels corresponding.

The *lacteals*, or *chyliferous vessels*, are the lymphatic vessels of the small intestine, and differ only from the others in carrying chyle during digestion from the intestines to the thoracic duct.

The thoracic duct (*ductus thoracicus*) is formed by the junction of the two lumbar lymphatic trunks with the intestinal

lymphatic trunk, in front of the second lumbar vertrebra, between the aorta and inferior vena cava, as the receptaculum chyli, or cistern of Pecquet (*cisterna chyli*). This receptacle is about one to two inches long and a quarter of an inch wide. From its origin the thoracic duct ascends through the abdomen, passes through the aortic orifice in the diaphragm, and ascends behind the esophagus between the aorta and azygos vein to the fourth dorsal vertebra, where it passes to the left beneath the aorta, and ascends between the esophagus and the left subclavian artery to the last cervical vertebra, where it arches forward, outward and downward to enter the junction of the subclavian and the left internal jugular vein at its posterior aspect. Its orifice is protected by a pair of valves. It receives all the lymphatic vessels below the diaphragm, those of the left side of the head, neck and left upper extremity.

The right lymphatic duct (*ductus lymphaticus dexter*) is about half an inch long and one-twelfth inch wide. It empties in a corresponding manner on the right side to the thoracic duct. It receives all the lymphatics of the right side of the thorax, neck, head and right upper extremity.

Lymphatics of the Head and Neck.—The substance of the brain is probably destitute of lymphatics, but they are very numerous in the pia mater and choroid plexuses of the lateral ventricles, and pursue the same course as the principal veins, to emerge at the base through the various foramina, to terminate in the deep cervical glands. The occipital lymphatic vessels terminate in the posterior auricular, or retroauricular or mastoid glands (*lymphoglandulæ auriculares posteriores*), and occipital or suboccipital glands (*lymphoglandulæ occipitales*). The temporal lymphatic vessels terminate in the anterior or auricular glands. The lymphatics of the face are superficial and deep. The superficial lymphatics are numerous, and terminate in the submaxillary glands, six or more in number; the deep lymphatics accompany the branches of the internal maxillary artery, and terminate in the deep cervical and deep parotid glands about the ramus of the jaw.

Lymphatics of the Upper Extremity.—Lymphatics of the upper extremity are composed of two sets, the superficial and deep. The *superficial lymphatic glands* are few in number, one or two only being situated at the internal condyle of the humerus. The deep lymphatic glands lie along the course of the vessels, and communicate with the axillary glands. All of these glands unite in the deep axillary glands (*lymphoglandulæ axillares*), about eight to ten in number, which com-

municate with the deep cervical glands, and through them empty into the subclavian lymphatic trunk, to end finally in the thoracic or right lymphatic duct. The superficial and deep vessels of the thorax, the former in the skin, the latter from the mammary glands, pectoral and other muscles, for the most part, pass to the axilla, a few only terminating in the glands below the clavicle.

The Cavity of the Thorax.—The *intercostal* lymphatic vessels, derived from the side of the abdomen and thorax, pleuræ, diaphragm, spinal canal, muscles of the back, etc., follow the course of the veins, traverse fifteen to twenty intercostal glands (*lymphoglandulæ intercostales*) near the heads of the ribs, and terminate in the thoracic duct. The posterior mediastinal glands (*lymphoglandulæ mediastinales posteriores*) are between the intercostal glands, and communicate with them, receiving vessels from the pericardium, esophagus and diaphragm. Some of the efferent vessels end in the bronchial glands, others in the thoracic duct. The anterior mediastinal lymphatic vessels (*lymphoglandulæ mediastinales anteriores*) are derived from the anterior wall of the abdomen and thorax, the diaphragm, pericardium, upper surface of the liver, heart and thymus gland. They traverse about eighteen to twenty *anterior mediastinal glands,* situated in the course of the internal mammary vein, pericardium, and great vessels of the heart, and terminate in thoracic and right lymphatic ducts. The pulmonary lymphatic vessels consist of a superficial and deep set, traversing in the last part of their course the pulmonary glands. The *bronchial glands* are twenty or more glands at the bifurcation of the trachea and root of the lungs, and receive the lymphatic vessels of the lungs and bronchi. They become pigmented, and are often the seat of disease. Their efferent vessels terminate on the right side in the right lymphatic duct, either directly or by forming the bronchomediastinal trunk, and on the left side in the thoracic duct.

Lower Extremity and Pelvis.—The superficial lymphatic vessels from the back of the foot follow the course of the long saphenous vein, passing to the superficial inguinal glands (*lymphoglandulæ inguinales superficiales*); and those from the sole of the foot follow the short saphenous vein, joining the deep set in the popliteal space. The deep lymphatic vessels follow the deep veins, traverse two to four popliteal glands (*lymphoglandulæ popliteæ*), and join the deep inguinal glands (*lymphoglandulæ inguinales profundæ*). The deep lymphatic glands in the pelvis consist of three sets: the *external*

iliac, around the external iliac vessels; the *internal iliac,* around the internal iliac vessels; and the *sacral glands,* on the anterior surface, and in the mesorectal folds.

Lymphatics of the Abdomen.—The lymphatic vessels of the external and internal iliac glands enter the lumbar glands, twenty-five or more in number, situated upon the vertebræ, the origin of the diaphragm, the psoas and quadratus lumborum muscles and the great blood vessels. They receive vessels from the kidneys, ureters, loins, suprarenal bodies, ovaries and testicles, and form lumbar lymphatic trunks, which ascend to join the thoracic duct or receptaculum chyli. The *lymphatic vessels of the stomach* follow the general course of the blood vessels. They consist of three groups: the first, along the lesser curvature, passing to the glands along the pylorus; the second, at the great end of the stomach, passing to the splenic lymphatic glands; and the third, at the greater curvature, passing to one of the principal lacteal vessels. The *lymphatics* of the *small intestine* are called also lacteals. They pass between the layers of the mesentery and traverse a large number of mesenteric glands, arranged irregularly into three rows. The *lymphatic vessels* of the *large intestine* traverse the mesocolic glands, about thirty in number, and pass into the superior mesenteric glands. The vessels from the spleen and pancreas follow the course of the splenic vein, traverse a number of the glands, to end in the celiac glands. The *lymphatics of the liver* consist of superficial and deep, and are very extensive, both on the upper and lower surfaces. They terminate in the right lymphatic duct, the glands of the gastrohepatic omentum, the anterior mediastinal glands, the esophageal glands, the glands of the lesser curvature and of the thoracic duct. The deep lymphatics follow the course of the portal vein and hepatic artery and duct, and, emerging, join one of the lacteal vessels before it enters into the thoracic duct. The *celiac glands,* fifteen or twenty in number, are situated behind the pancreas and duodenum, the aorta, portal vein, celiac and superior mesenteric vessels. Their efferent vessels form the intestinal lymphatic trunk and empty into receptaculum chyli.

THE ALIMENTARY APPARATUS.

THE alimentary apparatus consists of the alimentary canal and of certain accessory organs.

The former is a musculo-membranous canal about thirty feet in length, extending from the mouth to the anus, and comprises: first, *the organs of deglutition,* consisting of the mouth, pharynx, and œsophagus; and, second, *the organs of digestion,* consisting of the stomach and small and large intestines. It is lined throughout by mucous membrane. The accessory organs comprise the teeth, salivary glands, liver, and pancreas.

Alimentary Apparatus.

- Alimentary canal,
  - Organs of deglutition,
    - Mouth,
    - Pharynx,
    - Œsophagus.
  - Organs of digestion,
    - Stomach,
    - Small intestine,
      - Duodenum,
      - Jejunum,
      - Ileum.
    - Large intestine,
      - Cæcum,
      - Colon,
      - Rectum.
- Accessory organs,
  - Teeth,
  - Salivary glands,
    - Parotid,
    - Submaxillary,
    - Sublingual.
  - Liver,
  - Pancreas.

THE MOUTH (*cavum oris*) is an oval cavity in which mastication takes place preparatory to deglutition. It is placed at the entrance of the alimentary canal, is bounded laterally by the alveolar processes of the upper and lower jaws and cheeks; above by the upper teeth and hard palate; below by the tongue, the lower jaw, the mucous membrane between, and the lower teeth; in front by the lips; and behind by fauces and soft palate. It terminates posteriorly at the anterior pillars of the fauces, through the fauces into the pharynx.

It is invested throughout (except on the teeth) with highly vascular mucous membrane covered with stratified squamous epithelium containing conical papillæ.

It presents for examination the following parts:—

The Teeth (*dentes*).—The teeth are firmly implanted within the alveoli of the jaws (*alveoli dentales*) and surrounded by the gums.

The gums (*gingiva*) are composed of dense fibrous tissue, covered by smooth, vascular, mucous membrane of slight sensibility. This fibrous tissue is continuous with the periosteum of the jaws, and forms about the neck of the teeth a constricted ring—the *dental ligament.*

There are four kinds of teeth—incisors, canines or cuspids, premolars or bicuspids, and molars. Man is provided with two sets of teeth, the temporary, deciduous, or milk teeth, which appear in childhood, and the permanent, which appear after the shedding of the milk teeth, and last until old age.

The temporary or deciduous teeth (*dentes decidui*) are twenty in number, ten in each jaw; or five in each side of each jaw:—

Two incisors, one canine, and two molars.

The permanent teeth (*dentes permanentes*) are thirty-two in number, sixteen in each jaw, or eight in each side of each jaw (*arcus dentalis superior* or *arcus dentalis inferior*):—

Two incisors, one canine, two bicuspids, three molars.

Each tooth consists of three parts:—

Crown, or body (*corona dentis*), the enameled portion above the gum; neck (*collum dentis*), the constricted portion between the crown and root; root, or fang (*radix dentis*), within the alveolus, and covered with cement.

Characteristics.—Incisors (*dentes incisivi*), or cutting, are so-called from their wedge-shaped, chisel-like crown, being adapted for biting or cutting the food. The fang is long, single, conical and compressed at the sides.

Cuspids, or canines (*dentes canini*), have been so named from their conspicuous character in the canine or dog tribe.

The crown is large, conical, convex in front, and beveled behind. The fang is single, longest and thickest of all the teeth.

Bicuspids, or premolars (*dentes premolares*). The crown has a pair of projecting tubercles or cusps. Fang is conical, single, but deeply grooved, indicating a disposition to bifurcate.

Molars (*dentes molares*), commonly known as *grinders* or *jaw teeth.* Crown, broad, quadrilateral, with four cusps in

upper, five in lower molars. Lower molars have usually a pair of fangs placed laterally; the upper, three fangs, two external and one internal.

The last or third molar has but one fang (with a tendency to divide into the same number of roots as the other molars), and is known as the *dens sapientiæ*, or "wisdom tooth" (*dens serotini*), from its late appearance.

Structure.—On section a tooth consists of two portions, the pulp cavity (*cavum dentis*) and the solid portion surrounding it.

The solid portion consists of three structures, dentine or ivory, which forms the principal mass of the tooth; enamel, which covers the crown, and cement, which covers the surface of the fang.

Dentine or ivory (*substantiæ eburnea*), resembles bone, but differs from it in composition and structure, consisting of twenty-eight parts animal and seventy-two parts mineral matter, and being made up of minute tubuli held together by the intertubular substance.

The dental tubuli (*canaliculi dentales*) are minute cylindrical canals $\frac{1}{4500}$ of an inch in diameter. They pass in a spiral direction from the pulp cavity to the periphery.

Enamel (*substantia adamantina*), the hardest and densest of all organized bodies, contains but 3.5 per cent. animal matter, and is composed of minute hexagonal rods (*prismata adamantina*) $\frac{1}{5500}$ of an inch in diameter, placed at right angles to the surface of the dentine. The external surface of unworn enamel can be separated as a thin, homogeneous membrane, Nasmyth's membrane (*cuticula dentis*).

Cement, or crusta petrosa (*substantia ossea*), is a thin layer of true bone with canaliculi and lacunæ, disposed on the surface of the fang.

The pulp cavity (*cavum dentis*) is a cavity within the base of the crown, continuous with a canal in the center of the fang, and open at the apex of the fang (*canal radicis dentis*) for the entrance of vessels and nerves. It is filled with dental pulp (*pulpa dentis*).

Dental pulp consists of two kinds of cells, the fusiform and the columnar, or *odontoblasts* of *Waldeyer,* held together by loose connective tissue. It is soft, vascular and highly sensitive. The nerves are both medullated and non-medullated, and form a rich plexus beneath the odontoblastic layer. The terminal fibrils probably unite with these cells, but the exact distribution is still unsettled.

Development—Temporary.—They are formed very early, seven to eleven weeks, in the *primitive dental groove* by an involution of the epithelium of the oral cavity covering the maxillary arches into the blastema or corium and connective tissue below, the former giving the enamel, the latter the cement and dentine.

The enamel comes from the *enamel germ,* a mass of epithelial cells, descending into the dental groove until it meets the dentine papilla (*papilla dentis*), a vascular growth extending upward from the connective tissue, upon which it forms a

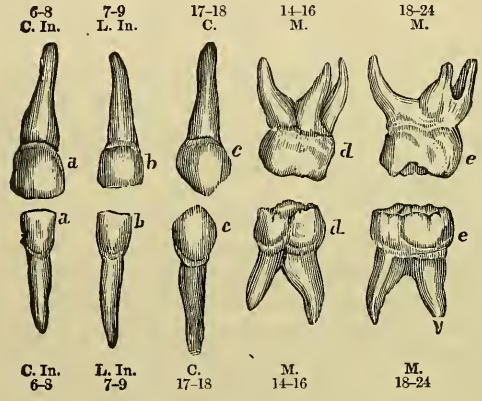

FIG. 86.

Temporary teeth.

cap. A vascular membrane inclosing the enamel germ then extends itself—as the *dental sac*—upon the united papilla and enamel germ and cuts the latter off from its earlier epithelial structure. The cells become differentiated and finally calcify.

The dentine is formed by the development of odontoblasts in the periphery of the papilla in a similar manner to the development of osteoblasts in bone.

The cement is developed from the wall of the dental sac by the intramembranous process of ossification.

Permanent.—The *successional permanent teeth,* or those replacing the temporary, are developed in a different manner from the *superadded,* or three molars in each side of each jaw.

The former are developed similarly to the temporary teeth, but in a *secondary dental groove,* from which, after their formation, they recede behind the germs of the temporary teeth,

inclosed in sacs. The molars, or superadded teeth, however, are formed by extensions backward of a portion of the enamel germ of the tooth immediately in front.

Eruption, or "cutting of the teeth," takes place by the growth of the fang, the gums being absorbed by the pressure of the advancing crown. The development of the fangs of the permanent causes the absorption of the fangs of the temporary teeth through the agency of the *odontoclasts*, multinucleated cells corresponding to the osteoclasts of bone.

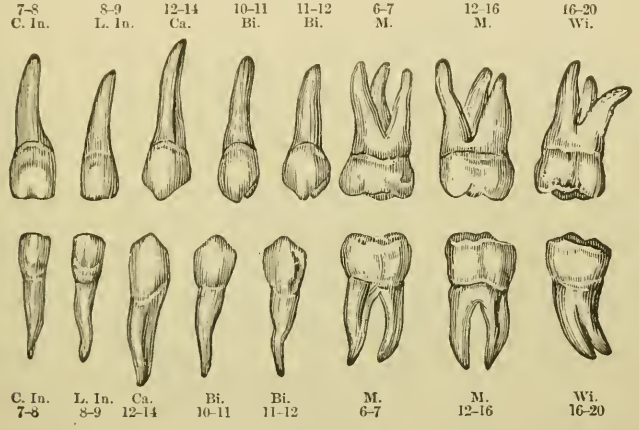

FIG. 87.

Permanent teeth.

The eruption of the temporary teeth takes place in *months* in the order shown in Fig. 86, the lower preceding by a short time the upper (according to Dr. C. N. Pierce, in "American System of Dentistry"). The order of the eruptions is: first the lower central incisors, the upper central incisors, lateral incisors, upper and lower, first molars, followed by the canines or cuspids, and ending with the second molars.

The eruption of permanent teeth takes place in *years* as in Fig. 87, the order of the eruptions being, first the "first or sixth year molar," followed by the first central incisors, four lateral incisors, four first bicuspids, four second bicuspids, the first canines or cuspids, the four second molars, and ending with the four third molars or "wisdom teeth."

About the sixth year the jaws contain the temporary teeth fully erupted, and the crowns of all the permanent teeth except the four wisdom teeth, in all forty-eight.

It should be noted that the first permanent or "sixth-year" molar is erupted before any of the permanent teeth, and that the second bicuspid takes the place of the second temporary molar.

Vessels and Nerves of the Teeth.—The *arteries* of the upper teeth are derived from the anterior dental branches of infra-orbital and posterior or alveolar dental branches of the internal maxillary; of the lower teeth, from the inferior dental branch of the internal maxillary.

The *nerves* are distributed to the upper teeth from the anterior and posterior dental branches of the superior maxillary (second division of fifth cranial nerve), and to the lower teeth from the inferior maxillary (third division of fifth cranial nerve).

Soft palate (*palatum molle*) is a movable fold of mucous membrane suspended from the posterior border of the hard palate, and inclosing an aponeurosis, vessels, nerves, glands and the following muscles on each side; tensor palati, levator palati, palatoglossus, palatopharyngeus and azygos uvulæ, the latter uniting with its fellow to form the uvula (*uvula palatina*).

Hard palate (*palatum durum*) is formed by the palatal process of the superior maxillary and the palate bone, and covered by a thick, dense structure composed of mucous membrane and periosteum combined. It forms the roof of the mouth, and presents a median raphé (*raphé palati*) and corrugated surface (*plicæ palatinæ transversæ*).

Anterior pillar of the fauces (*arcus glossopalatinus*) is a fold of mucous membrane arching downward and forward from the base of the uvula to the base of the tongue, and inclosing the palatoglossus muscles.

Posterior pillar of the fauces (*arcus pharyngopalatinus*) is a similar fold arching downward and backward from the base of the uvula to the sides of the pharynx, and inclosing the palatopharyngei muscles.

The tonsils (*tonsilla palatina*), or amygdalæ, are small, almond-shaped, glandular bodies situated on each side of the fauces between the anterior and posterior pillars. They rest upon the superior constrictor of the pharynx, which separates them from the ascending pharyngeal and internal carotid arteries. They are composed of numerous follicles (*fossulæ tonsillares*) (lined by closed capsules containing adenoid tissue),

which contain a thick, grayish secretion and open on the surface of the gland by a dozen or more orifices.

The *arteries* to the tonsil are from the tonsillar and ascending palatine of the facial, dorsalis linguæ from the lingual, ascending pharyngeal from external carotid, branch from small meningeal, and descending palatine branch of internal maxillary.

The *nerves* are from glossopharyngeal and Meckel's ganglion.

The Salivary Glands.—The salivary glands communicating with the mouth are three: the parotid, submaxillary and sublingual.

The parotid gland (*glandulæ parotis*), so called from its location near the ear, is the largest, weighing from a half to one ounce. It occupies the space in front of the ear, bounded below by the angle of the jaw, and a line extended from it to the mastoid process, above by the zygoma, in front by the masseter muscle, and behind by the mastoid process, the external meatus and the digastric muscle. The external carotid artery, the temporomaxillary vein, the facial nerve and the great auricular nerve pass through it.

The duct of the parotid gland (*ductus parotideus* [*Stenonis*]), Steno's or Stenson's duct, empties its secretion into the mouth. It is about two and a half inches in length, of the diameter of a crow's quill, and crosses the face upon the masseter muscle, through the substance of the buccinator muscle, in the direction of an imaginary line drawn about a finger's breadth below the zygoma, from the lower part of the ear to midway between the ala of the nose and the margin of the upper lip, to open about the position of the second molar tooth of the upper jaw.

Its *arteries* are branches of the external carotid. The *veins* empty into the external jugular. The *lymphatics* empty into the superficial and deep cervical glands, and the *nerves* are derived from the facial, from the superficial temporal branches of the great auricular, the auriculotemporal and sympathetic.

The submaxillary gland (*glandula submaxillaris*) occupies the submaxillary fossa on the inferior surface of the inferior maxilla, within the submaxillary triangle of the neck. The facial artery grooves its upper and posterior border, and it is separated behind from the parotid gland by the stylomaxillary ligament. The duct of the submaxillary gland, or Wharton's duct (*ductus submaxillaris* [*Whartoni*]), about two inches in length, passes forward between the hyoglossus, geniohyoglossus

and mylohyoid muscles, to open at the side of the frænum linguæ in a small papilla (*caruncula sublingualis*).

Its *arteries* are from the facial and lingual; the veins follow the course of the corresponding arteries; the *nerves* are from the submaxillary ganglion, the sympathetic and the mylohyoid branch of the inferior dental.

The sublingual gland (*glandula sublingualis*), the smallest, lies on the floor of the mouth, at the side of the frænum linguæ, beneath the mucus membrane. Its ducts, called the ducts of Rivinus (*ductus sublingualis minores*), from eight to twenty, open on the mucous membrane. One of them, the longest, called the duct of Bartholin (*ductus sublingualis major*), joins Wharton's duct. Its *arteries* are from the submental and sublingual. The *nerves* are branches from the gustatory.

Besides these glands, the mucous membrane of the mouth is plentifully supplied with mucous glands.

The pharynx is a musculomembranous sac, extending from the basilar process of the occipital bone above to the level of the fifth cervical vertebra or the cricoid cartilage below. It is about four and a half inches in length. It has communicating with it seven openings:—

Two posterior nares,	Larynx,
Two Eustachian tubes,	Esophagus,
Mouth.	

It is composed of three coats:—

1. *Fibrous coat,* or pharyngeal aponeurosis, attached above to the pharyngeal spine of the basilar process of the occipital bone; it affords attachment in the median line to the constrictor muscles of the pharynx.

2. Mucous coat (*tunica mucosa*), continuous with that of the various openings. It is covered in its upper part with columnar ciliated epithelium, as low as the floor of the nares, below which it is squamous. It contains numerous racemose glands (*glandulæ pharyngeæ*), crypts, and lymphoid structure similar to the tonsils, a mass of which, between the Eustachian tubes, has been called the "pharyngeal tonsil."

3. Muscular coat (*tunica muscularis pharyngis*), consists of the three pharyngeal constrictors, the palatopharyngeus and the stylopharyngeus. (*Vide* Muscles.)

Arteries are from the inferior palatine, pharyngeal and thyroid arteries. *Nerves* are branches of the pneumogastric, glossopharyngeal and sympathetic.

THE ESOPHAGUS, or GULLET, is a musculomembranous tube about nine inches long and less than one inch in diameter, flattened from before backward, and extending from the pharynx to the stomach or from the level of the fifth cervical to the ninth dorsal vertebra.

Relations.—In the neck the trachea is in front, the common carotids on either side, and in the chest the pericardium, the left carotid,

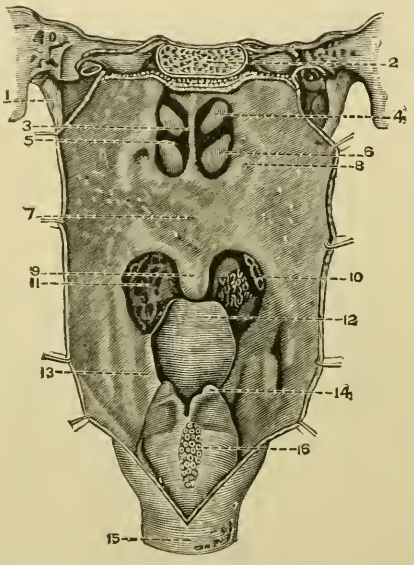

FIG. 88.

Pharynx laid open from behind: 1, styloid process; 2, body of occipital bone; 3, septum nasi; 4, middle turbinated bone; 5, posterior naris; 6, inferior turbinated bone; 7, soft palate; 9, uvula; 10, tonsil; 11, back of tongue; 12, epiglottis; 13, arytenoepiglottidean fold; 14, tip of arytenoid cartilage; 15, esophagus; 16, back of cricoid cartilage.

left subclavian, the aorta and the left bronchus are in front; the longus colli muscle and the intercostal vessels and the vertebral column are behind. The pleura covers it laterally, the descending portion of the arch of the aorta lying on the left and the vena azygos major on the right.

Its structure consists of three coats:—

Muscular coat (*tunica muscularis*), consisting of two layers, the longitudinal and the circular, continuous with the inferior constrictor;

Areolar or fibrous coat (*tela submucosa*), connecting the two;

Mucous coat (*tunica mucosa*), covered with stratified pavement epithelium, and having beneath it some non-striated muscular fibers, the muscularis mucosæ. It also contains numerous compound racemose glands, namely, the esophageal glands.

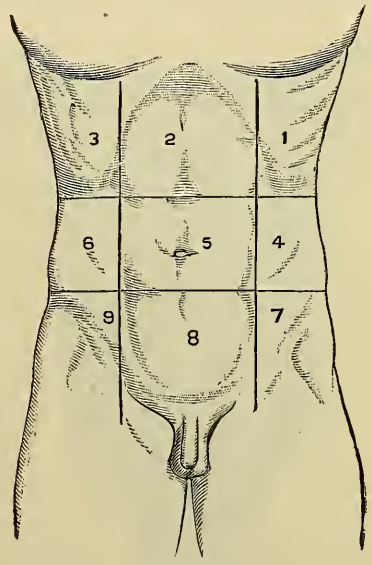

FIG. 89.

1, left hypochondriac region; 2, epigastric; 3, right hypochondriac; 4, left lumbar; 5, umbilical; 6, right lumbar; 7, left iliac; 8, hypogastric; 9, right iliac.

THE ABDOMEN.

The abdomen, the largest cavity in the body, is bounded in front and laterally by the abdominal muscles, the lower ribs, the ilii, above by the diaphragm, below by the brim of the pelvis, and behind by the vertebral column, quadratus lumborum and psoas muscles. It is lined throughout by peritoneum, inclosing the greater portion of the alimentary canal. It has six openings, as follows:—

Aortic opening, for the vena azygos, aorta and thoracic duct;
Esophageal opening, for the esophagus and pneumogastric nerves;
Quadrate opening, for the vena cava inferior;

Umbilicus, in front, for the fetal umbilical vessels;
Femoral canal (*vide* femoral hernia);
Inguinal canal, for the round ligament in the female, and the spermatic cord in the male.

REGIONS OF THE ABDOMEN.—For convenience of study, the cavity of the abdomen is divided into nine regions by four imaginary lines, two circular lines drawn around the body, one at the lower margin of the thorax (Leidy) or on a level with the cartilages of the ninth rib, the second at the highest point of the crest of the ilium; and two vertical lines, drawn from the cartilage of the eighth rib on each side through the center of Poupart's ligament, or from the anterior inferior spinous process of the ilium, drawn upward (Leidy). These regions are named as follows:—

Right hypochondriac,	Epigastric region,	Left hypochondriac,
Right lumbar,	Umbilical region,	Left lumbar,
Right inguinal (iliac),	Hypogastric region,	Left inguinal (iliac).

Contents of Regions.

Right Hypochondriac.	*Umbilical.*	*Left Hypochondriac.*
Hepatic flexure of colon, right lobe of liver, gall-bladder and upper part of right kidney.	Left lobe of liver, lobulus Spigelii, greater part of stomach, duodenum, pancreas, portions of the kidneys and suprarenal capsules, vena cava, aorta, thoracic duct, semilunar ganglia.	Splenic flexure of colon, spleen, tail of pancreas, splenic end of stomach and upper part of left kidney.
Right Lumbar.	*Umbilical.*	*Left Lumbar.*
Greater part of right kidney, ascending colon and portions of the small intestine.	Transverse portions of colon and duodenum, jejunum, and ileum, part of mesentery and great omentum, receptaculum chyli and portions of both kidneys.	Part of left kidney, descending colon, some convolutions of small intestine and part of the omentum.
Right Inguinal (Iliac).	*Hypogastric.*	*Left Inguinal (Iliac).*
Right ureter, cecum, spermatic vessels and appendix ceci.	Portions of the small intestine under certain circumstances, the uterus (pregnant), bladder (distended), sometimes the cecum, sigmoid flexure and appendix.	Left ureter, sigmoid flexure of colon and spermatic vessels.

Peritoneum (*tunica serosa*).—The peritoneum is a closed serous sac, its parietal layer (*peritonæum parietale*) lining the cavity of the abdomen, its visceral layer (*peritonæum viscerale*) inclosing more or less completely all the abdominal and pelvic viscera. It is not in all cases a closed sac, for in the female it is continuous with the mucous membrane of the Fallopian tubes. It consists essentially of two sacs of unequal size, the greater and lesser peritoneal sacs, united by a central constriction—the foramen of Winslow:—

The *greater sac* is located in front of the viscera, one layer lining the internal abdominal wall, the other reflected upon the viscera. Its cavity is known as the *greater peritoneal cavity.*

The *lesser sac* covers the upper part of the posterior abdominal wall, and is reflected upon the posterior surface of the liver and stomach. Its cavity is called the lesser peritoneal cavity. It also gives off three processes, one of which is a broad, loose fold,—the great omentum (*omentum majus*),—passing downward from the greater curvature of the stomach between the two layers of the greater sac, and is reflected upon itself back to the under surface of the transverse colon.

The foramen of Winslow (*foramen epiploicum* [*Winslowi*]) is a narrow canal, large enough to admit one finger, between the greater and lesser peritoneal cavities, located behind the right border of the lesser omentum, and formed by the hepatic and gastric arteries, constricting the sac at this point as they ascend from the celiac axis. It is bounded as follows:—

In front, by the lesser omentum, containing the hepatic artery, portal vein, duodenum and the ductus communis choledochus;
Behind, by the right crus of the diaphragm and the inferior vena cava;
Above, by the lobus Spigelii;
Below, by the hepatic artery.

Reflections.—The reflections of the peritoneum viewed in an anteroposterior section (the greater and lesser sacs together) may be traced as follows: From the diaphragm it is reflected to the upper surface of the liver. Enveloping this organ it then presents a doubling or fold—the gastrohepatic omentum—extending downward from the transverse hepatic fissure to the lesser curvature of the stomach. Inclosing the stomach, it is reflected upon itself in front of the intestines as a broad apron—the great omentum (*omentum majus*)—making a quadruple fold of peritoneum.

The two layers then embrace the transverse colon, unite and pass back to the vertebral column, forming the transverse

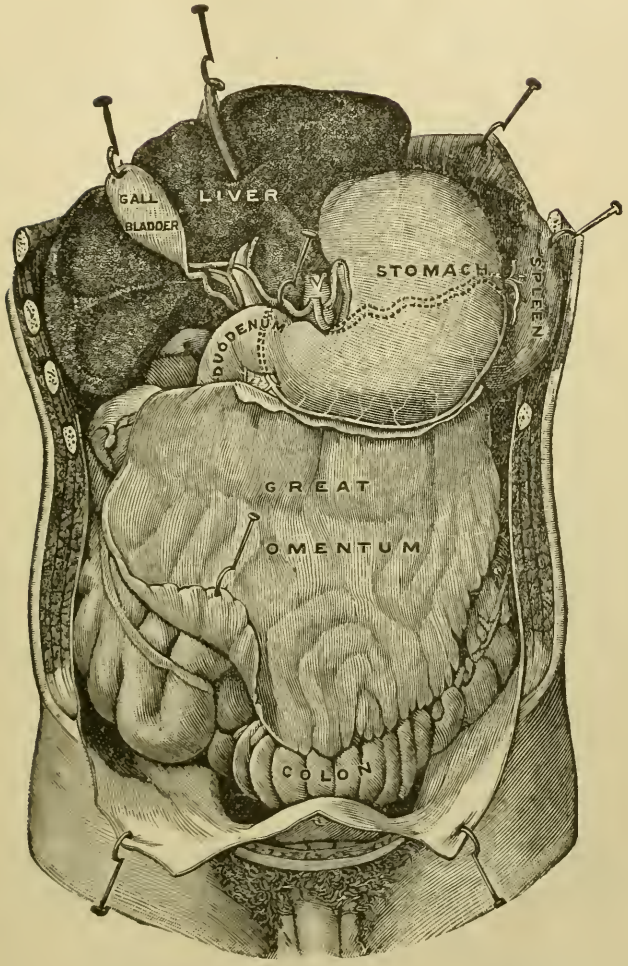

FIG. 90.

The abdominal viscera. (*Eckley.*)

mesocolon (*mesocolon transversum*). From here the layers separate, the upper one ascending in front of the pancreas to the starting point. The lower layer descends in front of the duodenum, incloses the small intestine—forming the mesentery proper—(*mesenterium*), is reflected upon the rectum—

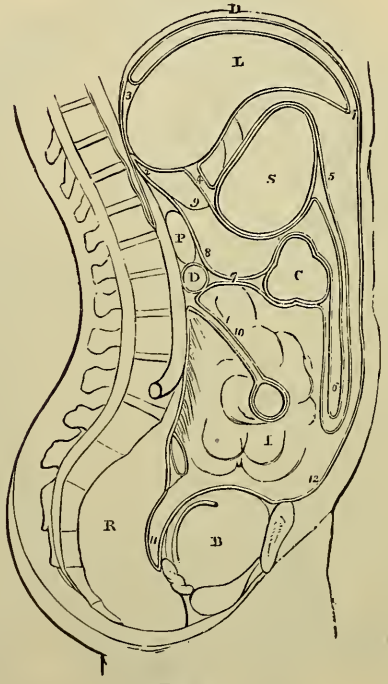

FIG. 91.

D, diaphragm; L, liver; S, stomach; P, pancreas; D, duodenum; C, colon; I, small intestine; B, bladder; R, rectum; 3, posterior surface of liver; 4, foramen of Winslow; 5, great omentum; 6, lesser omentum; 7, mesocolon; 8-9, lesser cavity of peritoneum; 10, mesentery; 11, rectovesical fold.

forming the mesorectum—and upon the bladder, and ascends upon the anterior abdominal wall to the starting point.

In the female, from the rectum it envelops the uterus and upper part of the vagina before reaching the bladder.

In addition to the folds seen in the anteroposterior section, the peritoneum passes between the various organs, and also laterally to the sides of the abdominal and pelvic cavities. In this

manner are formed the right lateral (*ligamentum triangulare dextrum*), left lateral (*ligamentum triangulare sinistrum*), and suspensory ligaments of the liver (*ligamentum falciforme hepatis*), the suspensory ligament of the spleen (*ligamentum phrenicolienale*), the broad ligament of the uterus (*ligamentum latum uteri*), and the three ligaments or omenta of the stomach —the gastrohepatic (*omentum minus*), gastrosplenic (*ligamentum gastrolienale*), and gastrocolic (*omentum majus*) (already described) and the mesenteries.

The latter, the *mesenteries,* include the mesentery proper, mesocecum; ascending (*mesocolon ascendens*), transverse (*mesocolon transversum*), and descending mesocolon (*mesocolon descendens*), sigmoid mesocolon (*mesocolon sigmoideum*) and mesorectum.

The mesentery proper (*mesenterium*) is a broad fold, reflected from the vertebræ around the jejunum and ileum. Its base, attached obliquely from the left side of the second lumbar vertebra to the right iliac region, measures about six inches, while its expanded extremity is quite considerable.

In the male the rectovesical folds, one on each side, pass from the rectum to the bladder, including between them the rectovesical pouch (*excavatio rectovesicalis*). In the female, however, this pouch is divided into two—the rectouterine and vesicouterine pouches (*excavatio vesicouterina*), the rectovesical folds being called rectouterine and vesicouterine folds (*plicæ rectouterinæ*). Folds of peritoneum (superior false ligaments of the bladder) (*plicæ umbilicalis media*) ascend from the bladder to the umbilicus, inclosing the remains of the fetal urachus (*ligamentum umbilicale medium*) and hypogastric arteries, and also a fold on each side follows the course of the epigastric arteries toward the umbilicus, dividing the inguinal region into the internal, middle and external inguinal fossæ. The peritoneum at the external inguinal fossa (corresponding to the internal abdominal ring) is continuous in the male fetus with the tunica vaginalis testis, and in the female forms a blind sac about the round ligament—the canal of Nuck.

Viscera Partly Invested by Peritoneum.

Vagina—upper part;
Bladder—posterior wall;
Duodenum—descending and transverse portions;
Cecum;
Colon—ascending and descending;
Rectum—middle portion.

Viscera Entirely or Almost Entirely Covered.

Stomach,	Sigmoid flexure,
Spleen,	Rectum—upper part,
Ileum,	Liver,
Jejunum,	Uterus,
Colon—transverse	Ovaries.

Viscera Without Peritoneal Investment

Bladder—except posterior wall;
Rectum—lower third;
Vagina—lower part of posterior wall;
Pancreas,
Suprarenal capsules,
Kidneys,
} partly covered anteriorly.

THE STOMACH.

The stomach (*ventriculus*) is a musculomembranous sac, pyriform in shape, situated below the diaphragm in an oblique position across the upper abdomen, where it is held in position by the lesser omentum and the gastrosplenic ligament. It measures about nine to twelve inches in length, four to five inches in its greatest diameter, and has a capacity of from one to two quarts. It occupies the epigastric, right and left hypochondriac regions, and is in relation above with the diaphragm and liver, below with the transverse colon, in front with the abdominal walls, and behind with the pancreas. When distended the stomach rotates on its long axis and the greater curvature points somewhat forward. It presents for examination a greater and lesser extremity, greater and lesser curvatures, anterior and posterior surfaces, and cardiac and pyloric orifices.

The greater extremity, or fundus (*fundus ventriculi*), occupies the left hypochondriac region, in contact with the spleen, with which it is attached by the gastrosplenic omentum, and behind the lower rib.

The *lesser* or *pyloric end* is smaller and lies in contact with the under surface of the liver and the wall of the abdomen in the right hypogastric region.

The greater curvature (*curvatura ventriculi major*) extends between the pyloric and esophageal orifices, along the lower border of the stomach, and to it is attached the great omentum.

The lesser curvature (*curvatura ventriculi minor*) extends between the same two points along the superior border of the organ.

The *esophageal* or *cardiac orifice* occupies the highest part of the stomach, behind the seventh left costal cartilage, and receives the esophagus.

The *pyloric orifice* occupies the right extremity, and opens into the duodenum, being protected by a muscular valve, the pylorus, or pyloric valve (*valvula pylori*).

The anterior, upper or parietal surface (*paries anterior*) is in contact with the under surface of the left lobe of the liver, the abdominal walls and the diaphragm.

The posterior, lower or visceral surface (*paries posterior*) is in contact with the peritoneum of the diaphragm, solar plexus, the pancreas and the abdominal vessels.

The *structure* of the stomach consists of four coats, a serous, muscular, fibrous or areolar and mucous.

The serous coat (*tunica serosa*) is derived from the peritoneum, which completely covers it, except along the lesser and greater curvatures, where the vessels and nerves enter.

The muscular coat (*tunica muscularis*) consists of three sets of fibers:—

The longitudinal (*stratum longitudinale*), the most superficial, are continuous with the longitudinal fibers of the small intestine below, and the esophagus above;

The circular fibers (*stratum circulare*), the second layer, are most abundant at the pyloric extremity, where they form the pyloric valve (*valvula pylori*).

The oblique fibers (*fibræ obliquæ*) are distributed over both surfaces, passing obliquely from right to left and left to right.

The areolar or submucous coat (*tela submucosa*) connects the muscular with the mucous layer, and is sometimes named the vascular coat.

The mucous membrane (*tunica mucosa*) is of a pale pinkish-ash color, thickened toward the pylorus, where it presents numerous rugæ, or pleats (*plicæ mucosæ*), and at the pyloric end it helps to form the pyloric valve. It is lined throughout with columnar epithelium, and is studded with three kinds of minute tubes, the gastric follicles and lenticular glands. The gastric follicles consist of two kinds, the pyloric (*glandulæ pyloricæ*) and the peptic glands (*glandulæ gastricæ propriæ*), the former most abundant at the pyloric end and the latter distributed all over the surface of the stomach.

The pyloric or mucous glands (*glandulæ pyloricæ*) each consist of from two to four blind tubes opening into a common duct, and lined throughout by columnar epithelium.

The peptic glands (*glandulæ gstricæ propriæ*) are similar in structure, but have a much shorter duct, and contain in addition peculiar large, spheroidal, granular *peptic cells.*

The lenticular or simple solitary glands (*noduli lymphatici solitarii*) are small masses of lymphoid tissue scattered throughout the connective-tissue framework of the stomach between the gastric follicles.

The *arteries* are derived from the gastric, pyloric, right gastroepiploic branches of the hepatic artery, and the left gastroepiploic and vasa brevia branches of the splenic artery (*vide* Arterial System).

The *veins* terminate in the portal, superior mesenteric and splenic veins.

The *nerves* are derived from the gastric plexuses (Auerbach's and Meissner's plexuses, in the muscular and submucous coats, respectively), formed by the terminal branches of the right and left pneumogastric, and the branches of the celiac plexus, an offshoot of the solar plexus of the sympathetic.

THE SMALL INTESTINE (INTESTINUM TENUE).

The small intestine is a convoluted tube about twenty to twenty-five feet in length, for the chylification of the food, occupying the lower and central portions of the abdominal and pelvic cavities, and held in position to the spinal column by the mesentery. It is divided into three portions—the duodenum, jejunum and ileum.

THE DUODENUM, so called from being in length about twelve fingers' breadth, is about eight to ten inches long. It consists of four portions, from the position of its course—ascending, descending, transverse and terminal ascending:—

The first, ascending or superior portion (*pars superior*) is about two inches in length, and ascends to the neck of the gall-bladder. It is completely invested by peritoneum for about an inch.

The second or descending portion (*pars descendens*), about three inches in length, descends in front of the right kidney as far as the third or fourth lumbar vertebra, and is overlapped in front by the head of the pancreas, and into its posterior aspect, the duct of the pancreas and the common biliary duct open by a common orifice.

The *third, preaortic, horizontal* or *transverse portion* is attached to the crura of the diaphragm and the vessels in front of the vertebral column, passes behind the transverse mesocolon,

and has the pancreas above it, while the superior mesenteric blood vessels cross from beneath the latter between the two, or over the duodenum.

The fourth or terminal ascending portion (*pars ascendens*) runs upward and forward to the duodenojejunal flexure.

The *arteries* are derived from the inferior pancreaticoduodenal branch of the superior mesenteric and the superior pancreaticoduodenal branch of the gastroduodenal, a branch of the hepatic. The *veins* terminate in the superior mesenteric and splenic veins. The *nerves* are from the solar plexus.

THE JEJUNUM (*intestinum jejunum*), named from *jejunus*, empty, includes the upper two-fifths of the small intestine, is continuous above with the duodenum and below with the ileum. It occupies chiefly the left iliac and umbilical region.

THE ILEUM (*intestinum ileum*), so called from its twisted appearance, includes the remaining three-fifths, is continuous above with the jejunum and below with the caput cecum of the large intestine. It occupies the right iliac, hypogastric and umbilical regions.

The *structure* of the small intestine consists of four coats—the serous, muscular, fibrous or areolar and mucous:—

The serous coat (*tunica serosa*) is the peritoneal covering;

The muscular coat (*tunica muscularis*) consists of two sets—a longitudinal and a circular;

The areolar or submucous coat (*tela submucosa*) connects the muscular with the mucous coat;

The mucous coat (*tunica mucosa*) is thinner and redder than that of the stomach, and is thrown into numerous transverse folds—the valvulæ conniventes—most numerous in the upper part; they diminish as it descends and finally disappear in the ileum. They increase the secreting and absorbing surface of the mucous membrane and retard the passage of the food.

The *mucous membrane* also contains the villi and four kinds of glands:—

Simple follicles, or crypts of Lieberkühn;
Duodenal glands, or Brunner's glands;
Solitary glands;
Agminate, or Peyer's glands.

The villi (*villi intestinales*) are minute vascular projections of the mucous membrane scattered throughout the surface of the small intestine. Their structure consists of a pouch-like termination of a lacteal in the center, surrounded by a minute plexus of capillary vessels, inclosed in a basement membrane and covered with columnar epithelium.

The simple follicles, or crypts of Lieberkühn (*glandulæ intestinales* [*Lieberkühni*]), are scattered throughout the mucous membrane of the entire small intestine. They consist of minute tubes of basement membrane, lined with columnar epithelium and surrounded by a capillary network.

The duodenal or Brunner's glands (*glandulæ duodenales* [*Brunneri*]) are distributed to the doudenum and jejunum only. They are largest and most numerous in the vicinity of the pylorus. They are composed of tubular alveoli, lined by epithelium, and having a small duct opening on the mucous membrane.

The solitary glands (*noduli lymphatici solitarii*) are distributed throughout the small intestine, being most numerous in the last portion of the ileum. They consist of lymph follicles, and communicate with the lacteal system by means of lymph spaces.

Peyer's glands, or Peyer's patches (*noduli lymphatici aggregati* [*Peyeri*]), consist of an aggregation of the solitary glands into oval groups of twenty or thirty, along the small intestine at a point opposite the attachment of the mesentery. The patches are about fifteen to thirty in number, each measuring about one-half to two inches in length and one-half inch in breadth. Their axes are parallel with the length of the intestine. In the duodenum they are few and small in size, and the mucous membrane of the valvulæ conniventes over them is reduced in size and much distorted.

The *arteries* are derived from the pyloric, pancreaticoduodenal and superior mesenteric. They reach the intestines inclosed in and along the course of the mesenteries. In the intervals of the coats they form three vascular nets, which supply the serous, muscular and mucous coats. The *veins* accompany the arteries and join the portal vein.

The *lymphatics* follow the course of the superior mesenteric vessels to enter the mesenteric glands.

The *nerves* are derived from the solar plexus of the sympathetic.

THE LARGE INTESTINE (INTESTINUM CRASSUM).

The large intestine is about five feet long and extends from the ileum to the anus.

It commences in the right iliac fossa, ascends through the right lumbar and right hypochondriac regions, passes transversely between the epigastric and umbilical regions to the left

hypochondriac region, where it descends through the left hypochondriac, lumbar and iliac regions, and through the pelvis on its posterior wall to terminate at the anus.

It consists of three divisions:—

1. Cecum.
2. Colon, { Ascending, Transverse, Descending, Sigmoid flexure.
3. Rectum.

THE CECUM (*intestinum cæcum*) is a blind pouch measuring about two and one-half inches in every diameter, lying free in the right iliac region.

It has opening into its lower back part the appendix vermiformis, and into its inner back part the ileum, guarded by the ileocecal valve.

The appendix vermiformis (*processus vermiformis*) is a long, narrow, twisted tube, the rudiment of the prolonged cecum in all mammalia. It terminates in a blunt extremity. Its mucous membrane is continuous with that of the cecum, and contains many solitary glands.

The ileocecal valve (*valvula coli*), or valve of Bauhin, protects the opening of the ileum into the cecum, and consists of two valve-like semilunar folds of mucous membrane, strengthened by bands of circular fibers. The upper one is attached to the junction of the ileum with the colon, the lower one to the junction of the ileum with the cecum. On each side where the folds coalesce, a ridge of mucous membrane, continuous for a short distance around the canal, forms the frenulum or retinaculum (*frenum valvulæ coli*) of the valve. The mucous membrane on either side of the valves corresponds to that of the large and small intestines respectively, being covered with villi on the side toward the ileum, and being destitute of villi, and containing numerous tubular glands or crypts of Lieberkühn, on the side toward the cecum. This difference occurs abruptly at the free margin of the valves.

THE COLON consists of four portions—ascending, transverse, and descending colon and sigmoid flexure:—

The ascending portion (*colon ascendens*) begins opposite the ileocecal valve, ascends through the right lumbar and hypochondriac regions, and terminates beneath the under surface of the liver at the hepatic flexure (*flexura coli dextra*) in the transverse portion. Its posterior surface is destitute of peri-

toneum, and is attached to the quadratus lumborum muscle by loose areolar tissue.

The transverse portion, or transverse arch of the colon (*colon transversum*), passes from the hepatic flexure, through the adjoining portions of the epigastric and umbilical regions, to terminate at the splenic flexure (*flexura coli sinistra*) in the descending portion. It is attached by transverse mesocolon, and is the most movable portion of the colon.

The descending portion (*colon descendens*) begins at the splenic flexure, descends through the left lumbar and iliac regions to terminate in the sigmoid flexure. Like the ascending colon, its posterior surface is destitute of peritoneum.

The sigmoid flexure—omega loop—(*colon sigmoideum*) is a narrow, twisted portion of the colon, occupying the left iliac fossa, between the descending portion of the colon and the rectum. It is held in position by the sigmoid mesocolon. It terminates opposite the third sacral vertebra.

The rectum (*intestinum rectum*)—the terminal portion—extends from the sigmoid flexure to the anus. It is four to six inches in length, not sacculated, but club-shaped, with its large extremity downward, and consists of two portions—superior and inferior:—

The lower four inches, formerly described as the upper portion of the rectum, rest upon the sacral plexus of nerves and the pyriformis muscle;

The *superior portion,* about three and three-quarters inches, is in relation in the male with the bladder, prostate gland and vesiculæ seminalis; in the female with the uterus and vagina, being adherent to the latter;

The *inferior portion,* about one and one-quarter inches, turns backward and terminates in the anus. It is supported by the levator ani muscle, and is surrounded by the internal and external sphincters of the anus. The *structure* of the large intestine consists of four coats—serous, muscular, cellular and mucous:—

The serous coat (*tunica serosa*), derived from the peritoneum, invests completely the transverse and sigmoid portions of the colon, but only partially the others, being absent in the posterior surfaces of the ascending and descending portions, and on the superior part of the rectum. The inferior surface of the rectum is without peritoneal covering. The *appendices epiploicæ* are folds of serous membrane filled with fat and attached chiefly to the transverse colon.

The muscular coat (*tunica muscularis*) consists of longitudinal fibers arranged into three flat bands, shorter by nearly one-half than the intestine itself, and the *circular*, distributed more evenly, but accumulated at points, producing with the former a sacculated condition.

The *cellular coat* connects the mucous with the muscular coat beneath.

The mucous coat (*tunica mucosa*) is smooth, destitute of villi and valvulæ conniventes, and thrown into numerous folds, two to four of which, situated in the rectum, have received the name of Houston's valves (*plicæ transversales recti*).

It contains crypts of Lieberkühn, more numerous here than in the small intestine, and solitary glands scattered throughout, but most numerous in the appendix and cecum, where some of them are accumulated into Peyer's patches.

The *arteries* of the cecum and colon are from the mesenteric. The *lymphatics* empty into the mesenteric glands, and the *nerves* are derived from the mesenteric plexus of the sympathetic system.

The *arteries* of the rectum are the hemorrhoidal branches of the inferior mesenteric, internal iliac and internal pudic. The *veins* form the hemorrhoidal plexus, and empty into the inferior mesenteric and internal iliac veins.

The *lymphatics* go to the sacral and lumbar glands, and the nerves are from the hypogastric plexus of sympathetic and contiguous spinal nerves.

THE PANCREAS.

The pancreas is an oblong, compound, racemose gland, about six to eight inches in length, one and one-half inches in breadth, and one-half to one inch in thickness, situated across the back part of the epigastric and left hypochondriac regions. Its weight varies from two to six ounces.

It consists of a head, body and tail:—

The head (*caput pancreatis*), or right extremity, is received into the concavity of the duodenum. The *lesser pancreas*, a detached portion of the gland, lies behind it.

The *tail*, or *lesser end*, terminates above the left kidney and suprarenal capsule, in contact with the spleen.

The body (*corpus pancreatis*) is in relation in front with the stomach and transverse mesocolon; behind it rests upon the first lumbar vertebra, having interposed the crura of the diaphragm, vena cava, left renal vein, aorta, superior mesenteric

artery and vein, the inferior mesenteric vein and commencement of portal vein.

The splenic artery and vein are lodged in a groove on its upper border.

The pancreatic duct, or canal of Wirsung (*ductus pancreaticus* [*Wirsungi*]), runs throughout the substance of the organ, to emerge at the head, and open into the duodenum by an orifice in common with the ductus communis choledochus. The lesser pancreas, when it exists, empties by the *ductus pancreaticus minor*.

The *structure* resembles that of the salivary glands, but is softer and looser.

Arteries are from the splenic and pancreaticoduodenal branches of the hepatic and superior mesenteric.

The *veins* join the splenic or superior mesenteric.

The *nerves* are from splenic plexus of the sympathetic.

The *lymphatics* empty into the lumbar glands.

THE LIVER (HEPAR).

The liver is the largest gland in the body, measuring in its transverse diameter from ten to twelve inches, and its anteroposterior six to seven, and its thickest part about three inches, and weighing about from three to four pounds. It occupies the upper part of the abdominal cavity, and the right hypochondriac, epigastric, and a portion of the left hypochondriac regions. Its upper surface is convex and rests against the diaphragm and a small portion of the abdominal parietes in front. Its lower, or visceral surface (*facies inferior*), is in contact with the duodenum and stomach, the right kidney and suprarenal capsules, and the hepatic flexure of the colon. It is divided by the longitudinal fissure into the right and left lobes (*lobuli hepatis*). The liver has five fissures, five lobes, five ligaments, five sets of vessels, and is inclosed in a fibrous coat, continuous at the transverse fissure with the capsule of Glisson. It is also invested by the peritoneum, except at the attachment of the coronary ligament.

Structure.—The liver is made up of lobules, which are small, granular bodies about one-fifteenth of an inch in diameter, held together by delicate connective tissue and the branches of the five sets of vessels (to be described) and nerves, the whole being inclosed in a serous and fibrous coat.

Each lobule is made up of a mass of polyhedral, nucleated cells, inclosed in a capillary plexus derived from the hepatic

artery and portal vein, and giving origin to the hepatic vein and biliary duct.

The five fissures of the liver are all situated on its under surface. They separate the five lobes from one another. They are:—

1. Longitudinal fissure (*fossa longitudinalis sinistra*) extends from before backward, from the notch in front to the posterior border. It is sometimes called the umbilical fissure (*fossa venæ umbilicalis*), and lodges the round ligament, the remains of the fetal umbilical vein.

2. Fissure for the ductus venosus (*fossa ductus venosi*) is

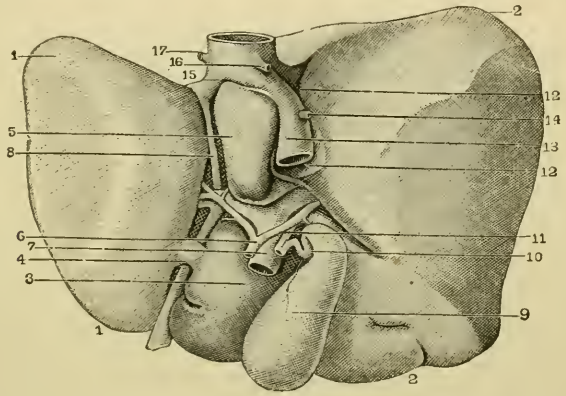

FIG. 92

1, left lobe; 2, right lobe; 3, quadrate lobe; 4, caudate lobe; 5, Spigelian lobe; 6, hepatic artery; 7, portal vein; 8, fissure of ductus venosus; 9, gall-bladder; 10, cystic duct; 11, hepatic duct; 12, fissure for vena cava; 13, vena cava; 14, right inferior phrenic vein; 15, hepatic vein; 16, right renal vein; 17, left renal vein.

the posterior portion of the longitudinal fissure, and lodges the remains of the ductus venosus of fetal life.

3. Transverse fissure, or portal fissure (*porta hepatis*), crosses the inferior surface of the liver transversely and joins the longitudinal. It transmits the portal vein, hepatic artery and nerves, and the hepatic duct and lymphatics.

4. Fissure for the gall-bladder (*fossa vesicæ felleæ*) is a shallow depression beneath the right lobe, running parallel with the longitudinal fissure in front.

Fissure for the vena cava (*fossa venæ cavæ*) runs obliquely upward along the inferior surface near its posterior margin to

the left side, joining the fissure for the ductus venosus behind, and separated from the transverse fissure in front by the lobulus caudatus. It lodges the inferior cava, which, within this fissure, receives the hepatic veins.

The five lobes of the liver are:—

Right lobe (*lobus hepatis dexter*), much the largest, is somewhat quadrilateral in outline, and presents three fissures and two depressions, the latter one for the right kidney and its suprarenal capsule, and the other for the hepatic flexure of the colon.

Left lobe (*lobus hepatis sinister*), smaller, is separated

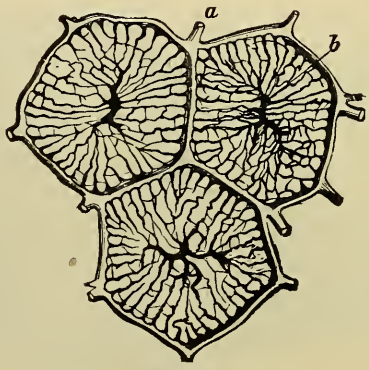

FIG. 93.

Transverse section of lobules of liver: (*a*), interlobular vein; (*b*), intralobular central vein.

from the right lobe by the longitudinal fissure, and is in contact with the stomach.

Lobulus quadratus, or square lobe, occupies the anterior border of the under surface of the right lobe, between the umbilical fissure and the fissure for the gall-bladder, and in front of the transverse fissure.

Lobulus Spigelii (*lobus caudatus* [*Spigeli*]) occupies a similar position to the quadrate lobe, along the posterior border, immediately back of it, from which it is separated by the transverse fissure. It is bounded laterally by the fissures for the ductus venosus and vena cava.

Lobulus caudatus, or tailed lobe, unites the lobus Spigelii with the right lobe, and separates the transverse fissure from the fissure for the vena cava.

The five ligaments of the liver are folds of peritoneum except one, the round ligament, which is the remains of the umbilical vein and ductus venosus of the fetus.

They are:—

1. Longitudinal or falciform ligament (*ligamentum falciforme hepatis*) consists of two layers of peritoneum, attached by one margin to the under surface of the diaphragm, and the sheath of the right rectus muscle, and is attached to the liver along its anterior margin, from the notch to its posterior border.

2 and 3. The lateral ligaments (*ligamenta triangulare dextrum et sinistrum*), one on either side, are triangular layers of peritoneum, attached to the lateral edges of the liver toward its posterior margin.

4. The coronary ligament (*ligamentum coronarium hepatis*) is formed of two layers, continuous with the lateral ligament and with the longitudinal ligament, connecting the posterior border of the liver to the diaphragm.

5. The round ligament (*ligamentum teres hepatis*) is a fibrous cord, the remains of the obliterated umbilical vein and ductus venosus, extending from the umbilicus to the longitudinal fissure, extending as far back as the inferior vena cava.

The five sets of vessels are the hepatic artery, portal vein, hepatic veins, hepatic ducts and lymphatics:—

The *hepatic artery,* the nutrient vessel of the liver, one of the branches of the celiac axis, enters the transverse fissure, and after giving off branches to the capsule of Glisson (*capsula fibrosa* [*Glissoni*]), and to the capsule, divides into interlobular branches, which form plexuses around each lobule, and terminate in capillaries between the cells, anastomosing with the capillaries of the portal vein.

The *portal vein* enters at the transverse fissure, divides into two branches, and finally terminates in the interlobular plexuses, already described. These all unite into one vein—*intralobular vein*—traversing the center of the lobule to join the *sublobular vein,* the latter ending in the *hepatic veins.* These latter finally terminate in the inferior vena cava.

The hepatic ducts (*ductus hepaticus*) originate between the hepatic cells as *bile capillaries,* minute canals without walls, and form a plexus between the lobules. From these plexuses ducts converge and unite to finally form the *hepatic duct.*

The *lymphatic vessels* form two sets—the superficial, those upon the surface of the organ; and deep, those accompanying the branches of the hepatic arteries and portal vein.

The gall-bladder (*vesica fellea*) is a conical membranous sac attached to the under surface of the right lobe of the liver, and partly covered by peritoneum. It measures about four inches by one, and has a capacity of about nine drachms. It consists of a fundus (*fundus vesicæ felleæ*), or rounded extremity, a body (*corpus vesicæ felleæ*) and neck (*collum vesicæ felleæ*), and has three coats—a fibrous, muscular and mucous—the latter lined with columnar epithelium.

The neck terminates in the cystic duct, the mucous membrane of which is thrown into a series of folds, forming a *spiral valve.*

The ductus communis choledochus (*ductus choledochus*), or common biliary duct, about three inches long and the diameter of a goose-quill, is formed by the union of the hepatic, about two inches in length, and the cystic (*ductus cysticus*), about one inch in length. It empties into the descending portion of the duodenum in common with the pancreatic duct, about three and one-half inches below the pylorus.

THE DUCTLESS GLANDS.

The following group includes the glands without ducts[1] which resemble each other in structure:—

Spleen,	Thymus,
Thyroid,	Suprarenal capsules,
Pituitary body,	Glandula coccygea,
Glandula intercarotica.	

The Spleen (Lien).—The spleen is a soft, very vascular, sponge-like organ, situated deeply in the left hypochondriac region. It varies much in size and weight, measuring about five inches in length, three in width, one and one-half in thickness, and weighing between seven and ten ounces.

Outer surface (*facies diaphragmatica*), smooth and convex, corresponds to the ninth, tenth, and eleventh ribs, and is adapted to the inferior surface of the diaphragm, to which it is connected by the suspensory ligament.

Inner surface is concave and adapted to the cardiac end of the stomach, to which it is attached by the gastrosplenic omentum.

[1] Formerly it was taught that these glands were enigmatic in nature; more recently, however, it was discovered that they elaborate substances which are added to the blood and lymph, and which are designated "internal secretions." These internal secretions play a dominant rôle in maintaining a balance in the economy.

Hilus (*hilus lienis*) is a vertical fissure on the concave inner surface, admitting the passage of blood vessels, lymphatics and nerves. The *structure* consists of two coats—a serous and fibroelastic coat, inclosing in its interior the spleen pulp.

Serous coat (*tunica serosa*), derived from the peritneoum, covers the entire organ, except at the hilus, where it forms the gastrosplenic omentum.

Fibroelastic coat, or tunica propria (*tunica albuginea*), surrounds the organ, and from the hilus and periphery sends numerous fibrous bands, or trabeculæ (*trabeculæ lienis*), into the substance of the organ, dividing it into small *trabecular spaces,* or *areolæ.*

Splenic substance, or spleen pulp (*pulpa lienis*), is a soft, reddish-brown mass, consisting of a fine reticulum of connective-tissue corpuscles, inclosing red and white blood corpuscles, nucleated and non-nucleated cells, granular matter, etc.

Malpighian corpuscles, or bodies (*noduli lymphatici lienales* [*Malpighii*]), are spheroidal hyperplasiæ of lymphoid tissue from the outer coat of the arterioles. They are not encapsuled, vary from one-sixtieth to one-twenty-fifth of an inch, and are visible in the fresh specimens to the naked eye.

Splenic artery, remarkable for its size and tortuosity, divides in the hilus into four or five branches, each distributed to a segment, terminating in a capillary plexus without anastomoses, or opening directly into the areolæ of the splenic pulp.

Splenic vein commences in the same manner as the arterioles end, and empties into the portal vein. The smaller veins anastomose freely.

Nerves are from the splenic plexus, formed from the right pneumogastric nerve, and the left semilunar ganglion of the solar plexus.

Thyroid Gland (*glandula thyreoidea*).—The thyroid is a vascular, gland-like body, situated on the sides of the upper part of the trachea, and consists of *two lateral lobes* connected by a transverse portion, the isthmus (*isthmus glandulæ thyreoidea*).

A third lobe—the *pyramid*—sometimes arises from the left lobe or upper margin of the isthmus.

Levator glandulæ thyreoideæ are muscular bands sometimes found passing from the isthmus to the body of the hyoid bone.

Structure.—This is similar to other glands, being made up of a capsule and radiating septa inclosing alveoli—the closed *vesicles*—each of which is lined with one layer of columnar epithelium, and contains more or less viscid, transparent fluid—the *colloid substance.* The closed vesicles are abundantly sup-

plied with blood by meshes of capillaries, while penetrating the septa are lymphatic networks, and lymph sinuses are found in the tissue between the vesicles and septa.

Arteries are the superior thyroid, a branch of external carotid, and inferior thyroid, a branch of the thyroid axis, and sometimes a branch from the arch of the aorta or innominate artery, the middle thyroid, or arteria thyroidea ima. All the vessels anastomose freely.

Veins form plexus about the gland and give off the superior and middle thyroid to internal jugular, and inferior thyroid to innominate vein.

Nerves, from middle and inferior cervical ganglia and from pneumogastric.

Thymus Gland.—The thymus gland is a temporary organ which attains its full size at the end of two years and at puberty has almost disappeared. It occupies the upper part of the anterior mediastinum, and is in relation in front with the sternum, and below with the pericardium, aorta, left innominate and trachea. It is a flat, triangular body, composed of a pair of lateral unequal lobes, about two inches in length, one and one-half inches at the widest part, and one-quarter inch thick, and weighing about one-half ounce.

Structure.—It is composed of a framework of fibroconnective tissue, consiting of a capsule, septa and gland substance, which is divided into lobes, these into lobules, and these latter into units or follicles.

The follicles vary in shape, present for study a *cortex* and *medulla,* and consist of adenoid tissue.

The cortical meshes of the reticulated adenoid tissue are filled with lymph-corpuscles, while in the medulla the meshes are less numerous and filled with large endothelioid plates and giant cells.

The capillary blood-vessels surrounded the follicles.

Arteries are from superior and inferior thyroid and internal mammary.

Veins join thyroid and left innominate veins.

Nerves are from sympathetic and pneumogastric.

Suprarenal Capsules (*glandulæ suprarenalis*).—The suprarenal capsules are two small, triangular bodies, situated upon the upper and front part of either kidney. They measure from one and one-quarter to two inches in length, and less in breadth, two to three lines in thickness, and weigh about two drachms.

Structure.—Like the kidneys, they consist of a cortical and medullary portion, inclosed in a capsule which sends septa into the substance of the body.

The cortex (*substantia corticalis*) is composed of three zones of epithelial cells—outer, middle and inner—the middle being the largest.

The medulla (*substantia medullaris*) consists of streaks of small, transparent cells, separated by connective tissue and capillaries. These streaks are continuous with the inner zone of the cortex. The nerve supply is rich, consisting of non-medullated fibers connected with small ganglia.

Relations.—The inferior concave border rests upon the upper surface of the kidney. The inner border rests against the inferior vena cava on the right side, the aorta on the left, and is in relation with semilunar ganglion and great splanchnic nerves.

The anterior surfaces touch on the right the under surface of the liver, and on the left side the pancreas and spleen. The posterior surface lies upon the crus of the diaphragm, about opposite the tenth dorsal vertebra.

Arteries are suprarenal from the aorta, the renal and phrenic arteries.

Veins on the right join vena cava, on left renal vein.

Nerves, from renal and solar plexus.

Pituitary body (*hypophysis cerebri*) is a small, vascular mass on the inferior surface of the cerebrum, but resembling in structure the ductless glands.

Structure.—The upper lobe is part of the central nervous system. The lower and larger lobe has a fibrous capsule which sends processes into the interior, forming minute septa; these divide and reunite around spaces called alveoli. The alveoli contain epithelial cells of various shapes, between which are small irregular cells having flattened nuclei.

The glandula coccygea (*glomus coccygeum*), lying near the tip of the coccyx, and the intercarotica, or carotid gland or body (*glomus caroticum*), at the angle of bifurcation of the common carotid, have been recently included among the ductless glands. They were both discovered by Luschka. The framework of their bodies is identical with that of other glands, except that the septa contain non-striped muscular tissue. The alveoli are filled with gland substance, consisting of connected masses of epithelial cells, having in their center a twisted capillary blood vessels.

VOCAL AND RESPIRATORY APPARATUS.

THE LARYNX is a musculocartilaginous box at the top of the trachea, below the root of the tongue and the hyoid bone, and is the organ of the voice. It is composed of cartilages (*cartilagines laryngis*) connected by ligaments, provided with muscles, blood-vessels and nerves, and lined with mucous membrane. The cartilages are nine in number, three single and three pairs:—

Thyroid,
Cricoid,
Epiglottis,
Two arytenoid,
Two cornicula laryngis,
Two cuneiform.

The thyroid (*cartilago thyreoidea*), the largest cartilage, consists of two quadrilateral halves, united in front in the median line, or entering angle of the thyroid, the upper part of which is the pomum Adami (*prominentia laryngea*). The outer surface is marked by an oblique ridge (*linea obliqua*) for the attachment of muscles. The inner surface is smooth and covered by mucous membrane, and has in front attached the true and false vocal cords. The posterior angles are prolonged into superior (*cornu superius*) and inferior horns (*cornu inferius*), the superior giving attachment to the thyrohyoid ligament, the inferior articulating with the sides of the cricoid cartilage.

The cricoid cartilage (*cartilago cricoidea*) resembles a seal ring, narrow in front, or anterior portion (*arcus cartilaginis cricoideæ*), the back part of the upper border articulates with the arytenoid cartilage, and on each side externally are two facets for the articulation of the inferior horns of the thyroid.

The epiglottis (*cartilago epiglottica*) is a spoon-shaped, fibrocartilaginous plate, large above, its narrow inferior extremity is prolonged and attached by a band of fibroelastic tissue of thyroepiglottic ligament (*ligamentum thyreoepiglotticum*) to the thyroid cartilage. It is also attached to the posterior surface of the hyoid bone by the hyoepiglottic ligament (*ligamentum hyoepiglotticum*). The anterior or lingual surface has three reflections of mucous membrane between it and the tongue

(*plicæ glossoepiglotticæ*), called the glossoepiglottidean ligaments (*ligamentum glossoepiglotticum*).

The arytenoid cartilages (*cartilagines arytænoideæ*) each resembles the mouth of a pitcher, from which they are named. They are smaller than the other two, and are situated on the summit of the cricoid cartilage posteriorly. They are three-sided, the apex extends backward, and is surmounted by the supra-arytenoid, cornicula laryngis, or cartilages of Santorini (*cartilagines corniculatæ*).

The *posterior surface* has attached to it the arytenoid muscle. The *anterior surface* has attached to it the thyroarytenoid muscle and the false vocal cord. The *internal surfaces* are opposed to each other and supplied with mucous membrane. Of the *three angles* at the base, the outer gives attachment to the cricoarytenoid muscle, lateral and posterior. The anterior (*processus vocalis*) is prolonged for attachment of the true vocal cord.

The cuneiform cartilages (*cartilagines cuneiformes*), or cartilages of Wrisberg, are two small rod-shaped bodies extending upward from the arytenoid cartilages into the arytenoepiglottidean fold (*plica aryepiglottica*).

The cartilages of the larynx, with the exception of the epiglottis, are composed of true cartilage.

The LIGAMENTS of the LARYNX are divided into two sets—the extrinsic, those connecting the epiglottis and thyroid cartilage with the hyoid bone, and the intrinsic, those which connect the various cartilages together. The *extrinsic* consist of three:—

1. Thyrohyoid membrane (*membrana hyothyreoidea*), connecting the upper border of the thyroid cartilage with the inner surface of the hyoid bone;

2 and 3. The two lateral thyrohyoid ligaments (*ligamentum hyothyreoideum laterale*), fibroelastic cords connecting the superior horns of the thyroid cartilage with the extremities of the great horns of the hyoid bone. They contain a small nodule, the *cartilago triticea*.

The *intrinsic ligaments* are sixteen in number, as follows:—

Hyoepiglottic ligament;
Cricothyroid membrane;
Two cricothyroid capsular ligaments;
Two cricoarytenoid ligaments;
Two cricoarytenoid capsular ligaments;
Two superior thyroarytenoid ligaments (in false cords);
Two inferior thyroarytenoid ligaments (in true cords);
Thyroepiglottic ligament;
Three glossoepiglottic folds.

The hyoepiglottic ligament (*ligamentum hyoepiglotticum*) is a fibroelastic band, connecting the anterior surface of the epiglottis with the upper border of the hyoid bone. The *ligaments* connecting the cricoid to the thyroid cartilage are three also—the cricothyroid ligament, capsular ligaments and synovial membranes.

The cricothyroid membrane (*conus elasticus*), a yellow, elastic band, connects the adjacent margins of the cricoid and thyroid cartilages, and extends from the upper border of the cricoid cartilage to the lower margin of the true vocal cords.

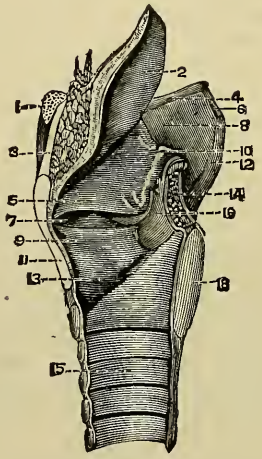

FIG. 94.

Vertical section of larynx: 1, body of hyoid bone; 2, epiglottis; 3, thyrohyoid membrane; 4, great cornu of hyoid; 5, false vocal cord; 6, thyrohyoid ligament; 7, ventricle of larynx; 8, thyrohyoid membrane; 9, true vocal cord; 10, arytenoepiglottidean fold; 11, thyroid cartilage; 12, superior cornu of thyroid; 14, arytenoid muscle; 16, arytenoid cartilage; 18, cricoid cartilage.

The two cricothyroid capsular ligaments (*articulatio cricothyreoidea*) surround the articulations between the inferior horns of the thyroid and the cricoid cartilage.

The synovial membrane (*capsula articularis cricothyreoidea*) lines the capsular ligaments, forming a true enarthrodial joint.

The ligaments of the epiglottis are the thyroepiglottic (*ligamentum thyreoepiglotticum*), the hyoepiglottic (*ligamentum hyoepiglotticum*), and the three glossoepiglottic folds (*plicæ glossoepiglotticæ*) of mucous membrane before described.

The superior aperture (*aditus laryngis*) of the larynx is a triangular opening with the apex in front. It is bounded behind by the apices of the arytenoid cartilages and corniculæ laryngis, in front by the epiglottis, and laterally by the arytenoepiglottidean folds. From this, as its superior boundary, the cavity of the larynx extends as low as to the lower border of the cricoid cartilage. The true vocal cords and the thyroarytenoid muscle divide it into two parts, the narrow fissure between the two cords being called the chink of the glottis (*rima glottidis*).

The superior or false vocal cords (*plicæ ventriculares*) are two folds of mucous membrane inclosing the superior thyroarytenoid ligaments (*ligamentum ventriculare*).

The inferior or true vocal cords (*plicæ vocalis*) are two folds of mucous membrane inclosing the inferior thyroarytenoid ligaments, composed of elastic tissue, from the sides of the upper border of the cricoid cartilage, extending upward to the bases of the arytenoid cartilages, and lower portion of the angle of the thyroid. Their upper margins correspond to the lower edges of the ventricles of the larynx.

The ventricle of the larynx (*ventriculus laryngis* [*Morgagnii*]) is a deep fossa on either side of the larynx, bounded above by the false vocal cords, below by the inferior or true vocal cords, and externally by the thyroarytenoideus muscle.

The sacculus laryngis (*appendix ventriculi*), or laryngeal pouch, is a membranous sac lined with mucous membrane, opening into the anterior portion of the ventricle of the larynx. Its inner or laryngeal surface is covered by the arytenoepiglottideus inferior (*compressor sacculi laryngis* [*Hilton*]), and the outer side by the thyroepiglottideus and thyroarytenoideus muscles. It is compressed by these muscles, discharging its mucous secretion upon the true vocal cords.

Muscles.—The *intrinsic muscles of the larynx* consist of two sets, five connected with the vocal cords and rima glottidis, and three with the epiglottis. The *five muscles* of the *vocal cords* are:—

Cricothyroid (*m. cricothyreoideus*).—*Origin,* from the front and sides of the cricoid cartilage; *insertion,* into anterior border of the inferior cornua, and lower margin of the thyroid cartilage; *action,* elongates and renders tense the vocal cords; *nerve,* superior laryngeal.

Cricoarytænoideus Posticus (*m. cricoarytænoidus posterior*).—*Origin,* from the sides and posterior surface of the cricoid cartilage; *insertion,* into the outer angle of the base of arytenoid cartilage; *action,* rotates the arytenoid cartilages out-

ward, opening the glottis, and rendering tense the vocal cords; *nerve,* recurrent laryngeal.

Cricoarytænoideus Lateralis (*m. cricoarytænoideus lateralis*).—*Origin,* from upper and outer side of the cricoid cartilage; *insertion,* in front of the preceding into the outer angle of the base arytenoid; *action,* rotates the arytenoids inward, closing the glottis; *nerve,* recurrent laryngeal.

Arytænoideus.—*Origin,* from outer border and posterior surface of one arytenoid cartilage; *insertion,* into the same part of the other—its fibers are oblique (*m. arytænoideus obliquus*), and transverse (*m. arytænoideus transversus*); *action,* by approximating the arytenoids closes the back part of the glottis; *nerves,* superior and recurrent laryngeal.

Thyroarytænoideus (*m. thyroarytænoideus*).—*Origin,* from the cricothyroid membrane and lower half of the entering angle of the thyroid cartilage; *insertion,* into anterior surface and base of the arytenoid cartilage—it consists of inferior (*m. vocalis*) and superior portions, the former entering into the formation of the true vocal cords; *action,* mainly relaxes the true vocal cords by drawing the arytenoids forward; *nerve,* recurrent laryngeal.

The muscles of the epiglottis are:—

Thyroepiglottideus (*m. thyreoepiglotticus*).—*Origin,* from the inner surface of thyroid cartilage; *insertion,* into the margin of epiglottis and arytenoepiglottidean fold; *action,* compress the sacculus laryngis and depress the epiglottis; *nerve,* recurrent laryngeal.

Arytænoepiglottideus Superior.—*Origin,* from apex of arytenoid; *insertion,* into arytenoepiglottidean folds; *action,* constricts the superior laryngeal aperture; *nerve,* recurrent laryngeal.

Arytænoepiglottideus Inferior, or Compressor Sacculi Laryngis of Hilton.—*Origin,* from middle of internal portion of the arytenoid; *insertion,* into upper and inner part of epiglottis; *action,* compresses the sacculus laryngis; *nerve,* recurrent laryngeal.

The lining *mucous membrane* of the larynx is continuous with that of the pharynx and trachea. It forms the glosso-epiglottic and arytenoepiglottic folds, adheres tightly to the epiglottis, vocal cords and the interior of the cricoid cartilage, but is more loosely attached to other parts. It contains numerous racemose glands, particularly along the posterior margin of the arytenoepiglottidean fold, and in front of the arytenoid cartilages, where they are called the *arytenoid glands.* Its epithe-

lium is of the ciliated, columnar variety below the true vocal cords, and above this point in front as high as the middle of the epiglottis. The other portions are covered by squamous epithelium.

The *arteries* are the laryngeal branches from the superior and inferior thyroid, and the cricothyroid branches of the superior thyroid.

The *veins* join the inferior, middle and superior thyroid veins.

The *lymphatics* enter the deep cervical glands.

The *nerves* are the inferior or recurrent laryngeal, the superior laryngeal branches of the pneumogastric and branches from the sympathetic nerve.

The *superior laryngeal* supplies sensation to the larynx. It descends from the inferior ganglion of the pneumogastric, behind the internal carotid at the side of the pharynx, and divides into two branches—the *internal laryngeal* pierces the thyrohyoid membrane to supply the mucous membrane and arytenoid muscle, the *external laryngeal* supplies the cricothyroid muscle.

The *inferior* or *recurrent laryngeal,* from its origin, winds around the subclavian on the right side and around the arch of the aorta on the left side, and ascends by the side of the trachea to the larynx, of which it is the motor nerve, supplying all the muscles of the larynx except the cricothyroid, giving off in its course cardiac, œsophageal, tracheal and pharyngeal branches, and anastomosing with the superior laryngeal nerve.

TRACHEA AND BRONCHI.

The *trachea,* or *windpipe,* is a membranocartilaginous tube, about four and a half inches in length, three-quarters to one inch in width, extending from the fifth cervical to the upper border of the fifth dorsal vertebra. It divides into two bronchi (*bifurcatio trachea*), the right (*bronchus dexter*), about an inch long and nearly at right angles, passing behind the right pulmonary artery on a level with the fifth dorsal vertebra; the left (*bronchus sinister*), narrower, about twice as long, passes beneath the arch of the aorta on a level with the fifth or sixth dorsal vertebra, behind the left pulmonary artery. The trachea and bronchi are formed of a series of cartilaginous rings, incomplete at their posterior third, connected by fibroelastic membrane, and lined by columnar ciliated epithelium. The last ring is triangular, so as to fit the rings of the two bronchi. The mucous membrane contains numerous racemose glands, the

largest on the posterior surface, called the tracheal glands (*glandulæ tracheales*). The muscular fibers consist of two layers, longitudinal, the most external, and transverse, internal, both unstriated.

Relations.—The trachea has the following relations in the neck:—

Laterally.

Lobes of the thyroid body;
Carotid arteries;
Inferior thyroid arteries.

Anteriorly.

Skin, superficial and deep fascia;
Anterior jugular veins;
Left innominate vein;
Inferior thyroid plexus of veins;
Isthmus of thyroid body;
Arteria thyroidea ima (sometimes).

Posteriorly.

Esophagus;
Vertebral column;
Recurrent and inferior laryngeal nerves.

The following in the thorax:—

Laterally.

Pleura;
Pneumogastric nerves.

Anteriorly.

Sternum;
Remains of thymus;
Arch of aorta;
Right and left innominate veins;
Left carotid artery;
Deep cardiac plexus.

Posteriorly.

Esophagus.

The *arteries* are derived from the inferior thyroid and bronchial.

The *veins* empty into the thyroid and bronchial plexuses.

The *nerves* are from the pneumogastric and sympathetic.

The *lymphatics* empty into the mediastinal glands.

The bronchi are the continuation of the trachea from its bifurcation to the hilus of the lung.

Right bronchus (*bronchus dexter*) is shorter, about one inch in length, placed more horizontally, and wider. It divides at the hilus into three short branches, corresponding to the divisions of the right lung.

Left bronchus (*bronchus sinister*) is longer, nearly two inches in length, placed more obliquely, and narrower than the right. It divides into two long branches corresponding to the number of lobes.

The two bronchi subdivide into the bronchial tubes, or bronchioles, which ramify throughout the lungs, dividing and subdividing (*bronchioli respiratorii*), to end finally in the primary lobules, where they communicate with the intercellular air-passages. Their cartilages consist of thin plates, distributed irregularly along the tubes, and in the finer tubes disappearing entirely. The mucous membrane of the bronchi and bronchial tubes is lined throughout with columnar ciliated epithelium.

The *arteries, veins, nerves* and *lymphatics* are the same as for the trachea.

THE LUNGS.

The lungs (*pulmones*), the organs of respiration, are two in number, occupying the lateral cavities of the chest, separated from each other by the heart and structures within the mediastinum. They accurately fill the cavity of the chest at all times, and are covered by the pleura. They are conical in shape, presenting each a base, apex, two borders, and two surfaces. The apex (*apex pulmonis*) extends upward above the level of the first rib; the base (*basis pulmonis*) occupies the convex surface of the diaphragm; the external, or thoracic surface (*facies costalis*), is accurately applied to the wall of the thorax; the inner surface (*facies mediastinalis*) is in contact with the pericardium, and is marked by a depression, the hilum pulmonis (*hilus pulmonalis*), at the root of the lungs. The *posterior border* rests on either side of the spinal column, and the *anterior border* is thin and overlaps the pericardium.

The root (*radix pulmonalis*) of each lung, situated near its middle, is composed of the following structures, surrounded by a reflection of pleura:—

Bronchus;
Pulmonary artery;
Pulmonary veins;
Bronchial glands;
Bronchial vessels;
Posterior and anterior pulmonary plexuses of nerves;
Connective tissue.

The root of the right lung is behind the right superior cava and the vena azygos arches over it. The root of the left lung lies below and in front of the arch and descending aorta. The relative positions of the pulmonary veins, pulmonary artery and bronchus on either side are:—

Both sides, from before backward—

V. Pulmonary veins,
A. Pulmonary artery,
B. Bronchus.

Right side, from above downward—

B. Bronchus,
A. Pulmonary artery,
V. Pulmonary veins.

Left side, from above downward—

A. Pulmonary artery,
B. Bronchus,
V. Pulmonary veins.

The weight of the lungs varies according to many conditions. In the adult the approximate weight is about forty-two ounces, the right being two ounces heavier than the left, and their total capacity about three hundred cubic inches. The right lung has three lobes, the left but two, of which the lower is the larger. The lungs in infancy are of a pale rose color, but later become of a leaden hue, variegated with dark slate and bluish black. They are highly elastic, crackle on pressure, and float in water, having a specific gravity of 0.345 to 0.746. In the fetus before birth, and also in certain diseases, they sink in water. The *structure* of the lung consists of an external serous coat, the visceral layer of the pleura, a subserous areolar tissue, highly elastic, and the parenchyma, or proper substance of the lungs. The latter is made up of small polyhedral primary lobules, which unite to form secondary lobules, the latter giving rise to the markings on the surface. Both the primary and secondary lobules are held together by connective tissue. A primary lobule represents the structure of the entire organ, consisting of a bronchiole (*bronchioli*) and infundibula, or air-passage, communicating with numerous air-cells.

The air-cells (*infundibula*) are minute polyhedral cavities, from one-two-hundredths to one-seventieth of an inch in diameter, separated from each other by a thin lamina, and communicating freely with the infundibula. They vary much in size, being largest on the surface at the thin borders and at the apices.

Each air-cell is composed of the basement membrane, lined with squamous epithelium, and surrounded by a minute capillary network of blood vessels, which intervene between the terminal branches of the pulmonary artery and the commencement of the pulmonary veins. Between the cells the capillary network forms a single layer.

The *pulmonary artery* conveys the venous blood to the lungs and terminates in the capillary network about the air-cells, from which proceeds the *pulmonary vein,* which passes

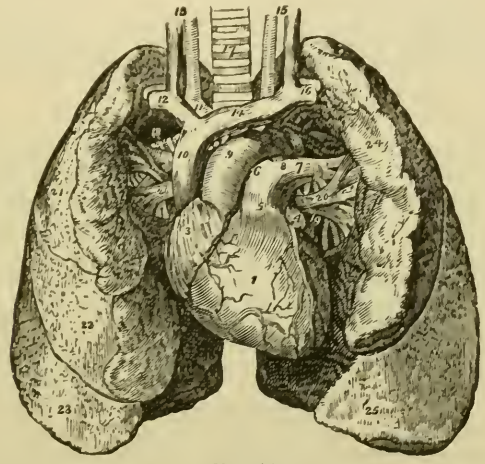

FIG. 95.

Heart and lungs: 1, right ventricle; 3, right auricle; 5, pulmonary artery; 9, aorta; 10, superior cava; 20, root of lung; 21, 22, 23, upper, middle and lower lobes of right lung; 24, 25, upper and lower lobes of left lung.

along the bronchial tubes to the left auricle of the heart. The *bronchial arteries* supply the structure of the lungs. They are derived from the aorta, and follow the course of the bronchial tubes, the *bronchial veins* returning the blood to terminate in the hemiazygos or superior intercostal vein on the left.

The *lymphatics* are numerous and consist of a superficial set converging to the root and a deep set along the course of the tubes, and both enter the bronchial glands.

The *nerves* are derived from the anterior and posterior pulmonary plexuses of the pneumogastric and sympathetic, the latter the larger. Ganglia are found upon these nerves.

THE PLEURÆ.

Each lung is invested by a delicate serous membrane, the pleura, which lines the internal wall of the thorax and is reflected at the root of the lung over that organ. It consists essentially of two layers, a parietal (*pleura parietalis*), or pleura costalis, and visceral (*pleura pulmonalis*). It adheres accurately to the subjacent structures, and is called, from its position, costal (*pleura costalis*), diaphragmatic (*pleura diaphragmatica*), mediastinal (*pleura mediastinalis*), and pulmonary. The space between the two layers of each pleura, known as the cavity of the pleura (*cavum pleuræ*), contains a thin, serous secretion.

A fold extending downward from the root of the lung to the diaphragm forms the so-called pulmonary ligament, or *ligamentum latum pulmonis.*

Each pleura is a closed sac; the right is wider, shorter and extends higher in the neck than the left. They do not meet in the median line, except opposite the upper part of the gladiolus, but have a space between them known as the mediastinum.

The *arteries* are from the intercostal, bronchial, pericardiac, internal mammary, musculophrenic and thymic.

The *veins* accompany the arteries.

The *lymphatics* are numerous, and empty into the intercostal and posterior mediastinal glands.

The *nerves* are from the phrenic and sympathetic.

MEDIASTINUM.

The mediastinum is the space left between the two pleuræ in the median line between the sternum and vertebral column, and contains the heart within its pericardium and all the thoracic viscera except the lungs. The intervals in the mediastinum from their position are named anterior, middle, posterior and superior mediastinal cavities. The boundaries and contents of the four mediastinal cavities are as follow:—

Anterior mediastinum, bounded in front by the sternum; laterally, pleura; behind, the pericardium. It contains:—

Triangularis sterni muscle;
Remains of thymus gland;
Left internal mammary artery and venæ comites;
Lymphatic vessels from convex surface of the liver;
Areolar connective tissue.

Middle mediastinum, bounded in front by the anterior mediastinum; laterally, by the pleura; behind, posterior mediastinum. It contains:—

Ascending portion of aorta;
Superior vena cava;
Heart, inclosed in the pericardium;
Bifurcation of trachea;
Pulmonary artery and veins;
Phrenic nerves;
Arteriæ comites nervi phrenici, from the internal mammary.

Posterior mediastinum, bounded in front by the pericardium and root of the lungs; behind, vertebral column; laterally pleura. It contains:—

Esophagus;
Thoracic duct;
Descending aorta;
Lymphatic glands and vessels;
Vena azygos major;
Vena azygos minor;
Superior intercostal veins;
Pneumogastric nerves;
Great splanchnic nerves.

The *superior mediastinum* is that portion of the mediastinal space above the upper border of the fifth thoracic vertebra. It is bounded in front by the manubrium sterni; behind, by the upper dorsal vertebra; laterally, by the pleura. It contains:—

Origin of sternothyroid muscle;
Origin of sternohyoid muscle;
Lower end of the longus colli muscle;
Innominate artery;
Left carotid artery;
Subclavian artery;
Transverse portion of the aorta;
Innominate veins;
Superior vena cava;
Left superior intercostal vein;
Left recurrent laryngeal nerves;
Cardiac nerves;
Pneumogastric nerves;
Phrenic nerves;
Esophagus;
Trachea;
Thoracic duct;
Remains of the thymus gland;
Lymphatics.

THE GENITOURINARY APPARATUS.

THE genitourinary apparatus consists of the urinary organs and the male and female generative organs.

THE URINARY ORGANS.

The urinary organs consist of the kidneys, ureters, bladder and urethra.

THE KIDNEYS (RENES) are two glandular organs, situated deeply in the lumbar region, opposite the second or third lumbar vertebra and last dorsal, the right a little lower than the left. They are surrounded by fat (*capsula adiposa*) and held in position by the blood vessels and loose connective tissue. The right kidney is in relation in front with the liver, descending portion of the duodenum and ascending colon. The left is in relation with cardiac end of stomach, lower end of spleen, tail of pancreas and descending colon. Each kidney measures about four inches in length, two in width, and one in thickness and weighs from four and one-half to six ounces in male, four to five and one-half in female. Their shape is characteristic. The notch at the inner side is called the hilus (*hilus renalis*), and communicates with the interior cavity, the sinus, at which the blood vessels, nerves, and ureter have their passage. The kidneys have a special fibrous coat designated as the true capsule (*tunica fibrosa*), slightly adherent, which extends into the hilus and becomes continuous with the fibrous coat of the blood vessels and ureters. The relative position of the arteries, veins, and ureter at the hilus are, from above downward:—

A. Artery,
V. Vein,
U. Ureter;

from before backward:—

V. Vein,
A. Artery,
U. Ureter.

The general *structure* of the kidney consists of a cortical substance (*substantia corticalis*) and a medullary substance (*substantia medullaris*), the latter arranged into conical masses

called renal pyramids, with their bases in the cortical substance, and their apices, the renal papillæ (*papillæ renales*), projecting into the calices (*calyces renales*) of the pelvis within the sinus of the kidney (*sinus renalis*). The renal pyramids of Malpighi (*pyramides renales*), about ten to fifteen in number, correspond-

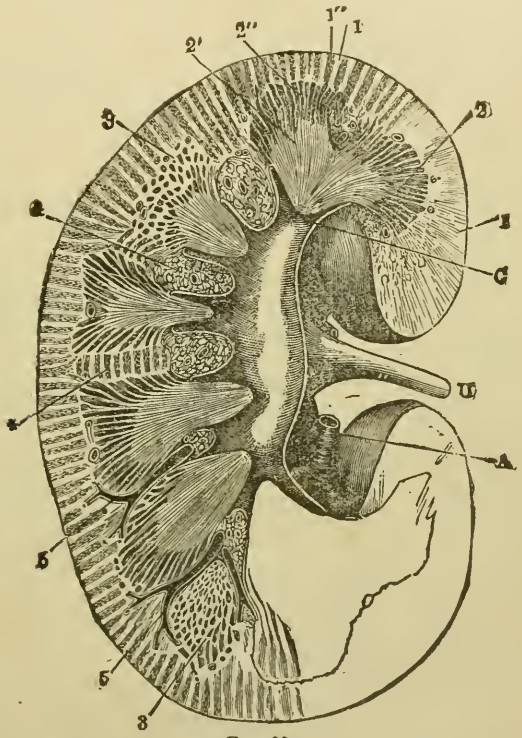

FIG. 96.

Longitudinal section of kidney: 1, cortex; 2, medulla; 3, section of tubules in boundary layer; 4, fat of renal sinus; 5, renal arteriole; *A*, branch of renal artery; *C*, renal calyx; *U*, ureter.

ing to the fetal lobules, are arranged into three irregular rows. The substance, or parenchyma of the kidney, is composed of uriniferous tubules (*tubuli renale*), held together by comparatively little connective tissue. The terminal orifices of these, several hundred to each papilla, open on its summit.

Course of the Tubuli Uriniferi.—Beginning at the Malpighian capsule (*capsula glomeruli*) within the cortex, each

tubule pursues a very tortuous and complicated course before it terminates in the renal papillæ (*papillæ renales*), the outline of which is as follows (after Gray) :—

(*a*) Neck—the constricted portion below the capsule, before it terminates in the renal papillæ,

(*b*) Proximal convoluted tube,
(*c*) Spiral tubule of Schachowa, } Within the cortical structure.

(*d*) Descending limb of Henle's loop,
(*e*) Henle's loop, } Within the medullary structure.

(*f*) Ascending limb of Henle's loop, { Partly in medullary and partly in cortical.

(*g*) Irregular tubule,
(*h*) Distal convoluted tubule,
(*i*) Curved tubule, } Cortical structure.

(*j*) Straight collecting tubule—descends through the medullary structure to open by an orifice in a renal papilla.

The *straight, collecting* or *receiving* tubes converge as they descend, and unite and reunite until there are about one dozen, but they vary from eight to twenty, one opening on the summit of each papilla. In the cortical portion they form groups, or *medullary rays,* giving the appearance of conical masses in the cortical substance with their apices toward the periphery—the so-called *pyramids of Ferrein.* The tubules are composed of a basement membrane, lined with pavement epithelium. In the neck the epithelium becomes continuous with that of the Malpighian capsule, and at the glomerule the wall is reflected upon the inclosed tuft, or Malpighian corpuscle. In other situations the epithelium varies much in shape and size. The *renal arteries* subdivide at the hilus, cross the sinus, and enter the renal substance between the renal papillæ. They terminate in the renal glomerules, or Malpighian corpuscles. Each one of these remarkable convolutions of capillaries is about one one-hundredth of an inch in diameter and inclosed in a pouch-like dilatation of the uriniferous tubules or Malpighian capsule, or capsule of Bowman. The efferent vessels form, together with others, a capillary network between and around the uriniferous tubules. They are made up of *three sets:* (*a*) the plexuses around the tubuli contorti; (*b*) the veins beneath the capsule; and (*c*) the plexuses about the apices of the pyramids of Malpighi. These form the *venæ interlobulares, which join the venæ rectæ,* and together form the renal veins, *venæ propriæ renales.* Those in the sinus unite together to form the renal vein, and open into the inferior vena cava, the left crossing in front of the abdominal aorta.

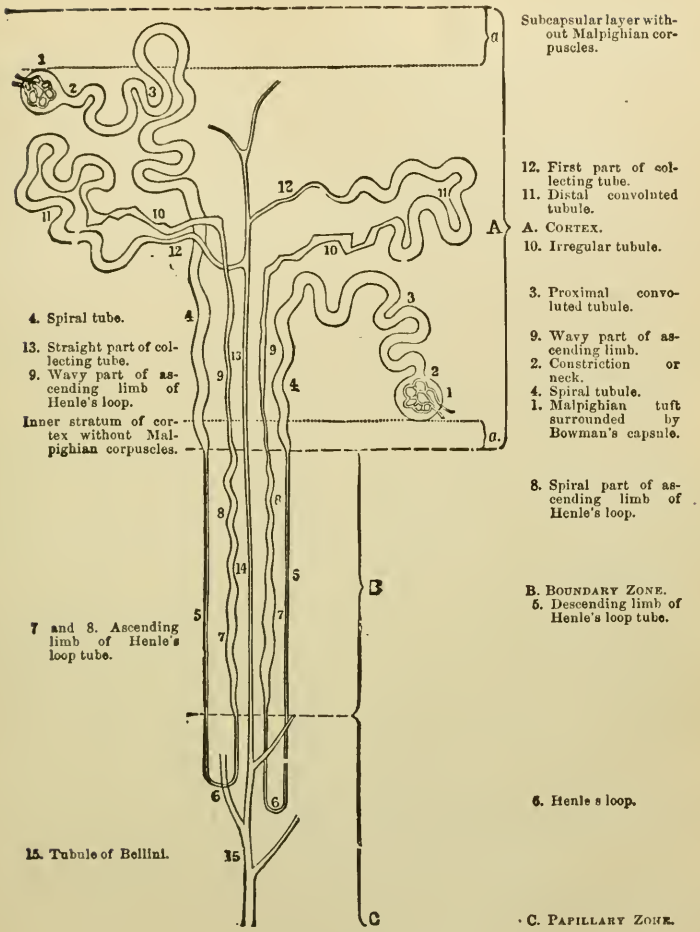

FIG. 97.

Diagram of uriniferous tubules: 1, Malpighian capsule; 2, proximal convoluted tubule; 2 b, distal convoluted tubule; 3, descending limb of Henle's loop; 4, ascending limb of Henle's loop; 5, irregular tubule; 6, collecting tube; *a*, apex of pyramid; *b*, base of pyramid; *c*, cortical portion.

The *ureter* commences as a compressed pouch, the pelvis. Within the sinus the pelvis divides, and subdivides into several small funnels, or *calices*, each one of which receives one or two projecting renal papillæ. The *calices*, pelvis and ureter are all of the same structure, consisting of a fibrous and unstriated muscular and a mucous coat. The fibrous coat (*tunica adventitia*) becomes continuous with the capsule above and below in the fibrous structure of the bladder. The muscular coat (*tunica muscularis*) ceases at the base of the renal papillæ, but the mucous membrane becomes continuous with that of the uriniferous tubules. Its epithelium is of the transitional variety, consisting of several layers of cells of varying shapes, resting upon a basement membrane.

The *nerves* are derived from the renal plexus of the sympathetic, formed by branches in the semilunar ganglion, the solar plexus and the lesser and smallest splanchnic nerve.

The *lymphatics* communicate with the lumbar glands.

The *ureter proper* is a musculomembranous tube, sixteen to eighteen inches in length, about the diameter of a goose quill, extending from its origin in the pelvis of the kidney to the basal or posterior angle of the vesical trigone, which it enters by passing obliquely through the muscular and mucous walls of the bladder.

Course.—It descends upon the psoas magnus muscle, beneath the peritoneum, being crossed by the spermatic vessels. About the first division of the sacrum it crosses the external or common iliac artery, passing behind the sigmoid flexure on the left and the ileum on the right side, to enter the pelvis, where it reaches the bladder within its posterior false ligament.

In the male it passes behind the vas deferens.

In the female it crosses the uterine artery one-third to one-half inch from the cervix uteri and passes along the side and upper part of the vagina to the bladder (*vide* Vagina).

Muscles of the Ureters.—Two oblique muscles. *Origin*, behind the orifices of the ureters; *insertion*, into the middle lobe of the prostate gland; *action*, they guard the orifices of the ureters, and prevent the reflux of urine.

Suprarenal capsules (*vide* Ductless Glands).

THE BLADDER.

The bladder (*vesica urinaria*) is a musculomembranous sac, the reservoir for the urine, situated in the anterior part of the pelvis, behind the pubes, in front of the uterus and vagina in the female, and the rectum in the male.

It measures, moderately distended, five inches in length, three in width, and holds about one pint. It consists of a body, summit, base and neck.

The body (*corpus vesicæ*) is partially invested with peritoneum behind, but in front it is wanting, the body being in relation with the symphysis pubis, triangular ligament, and internal obturator muscles.

The summit, or apex (*vertex vesicæ*), is rounded, and directed upward and forward, being connected to the umbilicus by the *urachus*, the remains of the fetal allantois, and also by the obliterated hypogastric arteries, one on either side.

The space bounded by the pubic surface and the sides of the bladder uncovered by peritoneum, filled by the rectovesical fascia, is known as the space of Retzius.

The base, or fundus (*fundus vesicæ*), in the male is situated upon a triangular space upon the second portion of the rectum, its base formed behind by the rectovesical fold, its apex by the prostate gland, and its sides by the vas deferens and vesiculæ seminales.

In the female it is situated in contact with the cervix uteri and anterior wall of the vagina, adhering closely to the latter. Its upper portion has a peritoneal covering.

The neck, or cervix (*collum vesicæ*), is the contracted portion, continuous with the urethra. It is encircled in the male by the prostate gland, and is directed obliquely when the individual is in the erect posture.

The *ligaments* of the *bladder* consist of five true ligaments derived from the pelvic fascia and the urachus; and five false ligaments derived from the peritoneum.

The *true* ligaments are:—

Two anterior (puboprostatic) (*ligamenta puboprostatica*), two folds of rectovesical fascia passing from the pubic symphysis to the cervix and upper surface of prostate gland;

Two lateral folds of rectovesical fascia connecting the lateral surfaces of prostate gland with sides of base of bladder;

The urachus (*ligamentum umbilicale medium*), an obliterated fetal structure, passing as a fibromuscular cord from the apex of the bladder to the umbilicus.

The *false* ligaments are:—

Two posterior ligaments (*plicæ rectovesicales*) are peritoneal folds passing between sides of rectum in male, sides of uterus in female, to posterolateral surface of bladder, inclosing obliterated hypogastric arteries, ureters, vessels and nerves;

Two laterals (*ligamenta umbilicale laterales*) are folds of peritoneum passing from iliac fossæ to sides of bladder;

The superior (*plica umbilicalis media*) is a single peritoneal fold inclosing the obliterated hypogastric arteries from apex of bladder to umbilicus.

The *structure consists* of four coats, a serous, muscular, submucous and mucous.

The serous coat (*tunica serosa*) is derived from the peritoneum. It covers the posterior surface from the ureters to the summit, and is reflected from the sides to the walls of the pelvis and abdomen.

The muscular coat (*tunica muscularis*) is made up of unstriated fibers arranged in three *layers*:—

(*a*) Longitudinal external layer (*stratum externum*), named the *detrusor urinæ muscle;*

(*b*) Circular middle layer (*stratum medium*), forming at the neck the sphincter vesicæ;

(*c*) Longitudinal internal layer (*stratum internum*).

The submucous or cellular coat (*tela submucosa*), made up of fibrous and elastic tissue, supports the mucous coat and unites it with the muscular.

The mucous membrane (*tunica mucosa*) is smooth and of a pale rose color. Its epithelium is continuous with that of the ureters and pelvis of kidneys; its superficial layer, large, tessellated, polyhedral cells; its deep layer of club-shaped and spindle-shaped cells.

The inner surface of the base presents a triangular space, the vesical trigone, or *trigonum vesicæ*, apex in front, formed by the orifice of the urethra, its basal angles behind about two inches apart, and each about one and one-half inches behind the urethral orifice, formed by the orifices of the ureters:—

U
1½ 1½″
U U
2″

The *uvula vesicæ* is an elevation of mucous membrane projecting from the floor near the apex of the trigone into the orifice of the urethra.

The *arteries* are the superior, middle and inferior vesical, with branches from the obturator and sciatic in the male, and branches from the vaginal and uterine in the female.

The *veins* from the vesicoprostatic empty into the internal iliac vein.

Lymphatics follow the course of the vessels and enter the lumbar glands.

The *nerves* to the base and neck are from the third and fourth sacral, and to the summit, from the hypogastric plexus of the sympathetic.

GENERATIVE APPARATUS.

Male Organs.

The male organs of generation consist of the testes, vasa deferentia, vesiculæ seminales and penis.

The TESTICLES (testes) are two glandular bodies which secrete the spermatic fluid, and are suspended by the spermatic cords within the scrotum, the left a little larger and lower than the right. They are oval, compressed laterally, measure one and a half to two inches in length, one inch in breadth, one and one-fourth inches in their anteroposterior diameter, and weigh from six to eight drachms.

They each consist of a body, or testicle proper, and an *epididymis*. The latter consists of a head or globus major (*caput epididymidis*), body or central portion (*corpus epididymidis*) and tail or globus minor (*cauda epididymidis*).

The scrotum consists of the skin marked in the median line by the raphé (*raphé scroti*), formed by the union of the genital folds, and the dartos, a reddish, contractile tissue which surrounds the testes and extends from the raphé to the under surface of the penis, forming the *septum scroti*, which divides it into two cavities for the testes.

The spermatic cord (*funiculus spermaticus*) is made up of the following structures:—

External spermatic, or intercolumnar fascia;
Cremaster muscle;
Internal spermatic fascia, or fascia propria;
Vas deferens;
Spermatic artery;
Deferential artery from superior vesicle;
Cremasteric artery, from epigastric;
Vasa spermatica;
Lymphatic vessels;
Spermatic plexus of nerves [from renal and aortic plexuses];
Genital branch of genitocrural;
Scrotal branch of the ilioinguinal.

It commences at the internal abdominal ring, passes obliquely through the inguinal canal, emerges at the external abdominal ring, descends into the scrotum, and terminates at the posterior border of the testes.

The external spermatic or intercolumnar fascia is derived from the aponeurosis of the external oblique muscle. This muscle arises within the inguinal canal from Poupart's ligament and pubic spine, and descends along the cord in loops. Its fibers are striated.

The cremaster muscle, or cremasteric fascia (*fascia cremasterica*) or middle spermatic fascia, is derived from the lower border of the internal oblique and transversalis muscle.

The internal spermatic fascia, or fascia propria, is the infundibuliform process of the transversalis fascia.

The proper coverings or tunics of the testicle are three—tunica vaginalis, tunica albuginea and tunica vasculosa:—

The tunica vaginalis (*tunica vaginalis propria testis*) is a serous membrane surrounding the testes, and at the posterior portion is reflected on itself to form a sac. The outer portion of the latter is loosely attached, except at the lower part of the testicle, where the gubernaculum testis binds it down.

The *tunica albuginea* is a dense, white fibrous structure, continuous at the upper part with a similar structure on the epididymis. At the back part it projects into the glandular substance of the testicle to form the mediastinum testis (*corpus Highmori*), from which numerous imperfect septa, called trabeculæ (*septula testis*) diverge, and with similar cords from the tunica albuginea serve to maintain the shape of the gland and divide it into lobules.

The tunica vasculosa (*pia mater testis*) lies within the tunica albuginea, and is the source and termination of the blood-vessels to the secretory substance of the gland, resembling the pia mater of the brain.

The *glandular structure* of the testis is divided into several hundred (two hundred and fifty to four hundred) pyramidal lobules (*lobuli testis*), each one of which consists of from one to three *tubuli seminiferi contorti.*

At the conical extremity of the lobules the tubules end in straight tubes, *vasa recta,* which enter the mediastinum to form the *plexus retiformis.* From the upper part of this the vessels unite into from twelve to twenty *vasa efferentia,* which pass out of the testicle to the epididymis. Within the epididymis these efferent canals form a series of spermatic cones, the *coni vasculosi.* These end in a coarse, convoluted tube, about twenty feet in length, forming the body and tail of the epididymis, and ending in the spermatic duct, or vas deferens (*ductus deferens*). These tubes are lined with columnar ciliated epithelium.

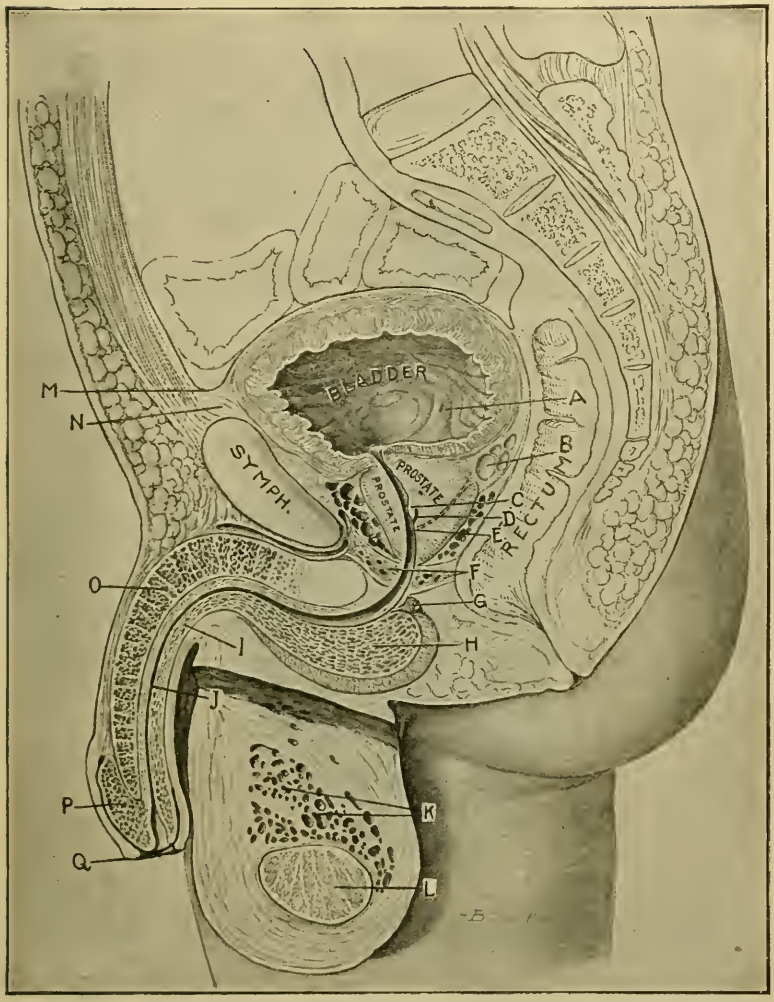

FIG. 98.

Section through bladder, urethra, and testicle: *A*, urethral orifice; *B*, seminal vesicle; *C*, colliculus seminalis or verumontanum; *D*, prostatic utricle; *E*, orifice of ejaculatory duct; *F*, suspensory ligament; *G*, Cowper's gland, *H*, bulb of corpus spongiosum; *I*, corpus spongiosum; *J*, urethra; *K*, seminal plexus; *L*, testicle; *M*, peritoneal fold; *N*, space of Retzius; *O*, corpus cavernosum; *P*, glans penis; *Q*, prepuce.

The *vas aberrans* of Haller is a spermatic cone joining the epididymis, but unconnected with the testicle.

The *hydatids of Morgagni* are one or two pedunculated bodies attached to upper part of testis or head of epididymis, and supposed to be the remains of Müller's duct.

Structure of the Tubules.—The tubuli seminiferi are minute convoluted tubules, closed at one extremity, consisting of a hyaline membrana propria lined with several layers of epithelial polyhedral cells, the *seminal cells,* from which the seminal or spermatic fluid is directly elaborated.

These cells undergo a process of indirect division (*karyokinesis*) to form the *spermatoblasts,* which are arranged into bundles, and are converted into *spermatozoids,* the nuclei becoming the head, and the tail, or ciliary appendages, being afterward developed. These cells are constantly cast off and replaced.

Descent of the Testes.—In early fetal life the testes are placed at the back part of the abdomen, below and in front of the kidneys, and behind the peritoneum.

About the third month a peculiar structure, the *gubernaculum testis,* appears, attached to the lower end of the epididymis, and extending as a cord to the bottom of the scrotum. It is supposed to cause the descent of the testicle. It reaches its full development between the fifth and sixth month, at which time the testicle reaches the iliac fossa. It enters the internal abdominal ring by seventh month, and the scrotum by the eighth month, carrying before it a fold of peritoneum, which is afterward shut off, forming the *tunica vaginalis testis.* Other coverings of the testicles are also derived in this manner. In the female a structure similar to the gubernaculum forms the round ligament.

The *vas deferens* has three coats—(1) an external fibrous coat (*tunica adventitia*), (2) an unstriated muscular coat (*tunica muscularis*), and (3) a lining membrane (*tunica mucosa*) of columnar epithelium. It is about one and one-half feet long and one line in diameter. From the tail of the epididymis it ascends in the cord, forming an important part, and lying behind the blood-vessels. It ascends through the inguinal canal, and at the internal ring descends on the bladder, crosses the ureter and obliterated hypogastric artery, and runs forward to form with the duct of the seminal vesicle the ejaculatory duct.

The walls of the vas are very thick and the canal very small. Its course for the most part is straight, but beneath the bladder

it becomes enlarged, tortuous, and more capacious, but again contracts near its termination.

The *arteries* of the cord are:—

The spermatic, to the testicle from the aorta;
The vas deferens, or deferent artery, from the superior vesical;
The cremasteric, from the deep epigastric.

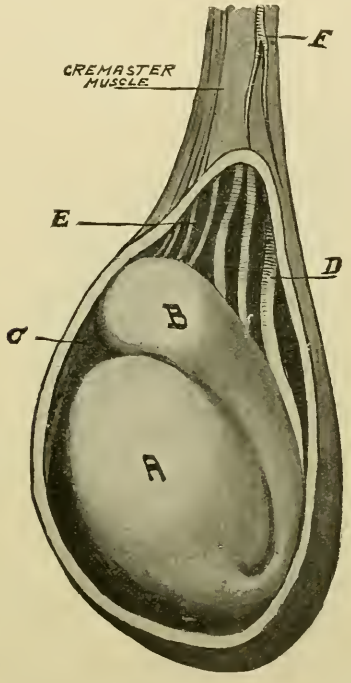

FIG. 99.

The testicle and epididymis: *A*, testis; *B*, epididymis; *C*, tunica vaginalis; *D*, vas deferens; *E*, spermatic artery and veins; *F*, artery of cord.

The *veins* from the testis—*spermatic veins*—unite with branches from the epididymis to form the *pampiniform plexus*, which terminates on the left side, passing beneath the sigmoid flexure in the left renal vein, on the right side in the inferior vena cava.

The *lymphatics* are numerous, and terminate in the lumbar glands.

The *nerves* are from the sympathetic system, and form the spermatic plexus.

The *arteries* of the scrotum are derived from the

Cremasteric branch of epigastric;
Superficial external pudic, from the femoral;
Deep external pudic, from the femoral;
Superficial perineal, branch of internal pudic, from internal iliac.

The seminal vesicles (*vesiculæ seminales*) are two membranous pouches, closely adhering to the under surface of the bladder.

Their size varies, but they usually measure two and one-half inches in length, one-half inch in breadth, and two to three lines in thickness.

Each consists of a tube closed at one end, about four to six inches long, the diameter of a quill, convoluted into a mass. Its structure is analogous to that of the ducts, but thinner.

The ejaculatory ducts (*ductus ejaculatorii*), two in number, are formed by the union of the vasa deferentia with the duct of the vesiculæ seminales. Each duct is three-fourths to one inch in length, and passes through the prostate gland to terminate at the margin of the sinus pocularis by a slit-like orifice.

The *arteries* are derived from the inferior vesical and middle hemorrhoidal. The *veins* and *lymphatics* correspond to, and accompany the arteries, and the nerves are from the hypogastric plexus of the sympathetic.

The seminal vesicles are not only reservoirs, but secrete a fluid to dilute the spermatic liquid.

The *semen* is a viscid, whitish liquid, composed of a colorless liquid, the *liquor seminis,* and the *spermatozoa* and *seminal granules.*

The *seminal granules* are about one-four-thousandth of an inch in diameter.

The *spermatozoa* are the essential elements, and consist of an oval head, a body or middle piece and a tail.

The penis is composed of three columnar bodies, two corpora cavernosa and one corpus spongiosum, invested with skin, and filled with a peculiar, vascular, sponge-like structure.

It is attached to the pubic arch and symphysis by its root (*radix penis*), has a free expanded extremity (glans penis) or head, and an intermediary portion, the body (*corpus penis*).

The upper surface is the dorsum, or back. The *glans* is a blunt, cone-like body, expanded at its base, the corona, and attached by its cervix, or neck (*collum glandis*).

The summit has a slit-like aperture, the meatus (*orificium urethræ externum*), or orifice of the urethra.

The skin adheres loosely to the organ, and has a loose, cup-like fold over the glans, called the prepuce (*præputium*), after which it is reflected into the cervix and glans, becoming continuous with the mucous membrane of the urethra at the meatus, to which it is attached below by a band or bridle, the frænum (*frenulum præputii*).

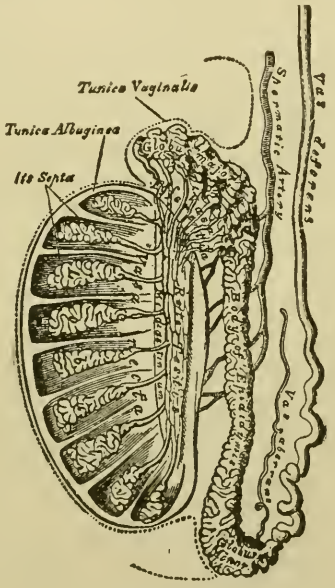

FIG. 100.

Vertical section of testicle. (*After Gray.*)

The skin covering the glans resembles mucous membrane, is very vascular and sensitive, but about the cervix and corona has numerous preputial glands—*glandulæ Tysoni odoriferi* (*glandulæ Tysonii odoriferæ*), which secrete the *smegma*.

The superficial fascia is thin, free from adipose tissue, and continuous with that of the abdomen and scrotum.

The suspensory ligament (*ligamentum suspensorium penis*) passes from the front of the pubic symphysis to the tunica albuginea of the corpora cavernosa. The fundiform ligament, or ligamentum fundiforme penis, was formerly described as the

suspensory ligament; this is not strictly correct, although the latter ligament is suspensory in character. The ligamentum fundiforme penis passes to the penis from the lower part of the linea alba, and at its penile attachment divides into two portions, between which pass the dorsal vessels and nerves.

The corpora cavernosa (*corpora cavernosa penis*), or cavernous bodies, constitute more than two-thirds of the bulk of the organ. They spring as crura from the rami of the ischium and pubis, swell out into the *bulb* of the *cavernous body,* or corpus cavernosum, join each other in the median line, to terminate in a conical extremity, which receives the glans.

They are grooved above for the dorsal vein, and below for the corpus spongiosum.

They each have a strong outer fibrous membrane, which, on uniting, forms a thick partition, complete behind, but incomplete and comb-like in front—*septum pectiniforme.*

From this septum fibroelastic bands diverge in all directions and form *trabeculæ,* which, with the blood-vessels occupying their intervals, form the erectile tissue of the corpora cavernosa.

The corpus spongiosum (*corpus cavernosum urethræ*) commences as a bulb below the crura and in front of the triangular ligament. It expands anteriorly into the *glans penis,* which fits upon the conical termination of the corpora cavernosa.

The urethra enters above and anteriorly to the bulb (*bulbus urethræ*), and traverses its entire length to the summit of the glans, opening at the meatus.

The corpus spongiosum consists of an external fibrous coat, thinner and more elastic than that of the corpora cavernosa, and an interior erectile tissue. A thin, muscular layer lines the external fibrous coat, and another is found beneath the mucous membrane of the urethra.

The corpora cavernosa get their blood from the arteries of the corpora cavernosa, and branches from the dorsal artery of the penis, from the internal pudic.

The corpus spongiosum is supplied by the artery of the bulb.

The *arteries* of all three bodies terminate finally in the erectile tissue. Many arterial branches, especially at the root of the penis, form short convolutions—the helicine arteries (*arteriæ helicinæ*), which terminate in finer vessels, and subsequently open into the spaces of the erectile tissue. Others open directly.

From these spaces the *veins* begin; some wind around the side of the organ to the dorsal vein, while others pass under the pubis to join the prostatic plexus.

The *lymphatics* are numerous; the superficial join the inguinal glands, the deep join the lymphatic plexus about the prostate and other deep lymphatics of the pelvis.

The male urethra (*urethra virilis*) is the common canal for the emission of semen and urine, extending from the neck of the bladder (*orificium urethræ internum*) to the meatus urinarius (*orificium urethræ externum*). It is from eight to nine inches in length, and consists of three portions—the prostatic, membranous and spongy.

The prostatic portion (*pars prostatica*) extends from the neck of the bladder to the anterior border (apex) of the prostate gland. It is one and one-quarter inches in length, and is the widest and most dilatable part.

Its floor is raised, and presents:—

Verumonatum, or caput gallinaginis (*colliculus seminalis*), an elevated ridge;

Prostatic sinus (*utriculus prostaticus*), on each side of the verumontanum;

Orifices of the *prostatic ducts,* in the floor of the prostatic sinuses;

Sinus pocularis, a depression in the median line in front of the verumontanum, presenting the slit-like openings of the ejaculatory ducts (*ductus ejaculatorii*). This *cul-de-sac* is one-quarter of an inch in length. It is homologous with the uterus, and has received the name of *utricle,* or *uterus masculinus.*

The membranous portion (*pars membranacea*) is about three-quarters of an inch in length, extending from the apex of the prostate gland to the corpus spongiosum above and in advance of the bulb. It passes out of the pelvis beneath the symphysis pubis, traversing the triangular ligament. It is the least dilatable portion and has four coats:—

Fibrous, continuous with both layers of the triangular ligament; erectile, continuous with that of the spongy body; an unstriated muscular layer and a mucous coat.

The spongy portion (*pars cavernosa*) extends from the membranous portion through the corpus spongiosum to the meatus urinarius on the summit of the glans.

The portion within the bulb has received the name of *bulbous portion* of the *urethra.* The spongy portion diminishes gradually in size to near the orifice, where it suddenly dilates into the fossa navicularis (*fossa navicularis urethræ* [*Mor-*

gagni]), contracting again at the meatus, the narrowest part of the urethra.

The mucous membrane is provided with columnar epithelium, except near the meatus, where it is tessellated, a fibro-elastic submucous layer with unstriated muscular fibers, and numerous minute racemose glands, the glands of Littré (*glandulæ urethrales*). These latter open forward into the urethra by good-sized orifices, especially one in the upper part of the fossa navicularis, called the *lacuna magna*. Into the bulbous portion of the urethra the ducts of Cowper's glands open.

The prostate gland (*prostata*) is a glandular body which resembles in size and form a chestnut, and surrounds the first portion of the urethra between the neck of the bladder and the triangular ligament. It measures one and one-half inches in length and breadth and three-quarters in depth. Its weight, about six drachms. Its flat under surface rests on the rectum.

It has two lateral lobes (*lobus dexter et sinister*), and one middle lobe (*lobus medius*), which corresponds in position to the *vesicle uvula*, and is held in position by the anterior ligaments of the bladder, by a portion of the deep perineal fascia, and of the levator ani muscle.

It is perforated by the urethra and the common seminal ducts.

Its *structure* consists of a mass of fibromuscular (unstriated) tissue with imbedded follicular pouches, the whole inclosed in a firm fibrous capsule, continuous in front with the triangular ligament, behind with the posterior layer of the deep perineal fascia.

The muscular fibers are longitudinal and circular, the latter surrounding the urethra, continuous behind with the bladder, in front with the fibers about the membranous portion.

The glands open into the floor of the prostatic sinuses by twelve to twenty ducts.

The *arteries* are from the vesical, hemorrhoidal and internal pudic.

The *veins* enter into the formation of the prostatic plexus, receive the dorsal vein of the penis, and empty into the internal iliac vein.

The *nerves* are from the hypogastric plexus.

Cowper's glands, or suburethral glands (*glandulæ bulbo-urethrales*), are two small lobular bodies, about one-quarter of an inch in diameter, inclosed between the two layers of the deep fascia, situated behind the bulb of the corpus spongiosum, below the membranous portion of the urethra. They are racemose

glands and empty their secretion by a long duct (*ductus excretorius*) into the bulbous portion of the urethra.

Female Organs.

The female organs of generation are divided into the external (*partes genitales externæ muliebres*), termed the vulva, or pudendum, consisting of the mons veneris, labia majora, minora, clitoris, meatus urinarius and orifice of the vagina; and the internal (*pars genitales internæ muliebris*), consisting of

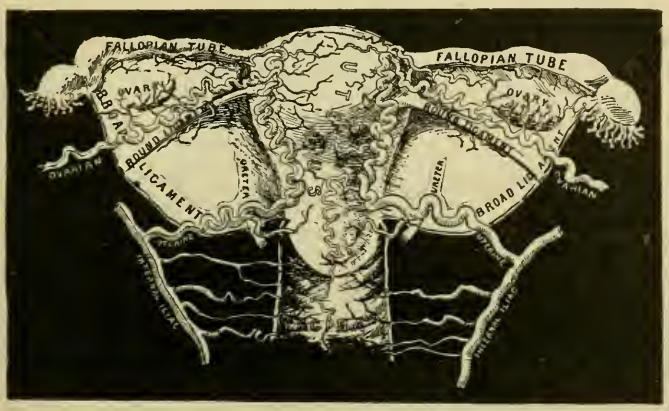

FIG. 101.

Internal female genitals.

the uterus, ovaries, Fallopian tubes and vagina, with certain accessories.

THE UTERUS is a hollow, muscular organ for the reception of the fecundated ovum and the development and expulsion of the fetus.

The virgin uterus holds an oblique anterior position in the pelvis, being supported by attachments to the vagina, rectum, bladder and sides of the pelvis.

It is in contact with the bladder in front, the rectum behind, and above the small intestine.

Its shape is pyriform, compressed from before backward, and measures three inches in length, two in breadth, one in thickness, and weighs from one to one and a half ounces.

It consists of a neck, fundus and body.

The mouth, os uteri, or os tincæ (*orificium uteri externum*), open into the vagina, being protected by two lips; an anterior (*labium anterius*) thick lip, and a posterior (*labium posterius*), long and narrow.

The cavity of the uterus (*cavum uteri*) is triangular ▽ from side to side, but a mere slit from before backward, and measures two and one-half inches in its longitudinal diameter.

The two upper angles are prolonged to communicate with the Fallopian tubes; the lower angle forms the ostium internum uteri (*orificium internum uteri*), communicating with the cavity of the cervix.

Its *structure* consists of three coats:—

Serous coat (*tunica serosa*), derived from the peritoneum and investing all but the lower anterior quarter;

Muscular coat (*tunica muscularis*), about one-half inch thick, composed of unstriated muscular fibers arranged into three layers;

Mucous coat (*tunica mucosa*), has numerous tubular follicles, is lined with ciliated columnar epithelium, and has no submucous coat to connect it with the muscular coat.

The mucous membrane of the cervix is thrown into folds, or *rugæ*, which assume on the anterior and posterior walls a branched arrangement, or *arbor vitæ uterina*. It is lined by squamous epithelium, and presents numerous follicular glands—the *ovula of Naboth*, or *glandulæ Nabothi*.

The *arteries* are branches of the ovarian from the aorta, and the uterine from the internal iliac, remarkable for their tortuosity and anastomoses.

The *veins* form plexuses or *uterine sinuses*, the branches of which correspond to the uterine arteries and terminate in the uterine plexuses.

The *lymphatics* are very numerous and terminate in the lumbar and pelvic glands.

The *nerves* are from the ovarian and hypogastric plexus of the sympathetic.

The *ligaments* of the uterus are folds of peritoneum arranged into four pairs:—

Two anterior, or *vesicouterine*, passing one on either side from the posterior surface to the cervix uteri;

Two posterior or rectouterine (*plicæ rectouterinæ*), passing between the sides of the rectum and uterus, and inclosing a *cul-de-sac*, the *rectovaginal pouch*, or *Douglas's pouch;*

A prolongation of this ligament upward to the second sacral vertebra, with some unstriated muscular fibers derived from the uterus and vagina, forms the so-called *uterosacral ligaments;*

Two lateral, or broad (*ligamentum latum uteri*), extending from the uterus to the sides of the pelvis, dividing it into two portions, and inclosing the Fallopian tubes, ovary, ovarian ligament, uterine blood-vessels, lymphatics and nerves, and some unstriated muscular fibers;

Two round ligaments (*ligamentum teres*), are cords of unstriated muscular and fibrous tissue, extending from the side of the fundus uteri to the inguinal canal, where they are lost in the subcutaneous tissue of the pubes and labia majora.

The canal of Nuck, a pouch of peritoneum, incloses the ligament in the young subject, but is usually obliterated later.

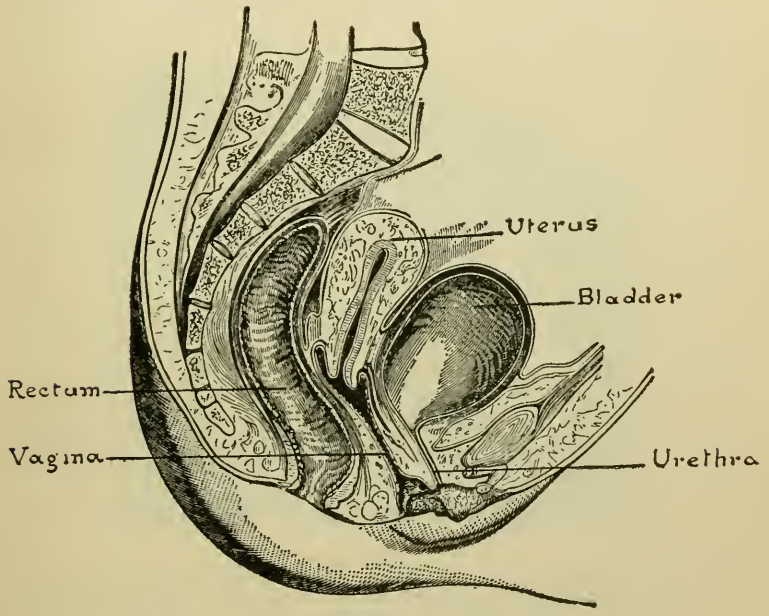

FIG. 102.

Female organs of generation.

THE OVARIES correspond to the male testicles, and are suspended behind the broad ligament inclosed in its posterior layer.

They are largest from puberty to adult age, and measure one and one-half inches in length, three-quarters of an inch in width, and one-third of an inch in thickness, and weigh from one to two drachms. The inner border is attached to the fundus uteri by the *ovarian* ligament, and its outer border to the fimbriated extremity of the Fallopian tube by a cord (tubo-ovarian ligament).

The *structure* of the ovary is made up of a reddish, spongy *stroma,* well supplied with blood-vessels, containing numerous ovisacs, or Graafian vesicles (*folliculi oöphori vesiculori* [Graafi]), inclosed in a serous covering derived from the peritoneum.

The *serous coat* differs from the peritoneum in having a single layer of columnar cells, the *germinal epithelium of Waldeyer.*

The *stroma* of the ovary is a vascular tissue, composed of many spindle cells and a small portion of connective tissue. Upon the surface of the ovary, this tissue becomes more firmly organized and tenacious; and was formerly, but erroneously, designated the *tunica albuginea.*

The *Graafian vesicles,* or ovisacs, containing the human ova, vary in size from microscopic bodies to one-quarter of an inch in diameter, and are most abundant in the periphery.

In *structure* they consist of a fibrous coat—the *ovicapsule*—lined by a basement membrane—*membrana propria*—and a layer of cells, the *membrana granulosa.* The interior is filled with a transparent albuminous fluid, *liquor folliculi.*

The epithelial lining nearest the ovary presents an accumulation of cells—the *germinal eminence,* or discus proligerus, within which is the *ovum* or *egg.*

Discharge.—The Graafian vesicles approach the surface of the ovary and burst, their contents passing into the opened aperture of the tube, the fimbriated extremity apparently applying it to the region of the bursting ovisac.[1]

The rupture occurs periodically and corresponds to the menstrual flow.

The ovum is surrounded by the tunica vasculosa and some additional epithelial structures (retinacula). It is one-tenth line in diameter, and represents all the elements of an organized cell, being composed of a

Cell-wall, or *vitelline membrane,* or *zona pellucida;*
Cell-contents, or *vitellus;*
Nucleus, or *germinal vesicle;*
Nucleolus, or *germinal spot.*

At the seat of the rupture the walls collapse, and the vesicle immediately becomes filled with a blood-tinged fluid, which, together with the hypertrophy of the walls, forms the

[1] The fimbriated extremity contains no erectile tissue, and the ovum probably falls into the peritoneal cavity and is swept into the tube by the action of the cilia. (*Spigelberg.*)

false corpus luteum, which remains and develops for two to three months and gradually disappears.

Under the influence of pregnancy it enlarges for some time, forms the *true corpus luteum* of *pregnancy,* and disappears two to three months after parturition.

The *arteries* are the ovarian from the aorta.

The *veins* form an intricate plexus from which emerge vessels corresponding to the arteries; they form a plexus near the ovary—the pampiniform plexus—which communicates with the uterine and terminates as in the male.

The *lymphatics* are numerous and of large size in the

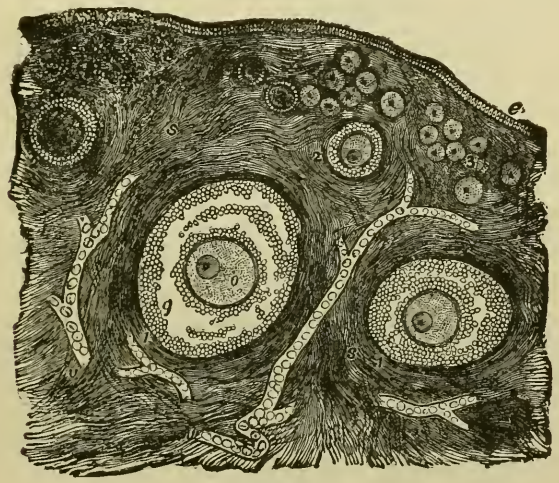

FIG. 103.

Section of an ovary: *e*, germ epithelium; 1, large-sized follicles; 2, 2, smaller-sized follicles; *o*, ovum within a Graafian follicle; *r*, *r*, blood-vessels of the stroma; *g*, cells of the membrana granulosa.

impregnated uterus, and terminate in the lumbar and pelvic glands.

The *nerves* are from the ovarian and thoracic aortic plexuses of the sympathetic.

The *Parovarium,* epoöphoron or organ of Rosenmüller, consists of a series of tortuous tubes extending from the ovary to a main transverse trunk, near the Fallopian tubes; and is the remains of the Wolffian body of embryonic life, and corresponds to the origin of the epididymis in the male.

The Fallopian tubes, or oviducts (*tuba uterina Fallopii*), are the passageways for the ovum from the ovaries to the uterus.

They are trumpet-shaped tubes about four inches long, with the largest extremity outward.

Its ovarian extremity is fimbriated; hence its name, *fimbriated extremity.* It is also called *morsus diaboli,* from its supposed erectile action.

One of these fimbriæ extends along the border of the broad ligament to the outer extremity of the ovary, forming the tubo-ovarian ligament (*fimbria ovarica*).

The ovarian orifice—ostium abdominale, or pavilion (*ostium abdominale tubæ uterinæ*)—is much larger than the uterine, or ostium internum (*ostium uterinum tubæ*).

The tube has three coats:—

Serous (*tunica serosa*), derived from the peritoneum;

Fibromuscular (*tunica muscularis, stratum longitudinale et stratum circulare*), from the uterine walls;

Mucous coat (*tunica mucosa*), with ciliated columnar epithelium, continuous with the uterine.

The remains of the duct of Müller form the hydatid of Morgagni (*appendices vesiculosi*), a small vesicle, attached by a long pedicle near the fimbriated extremity.

The *arteries* are from the ovarian, the *veins* follow the same course, and the *lymphatics* and nerves are the same as the ovarian and uterine.

The vagina is a cylindrical membranous canal extending from the vulva to the uterus. It is formed by the coalescence of two symmetrical tubes in fetal life.

Relations.—It is in relation in *front* with the base of the bladder and urethra, behind its upper fourth with Douglas's pouch, its lower three-fourths connected loosely with the rectum, and *laterally* with the broad ligaments, pelvic fascia and levator ani muscles.

On the posterior wall just below the cervix uteri the ureters approach each other, leaving a space of only three-quarters of an inch between them, an important factor in lithotomy.

In the virgin adult it measures about four inches in length, one inch in width, somewhat larger in its middle. Its anterior (*paries anterior*) and posterior walls (*paries posterior*) are in contact.

Its lower orifice, or entrance (*orificium vaginæ*), is constricted by a crescentic or circular fold of mucous membrane, the *hymen.*

The upper extremity, or fundus, receives the cervix uteri, extending higher up posteriorly (five to six inches), making the anterior lip apparently the longest.

The mucous membrane has numerous transverse folds, or rugæ (*rugæ vaginales*), passing to either side of a median ridge, both anterior and posterior, the columnæ vaginæ (*columnæ rugarum anterior et posterior*), formed by the coalescence of the two tubes in fetal life. Some of these rugæ present wart-

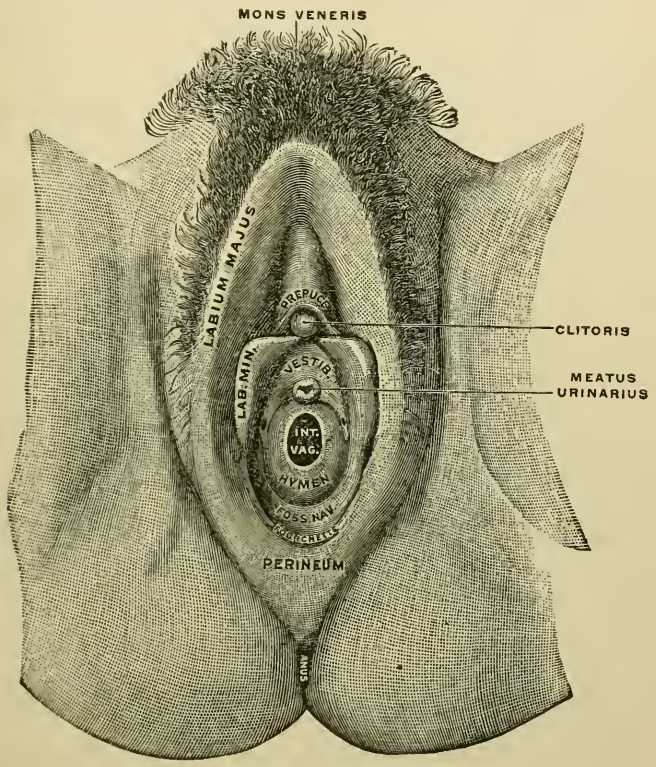

FIG. 104.

External female genitals. (*Eckley.*)

like eminences, most numerous about the entrance of the vagina, where they form the caruncule myrtiformes (*caruncule hymenales*), the remains of the hymen after intercourse (or after parturition—Budin).

The walls of the vagina are about one line thick and consist of three coats:—

Muscular coat (*tunica muscularis*), of unstriated fibers, elastic tissue and blood-vessels, consisting of two layers, external longitudinal and internal circular, and about the entrance the internal circular fibers form the *sphincter vaginæ* (*vide* Perineum);

An *erectile coat,* largely composed of loose connective tissue, imbedded in which are many large veins and unstriped muscular fibrous tissue. This erectile coat is found between the mucous membrane and the muscular coat.

Mucous or internal coat (*tunica mucosa*), containing numerous conical papillæ, and covered by squamous epithelium.

The *arteries* are from the vaginal, uterine, vesical and internal pudic.

The *veins* form an intricate plexus on each side with the returning vessels, corresponding to the prostatic plexus, and join the internal iliac veins.

The *nerves* are from the hypogastric plexus of the sympathetic, also the fourth and fifth sacral and internal pudic nerves.

The vulva, or pudendum (*pudendum muliebre*), consists of the mons veneris, labia majora and minora, clitoris and meatus urinarius.

The mons veneris (*mons pubis*) is the prominence of skin over the symphysis pubis, supported upon a mass of adipose tissue, and covered with hair.

The labia majora (*labia majora pudendi*) are two folds of skin bounding the vertical fissure of the labia (*rima pudendi*), the junctions of which in front and behind form the anterior (*commissura labiorum anterior*) and posterior (*commissura labiorum posterior*) commissures. The labia correspond to the scrotum in the male.

Within the posterior commissure is a depression, fossa navicularis (*fossa navicularis vestibuli vaginæ*), which separates it from a fold of mucous membrane—the fourchette (*frenulum labiorum pudendi*).

The triangular space between the anus and the posterior commissure is termed the *perineum.*

The *clitoris* corresponds to the penis in the male, resembling it also in form, structure and connections.

It is about one and one-half to two inches in length, and consists of a pair of corpora cavernosa, and a double, spongy body (*corpus clitoridis*), surmounted by a free extremity (*glans clitoridis*).

The corpora cavernosa (*corpus cavernosum clitoridis*) arise by two crura attached to the rami of the pubes and ischium like

the penis, and united in front by the septum pectiniforme. They curve abruptly down, being attached to the pubic symphysis by a suspensory ligament. The body and crura represent a tripod.

The free extremity (*glans clitoridis*) corresponds to that of the male penis, but is not perforated by the urethra. It is covered by the *præputium clitoridis,* a hood-like fold of skin continuous with the nymphæ.

The corpus spongiosum consists of an intermediate portion and semibulbs. The former consist of a plexus of veins, inclosed in a fibrous membrane.

The semibulbs, or *bulbi vestibuli,* are about the size of large almonds, and are situated beneath the vestibule, embracing the orifices of the urethra and vagina. In front of the bulbs, between them and the clitoris, is a smaller plexus called the *pars intermedia.*

The *arteries, nerves,* and *veins* are the same as those of the penis.

The nymphæ, or labia minora (*labia minora pudendi*), are two folds of mucous membrane diverging from the *præputium clitoridis* to the labia, where they are lost. At their superior extremity they divide into two folds, the upper forming the *præputium clitoridis,* the lower ones are usually lost in women who have borne offspring. In the non-pregnant female they usually unite behind, forming a fold, designated the frenum (*frenulum clitoridis*).

These diverging labia inclose a triangular space, the vestibule (*vestibulum vaginæ*), at the middle of the base of which is situated the orifice of the urethra, or *meatus urinarius,* (*orificium urethræ externum*).

The *bladder* in the female is larger and broader than in the male. It is situated behind the pubes, in front of the uterus, from which it is separated by the small intestine, and rests upon the anterior wall of the vagina and cervix uteri.

The *urethra* is a short but capacious canal, one and one-half inches in length, one-quarter inch in diameter, extending beneath the pubic symphysis from the neck of the bladder to the external urinary meatus. It lies in the anterior wall of the vagina, and perforates the triangular ligament precisely as does the male urethra (*vide* Urethra).

Below the vestibule is the entrance or orifice of the vagina (*orificium vaginæ*). The mucous membrane of the labia is reflected continuously to the clitoris, nymphæ, prepuce and vestibule, and becomes continuous with the vagina and urethra.

Its epithelium is squamous, and its glands racemose, mucous and small sebaceous glands (*glandulæ Tysonii odoriferæ*).

The Bartholin or suburethral glands (*glandula vestibularis major* [*Bartholini*]) are two racemose glands about one-third inch in diameter, situated just behind the semibulbs of the spongy body. The ducts, about three-fourths inch long, open between the nymphæ and the vaginal orifice, or the hymen, if present. They secrete mucus.

The *blood vessels* and *nerves* of the vulva correspond to those of the penis and scrotum (*vide* Internal Pudic Artery).

MAMMARY GLAND.

The mammæ, or breasts (*mamma*), are the milk-secreting organs of the female (being rudimentary in the male). They consist of two large, hemispherical bodies (*corpus mammæ*), in the anterolateral region of the thorax, resting upon the pectoralis major muscle, between the third and seventh ribs, inclosed between the two layers of the superficial fascia.

The nipple (*papilla mammæ*) is roseate or brownish, and surrounded by an areola (*areola mammæ*) of the same color, the skin of which contains numerous sebaceous glands, the *tubercles* of the *areola,* or the glands of Montgomery (*glandulæ areolares*). The skin of the nipple is thin, vascular and erectile. On its summit are the orifices of the fifteen to twenty milk-ducts, or lactiferous ducts.

Its structure is firm and pinkish white, consisting of fifteen or twenty lobes (*lobi mammæ*), forming a racemose gland, held together and invested with fibrous tissue.

Each lobe ends in one of the tubuli lactiferi, or galactophori (*ductus lactiferus*), which beneath the areola dilates into a lactiferous sinus, or galactophorus sinus, or ampulla (*sinus lactiferans*), and terminates on the summit of nipple in an orifice.

The *arteries* are, the long thoracic, with other branches of the axillary, the internal mammary and intercostals.

The *veins* follow the corresponding arteries to end in the internal mammary and axillary veins. They form about the base of the nipple a venous circular anastomosis, the *circulus venosus.*

The *lymphatics* terminate in the axillary glands, a few also entering the anterior mediastinal glands.

The *nerves* are from the fourth, fifth and sixth intercostals, with sympathetic filaments from the dorsal cord.

Milk, the secretion of the mammary gland, is an emulsion, consisting of a colorless fluid, the *milk-plasma,* holding in suspension the *milk-globules.* It has a specific gravity of 1.028 to 1.034, and slightly alkaline reaction.

THE NERVOUS SYSTEM.

THE nervous system, for description, is divided into two parts: *central* and *peripheral.*

The *central nervous system,* cerebrospinal axis, or encephalospinal axis, or neuraxis, consists of the brain and spinal cord, and also comprises certain exterior ganglia.

The *peripheral nervous system* consists of the cranial and spinal nerves and ganglia, and the sympathetic nerves and ganglia.

The nervous system may also be divided into the *cerebrospinal system,* that supplying muscles, skin, and mucous membranes; and the *sympathetic system,* presiding over organs and blood vessels.

Structure.—Nervous tissue consists of three distinct substances, combined in variable proportions in the different parts of the nervous system (white, or fibrous substance; gray, cineritious, or vesicular substance, and neuroglia).

(*a*) White substance is found in the cortex of the cord, the interior of cerebrum, in nerves, etc., and is made up of medullated nerve fibers. These are smooth, round fibers, measuring one-two-thousandth to one-twelve-thousandth of an inch in diameter, and have each three parts:—

1. *Axis cylinder* of Purkinje is a round or bandlike striated structure consisting of fibrillæ, called the primitive fibrillæ of Schultze. There is said to be an envelope of tissue around this composed of a substance called neurokeratin;

2. The *medullary sheath,* or white substance of Schwann, is made up of fatty matter in a fluid condition and probably insulates the axis cylinder; and

3. The *neurilemma,* or sheath of Schwann, a delicate, structureless membrane, closely surrounding the medullary sheath, and forming the surface of the nerve fibers.

Near their termination the nerve fibers lose their medullary sheath and become non-medullated (Remak's) fibers. Such are the olfactory and most of the sympathetic nerves.

(*b*) *Gray substance,* found in the middle of the spinal cord, in the cortex of the brain, in ganglia, etc., consists of

three elements: (1) nerve fibers; (2) nerve cells; and (3) blood vessels and connective tissue.

Nerve fibers.—The nerve fibers are the prolongation of the nerve cells. If there be but one process it is termed the axone, axis cylinder, or Dietrich's process. If there be more than one there is one which is the axone and the rest are called dendrites, or protoplasmic processes. There are two kinds of fibers, medullated and non-medullated.

Nerve cells are of three kinds, according to the number of their processes: unipolar, bipolar and multipolar cells.

A *neuron* is the term given to a nerve cell with its axone, or axis-cylinder process, and its dendritic processes. Each neuron is a distinct and separate unit. According to the neuron theory the neurons mass together to form cell groups and fiber systems. Each neuron is not joined to the other neurons, but is in contact with them. Process touches process or process touches cell. The neuron theory is as yet not firmly established and a new theory, that of Apáthy and others, claims that the chief constituents of the nervous system are neurofibrils which go from cell to cell.

(*c*) *Neuroglia,* the supporting framework of nerve tissue, is made up of a matrix of delicate, fibrillar network and small neuroglia cells, and forms an imbedding substance for the other elements.

Nerves are round, or flattened white, shining cords, belonging either to the cerebrospinal or the sympathetic systems. They are made up of bundles of nerve fibers held together by fibroconnective tissue, the *epineurium.* The individual fibers are held together within the bundles by connective tissue, the *endoneurium.*

The nerve fibers have a twofold function—sensory and motor.

Sensory, or afferent, transmit impressions from the periphery to the centers.

Motor, or efferent, transmit impressions from the centers to the periphery.

Ganglia form independent nerve centers, similar to but less complex than the brain. They are connected with some of the cranial nerves, all of the spinal nerves, and form an important part of the sympathetic system.

Terminations.—The motor nerves end in the voluntary and involuntary muscles, the former having special endings called the *motorial end plates.*

The sensory nerves terminate in the peripheral organs to which they are distributed by first becoming non-medullated, and then dividing and joining one another to form a minute plexus or by means of one of the five special endings, called *"peripheral end organs":* (1) tactile corpuscles of Wagner; (2) end bulbs of Krause; (3) the Pacinian corpuscles; (4) neurotendinous spindles; or (5) neuromuscular spindles.

CEREBROSPINAL AXIS.

The cerebrospinal axis is divided into two grand divisions:—

The encephalon, or brain and spinal cord.

Membranes of the Brain.—The membranes of the brain (*meninges encephali*) are three—dura mater, arachnoid and pia mater.

Dura mater (*dura mater encephali*) is a dense, white, fibrous membrane lining the interior of the skull, and forming its internal periosteum, to which it is tightly adherent at the sutures.

It contains the sinuses or venous channels (already described), and forms four partitions for the support of the brain—the falx cerebri, falx cerebelli, tentorium cerebelli and diaphragma sellæ.

Falx cerebri is an arched or sickle-shaped process received into the longitudinal fissure. It contains in its upper and lower margins the superior (*sinus sagittalis superior*) and inferior (*sinus sagittalis inferior*) longitudinal sinuses and forms by its attachment to the tentorium the straight sinus (*sinus rectus*).

Tentorium cerebelli is a lamina, arched across, between the superior borders of the petrous portion of temporal on either side, the anterior and posterior clinoid processes in front, the transverse ridge of the occipital behind, for the support of the posterior lobes of the cerebrum. It incloses the superior petrosal (*sinus petrosus superior*) and the lateral sinuses (*sinus transversus*).

Falx cerebelli is a small median, triangular partition descending from the tentorium to the foramen magnum, and separating the lateral lobes of the cerebellum.

Diaphragma sellæ is a horizontal process formed by a doubling of the meningeal layer of the dura mater. It forms a small circular fold which roofs the sella turcica and covers the pituitary body, leaving a small central opening (*foramen diaphragmatis sellæ*).

The arachnoid (*arachnoidea encephali*) is a thin, transparent, delicate membrane consisting of fibrous and elastic tissue, situated between the dura and pia mater. From the former it is separated by the subdural space (*cavum subdurale*); from the latter, by the subarachnoid space (*cavum subarachnoideale*).

Unlike the pia mater, it does not dip into the sulci on the brain surface, except by the Sylvian and great longitudinal fissures.

The subarachnoid space contains cerebrospinal fluid, and communicates through certain foramina with the cavities of the brain. The space is much broken up by loose connective tissue, which connects it to the pia mater.

The three expanded portions of the subarachnoid space are the cisterna magna, cisterna pontis and cisterna basalis.

The cisterna magna (*cisterna cerebellomedullaris*), or posterior subarachnoid space, is placed over the roof of the lower portion of the fourth ventricle, and communicates with the fourth ventricle by the foramen of Majendie and two smaller foramina: those of Keyes and Retzius.

The anterior subarachnoid space (*cisterna pontis*) is placed in front of the pons Varolii.

The cisterna basalis (*cisterna interpeduncularis*) incloses the circle of Willis.

The Pacchionian bodies (*granulationes arachnoideales*) are projections of the arachnoid into, but not through, the dura mater, and are most numerous along the great longitudinal sinus. They make impressions on the under surface of the calvarium, from which, however, they are separated by a thin layer of dura mater. Their function is to allow the passing of fluid from the subarachnoid space into the brain-sinuses when the blood pressure in the sinuses is lower than in the subarachnoid space.

Pia mater (*pia mater encephali*), the investing membrane of the brain, is composed of a network of blood vessels derived from the vertebral and internal carotid arteries, held together by delicate connective tissue. It dips into the sulci, and is prolonged into the ventricles, forming the velum interpositum (*tela chorioidea ventriculi tertii*); or tela choroidea superior and the tela choroidea inferior (*tela chorioidea ventriculi quarti*). The former covers the third ventricle and extends into the lateral ventricles, carrying in its margins the choroid plexus of the lateral and third ventricles. It is perforated by two slitlike foramina, one communicating with each lateral ventricle.

The tela choroidea inferior (*tela choroidea ventriculi quarti*) forms the roof of the lower part of the fourth ventricle. It contains nerves and lymphatics.

The Brain (The Encephalon).

The brain (*encephalon*) consists of four distinct portions: the cerebrum, cerebellum, pons Varolii and medulla oblongata. The average weight of the brain in the male adult is forty-nine and a half ounces, in the female forty-four ounces, of which the cerebrum is about seven-eighths of total weight. The maximum male brain weighs sixty-five ounces; minimum, thirty-four ounces. The maximum female brain weighs fifty-six ounces; minimum, thirty-one ounces. The brains of idiots seldom weigh more than twenty-three ounces. Excepting the whale and elephant, the human brain is heavier than that of all the lower animals.

The brain is developed from the anterior portion of the primitive neural tube. This expands and later becomes constricted into three primary brain-vesicles, which are called the fore-brain (prosencephalon), mid-brain (mesencephalon), and hind-brain (rhombencephalon). The fore-brain becomes differentiated later into the telencephalon and diencephalon; and the hind-brain likewise is differentiated into two parts: the metencephalon and the myelencephalon.

From these brain-vesicles are developed the following:—

- Brain or Encephalon,
  - Rhombencephalon, or hind-brain,
    - Myelencephalon,
      - Medulla oblongata,
      - Lower part of fourth ventricle.
    - Metencephalon,
      - Cerebellum,
      - Pons Varolii,
      - Upper part of fourth ventricle.
    - Isthmus rhombencephali (narrow part connecting with mesencephalon),
      - Superior cerebellar peduncles,
      - Valve of Vieussens.
  - Mesencephalon, or mid-brain,
    - Mesencephalon, or mid-brain,
      - Corpora quadrigemina,
      - Crura cerebri,
      - Aqueduct of Sylvius.

- Brain or Encephalon, (*continued*)
  - Prosencephalon, or fore-brain
    - Thalamencephalon, or diencephalon,
      - Optic thalami,
      - Subthalamic regions,
      - Pituitary and pineal bodies,
      - Structures in interpeduncular space.
      - Optic nerve and retina.
      - Hinder part of third ventricle.
    - Telencephalon
      - Cerebral hemispheres,
      - Olfactory lobes,
      - Lateral ventricles,
      - Foramina of Monro,
      - Anterior portion of third ventricle.

The medulla oblongata (*myelencephalon*) is the upper expanded portion of the spinal cord, extending between the lower border of the pons and the upper border of the atlas. It is divided by two fissures—the anterior (*fissura mediana anterior*) and posterior median (*fissura mediana posterior*) fissures—into two halves, each one of which is subdivided into four columns, from before backward, the following:—

(*a*) Anterior pyramids (*pyramis medullæ oblongatæ*), or corpora pyramidalia, are two pyramidal masses of white nervous matter, placed between the anterior median fissure and the olivary body, and continuous with the anterior columns of the cord below;

(*b*) *Lateral tract* and olivary body, are continuous with the lateral columns of the cord below;

(*c*) Restiform bodies (*corpus restiforme*) are continuous below with the posterior columns of the cord. They are composed of the fibers of the columns of Goll and Burdach and the direct cerebellar tract. They diverge, the interval between them being the lower portion of the fourth ventricle.

The *structure* of the medulla oblongata consists of both white and gray matter, the former arranged into four columns, the latter contained in the interior.

The gray matter of the medulla is partly arranged into masses and partly continuous with the gray matter of the cord. The posterior horns are called here "the tubercles of Rolando" (*tuberculum Rolandi*). On the floor of the fourth ventricle (*fossa rhomboidea*) the ganglion-cells are arranged into *nuclei*, from which several of the cranial nerves have their origin.

The Pons Varolii connects the cerebrum above with the cerebellum behind and the medulla oblongata below. On its under surface it presents a groove (*sulcus basilaris*) for the

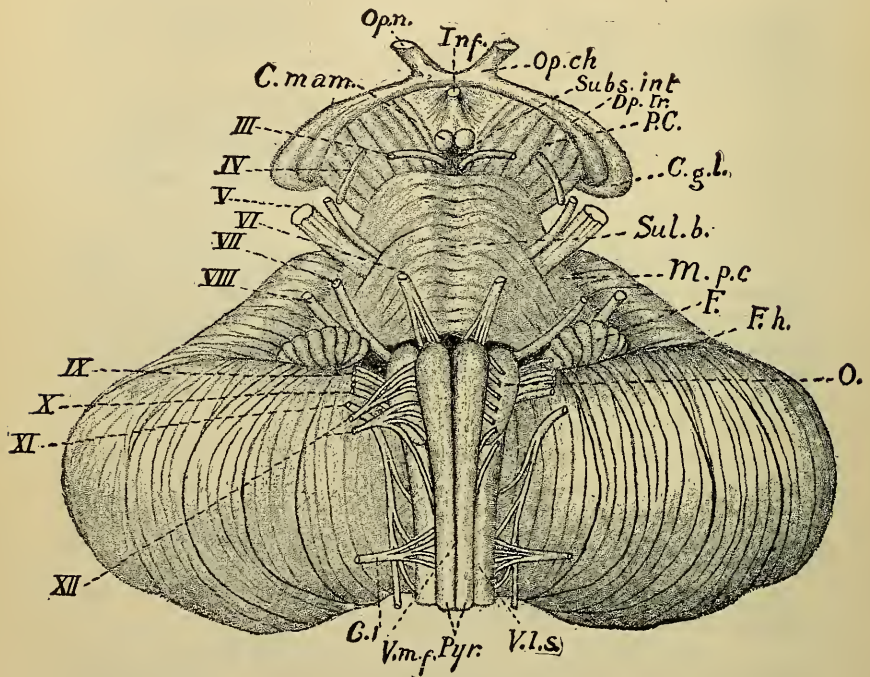

Fig. 105.

Surface anatomy of the myelencephalon. Roman numerals refer to cranial nerves.) *C.* 1, first cervical spinal nerve; *C. mam*, corpus mammillare; *Op. n.*, optic nerve; *Inf.*, infundibulum; *Op. ch.*, optic chiasm; *Subs. int.*, substantia interpeduncugeniculate body; *Sub. b.*, basilar sulcus; *M. p. c.*, middle peduncle of cerebellum; *F.*, flocculus; *F. h.*, horizontal fissure; *O.*, olive; *V. l. s.*, ventrolateral sulcus; *Pyr.*, pyramid; *V. m. f.*, ventral median fissure. (*Whitehead, after Van Gehuchten.*)

passage of the basilar artery. The upper surface forms a portion of the floor of the fourth ventricle (*fossa rhomboidea*), and on either side, under the name of the crus, passes to the cerebellum, forming its middle peduncle (*brachia pontis*).

CEREBELLUM.

The *cerebellum*, or little brain, occupies the inferior occipital fossæ beneath the great cerebral lobes, from which it is separated by the tentorium. Its average weight is a little over five ounces in the male, and is proportioned to the greater brain about one to twenty. It is oblong, flattened from above downward, and divided into two lateral hemispheres connected by a central portion, the vermiform process (*vermis*).

It is composed of gray and white matter—the former upon the surface. It is not convoluted, like the cerebrum, but consists of a number of thin plates, *folia*, arranged in a series of crescentic curves, with the concavity forward.

The cerebellum consists of a central lobe (*vermis*), and two lateral hemispheres (*hemisphæria cerebelli*). The latter are separated on the inferior surface of the cerebellum by a deep hollow, the valley or vallecula (*vallecula cerebelli*), which lodges the medulla oblongata. The floor of the vallecula is formed by the inferior portion of the vermis.

The incisura semilunaris (*incisura cerebelli anterior*) separates the hemispheres in front, and rests against the corpora quadrigemina;

The incisura marsupialis (*incisura cerebelli posterior*) separates the hemispheres behind, and receives the upper portion of the falx cerebelli;

The great horizontal fissure (*sulcus horizontalis cerebelli*) separates the cerebellum into a superior and an inferior surface.

The upper surface (*facies cerebelli superior*) shows the superior vermis (*vermis superior cerebelli*), with its corresponding lobes in the hemispheres. These latter are separated from each other by fissures. The following table gives the arrangement of the lobules:—

GREAT HORIZONTAL FISSURE.

Pre-	Frænulum	Lingula.	Frænulum	central fissure.
Post-	Ala.	Lobus centralis.	Ala.	central fissure.
Pre-	Anterior crescentic lobe.	Lobus culminis.	Anterior crescentic lobe.	clival fissure.
Post-	Posterior crescentic lobe.	Lobus clivi.	Posterior crescentic lobe.	clival fissure.
Great	Posterior superior lobe	Folium cacuminis.	Posterior superior lobe.	horizontal fissure.

The inferior surface (*facies cerebelli inferior*) of the cerebellum presents the deep depression, the vallecula, which renders the connection between the vermis and the hemispheres less intimate. The divisions of the vermis and their corresponding lobules in the hemispheres are as follows:—

Great				horizontal fissure.
	Slender lobe, post-gracile, posterior inferior lobule.	Tuber valvulæ.	Posterior inferior lobule.	
Post-				pyramidal fissure.
	Lobulus biventer.	Pyramis.	Lobulus biventer.	
Pre-				pyramidal fissure.
	Amygdala.	Uvula.	Amygdala.	
Post-				nodular fissure.
	Flocculus.	Nodule.	Flocculus.	
Great				horizontal fissure.

The cerebellum is connected with the encephalon by the *peduncles* of the *cerebellum,* three in number, from above downward, as follows:—

Crura ad cerebrum, superior cerebellar peduncles, or processus e cerebello ad testes (*brachia conjunctiva cerebelli*), pass to the cerebrum;

Crura ad posterior, middle cerebellar peduncles, or processus ad pontem (*brachia pontis*), the transverse fibers of the pons Varolii, connect the hemispheres;

Crura ad medullam, inferior cerebellar peduncles or processus e cerebello ad medullam, the restiform bodies of the medulla oblongata (*corpora restiformia*), connect with medulla oblongata.

The internal *structure* of the cerebellum consists of an arbor vitæ arrangement of gray matter, inclosing a white mass. In center of the latter is found a grayish, dentated mass, the corpus dentatum (*nucleus dentatus*), an irregular capsule of gray matter opening anteriorly.

THE CEREBRUM

consists of a large, ovoidal mass, divided into two lateral halves, or hemispheres (*hemisphæria cerebri*), by the great longitudinal

fissure (*fissura longitudinalis cerebri*), connected by a white, transverse commissure—the corpus callosum. The surface is irregularly marked by convolutions, or gyri (*gyri cerebri*), separated from each other by irregular depressions, fissures (*fissuræ*), or sulci (*sulci cerebri*). The outer surface is composed of gray matter, which, from its location, is called the cortical substance. The interior surface, for the most part, is white.

FIG. 106.

Left side of human cerebrum. *S. fr. s.*, superior frontal sulcus; *S. præc.*, precentral sulcus; *S. R.*, central sulcus of Rolando; *S. poste.*, Post-central sulcus; *S. interp.*, interparietal sulcus; *S. p. o.*, parieto-occipital fissure; *Ram. post. S.*, posterior ramus of fissure of Sylvius; *S. temp. m.*, middle temporal sulcus; *S. temp. s.*, superior temporal sulcus; *F. S.*, fissure of Sylvius; *R. ant. asc. S.*, ascending anterior ramus of fissure of Sylvius; *R. s. h. S.*, horizontal anterior ramus of fissure of Sylvius; *S. fr. inf.*, inferior frontal sulcus. (*Whitehead, after Van Gehuchten.*)

The principal fissures of the brain are five, as follows:—

1. The great longitudinal fissure (*fissura longitudinalis cerebri*), separating the two hemispheres from one another.

2. The great transverse fissure of Bichât (*fissura cerebri transversa*), between the cerebellum and the cerebrum, admitting the pia mater to form the velum interpositum.

3. The fissure of Sylvius (*fissura cerebri lateralis* [Sylvii]), beginning at the anterior perforated space and ascending obliquely.

4. The fissure of Rolando (*sulcus centralis* [Rolandi]), descends from near the middle of the great longitudinal fissure to join the fissure of Sylvius.

5. The parieto-occipital fissure (*sulcus occipitoparietalis*), on the postero-lateral aspect of the cerebrum.

6. The callosomarginal fissure (*sulcus singulus*).

7. The collateral fissure (*fissura collateralis*).

8. The limiting sulcus of Reil (*sulcus circularis* [Reili]).

The principal lobes of the brain are six, as follows:—

1. Frontal lobe (*lobus frontalis*), on the outer surface of the brain; it is bounded below by the fissure of Sylvius, and behind by the fissure of Rolando. On the mesial surface it is bounded by the callosomarginal fissure, and on the inferior surface it is bounded behind by the stem of the Sylvian fissure.

On the outer surface it is divided into the

(*a*) Ascending frontal convolution (*gyrus frontalis ascendens*);

(*b*) Superior frontal convolution (*gyrus frontalis superior*);

(*c*) Middle frontal convolution (*gyrus frontalis medius*);

(*d*) Inferior frontal convolution (*gyrus frontalis inferior*);

On the mesial surface it is divided into

(*a*) Marginal gyrus (*gyrus marginalis*);

(*b*) Paracentral lobule (*lobulus paracentralis*).

On the orbital surface it is divided into

(*a*) Internal orbital convolution (*gyrus orbitalis internus*);

(*b*) Anterior orbital convolution (*gyrus orbitalis anterior*);

(*c*) Posterior orbital convolution (*gyrus orbitalis posterior*).

2. Parietal lobe (*lobus parietalis*), lies between the fissure of Rolando, the parieto-occipital, and the fissure of Sylvius, and consists of five gyri:—

(*a*) Ascending parietal (*gyrus centralis posterior*);

(*b*) Superior parietal (*lobulus parietalis superior*);

(*c*) Inferior parietal (*lobulus parietalis inferior*), { Supramarginal (*gyrus supramarginalis*), Angular (*gyrus angularis*), Post parietal;

3. Occipital lobe (*lobus occipitalis*) lies at the posterior aspect of the cerebrum and is divided into first, second and third occipital convolutions.

4. Temporosphenoidal lobe or temporal lobe (*lobus temporalis*), occupies the middle fossa of the skull.

5. *Island of Reil*, or central lobe, lies within the fissure of Sylvius. It consists of six convolutions—the *gyri operti*.

6. The limbic lobe surrounds the corpus callosum. Its extremities are united by the roots of the olfactory tract.

The inner or median surface of the hemispheres presents five fissures, as follows:—

1. Callosomarginal (*sulcus cingulus*).
2. Parieto-occipital (*sulcus occipitoparietalis*).
3. Calcarine (*fissura calcarina*).
4. Occipitotemporal or collateral (*fissura collateralis*).
5. Dentate fissure, or sulcus hippocampi (*fissura hippocampi*).

The lobes on the internal surface are six in number, as follows:—

1. Callosal convolution (*gyrus fornicatus* or *gyrus cinguli*), descends as the gyrus hippocampi and terminates as the uncinate gyrus.
2. Marginal (*gyrus marginalis*), or first frontal convolutions.
3. Quadrate (*præcuneus*).
4. Cuneus, or occipital lobule (*lobus occipitalis*).
5. Uncinate gyrus.
6. Temporosphenoidal lobe or temporal lobe (*lobus temporalis*).

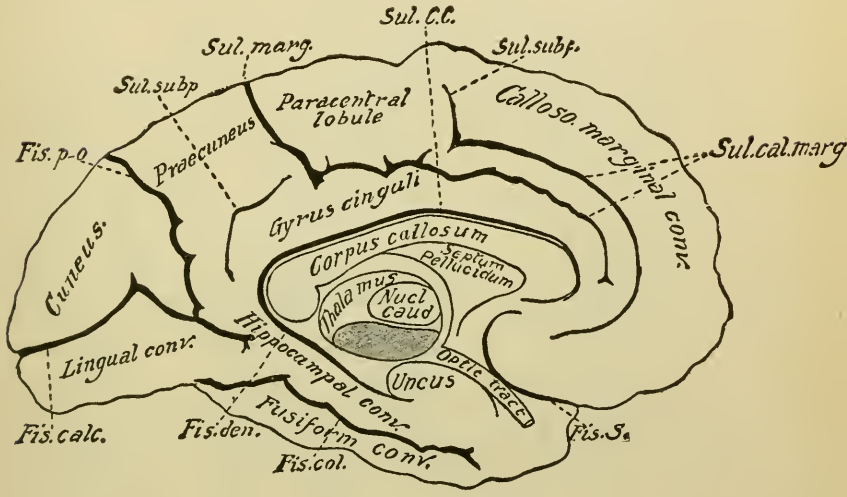

FIG. 107.

Convolutions and fissures of the median and tentorial surfaces of the right cerebral hemisphere. *Fis. S.*, fissure of Sylvius; *Sul. cal. marg.*, callosomarginal sulcus; *Sul. subf.*, subfrontal sulcus; *Sul. C. C.*, sulcus of corpus callosum; *Sul. marg.*, marginal sulcus; *Sul. subp.*, subparietal sulcus; *Fis. p. o.*, parieto-occipital fissure; *Fis. calc.*, calcarine fissure; *Fis. den.*, dentate fissure; *Fis. col.*, collateral fissure. (*Whitehead, after Van Gehuchten.*)

The inferior surface (*facies basalis encephali*) of each hemisphere is divided into three lobes—the anterior, middle and posterior. The two former occupy the anterior and middle fossa of the skull and the posterior rests upon the cerebellum, separated from it by the tentorium. This surface presents for study from before backward the following points:—

The longitudinal fissure (*fissura longitudinalis cerebri*), separates the two hemispheres;

Corpus callosum, the great transverse commissure of the cerebrum, extending by means of its *peduncles* to near the Sylvian fissure;

Lamina cinerea, is a thin, gray layer, forming the anterior part of the inferior boundary of the third ventricle;

Olfactory nerve, with its bulb;

Fissure of Sylvius (*fissura cerebri lateralis* [Sylvii]), between the anterior and middle lobes of the cerebrum, and lodges the middle cerebral artery;

Anterior perforated space (*locus perforatus anticus* or *substantia perforata anterior*), transmits vessels to the corpus striatum;

Optic commissure (*chiasma opticum*), is formed by the junction of the optic tracts;

Tuber cinereum, is a gray eminence between the corpora albicantia and optic tracts, and forms part of the floor of the third ventricle;

Infundibulum, is a tube of gray matter connecting the pituitary body with the third ventricle;

Pituitary body (*hypophysis cerebri*), is a small, vascular, bilobed body, connected by the infundibulum and occupying the sella turcica (for histology *ride* "Ductless Glands");

Corpora albicantia, or mammillaria, are two white, rounded masses, formed by the folding of the anterior crura of the fornix, and are sometimes called the bulbs of the fornix;

Posterior perforated space (*locus perforatus posticus;* or *substantia perforata posterior*), allows the passage of blood-vessels to the optic thalami;

Crura cerebri (*pedunculi cerebri*), or cerebral peduncles, connect the cerebrum with the medulla, cerebellum, and spinal cord; they consist of the anterior portion, or *crusta*, and the posterior portion, or *tegmentum*, between which is a mass of gray matter—the *locus niger;*

Pons Varolii, covers up the posterior portion of the cerebral lobes.

Interior of the Cerebrum.—The interior of the cerebrum, viewed above the level of the corpus callosum, presents a white surface—the *centrum ovale minus,* the margins of which are convoluted gray matter, and are called *labia cerebri.* It is studded throughout with minute blood vessels—puncta vasculosa.

The hemispheres, viewed on a level with the corpus callosum, present a large white mass—the *centrum ovale majus*—in the center of which is the connecting band, the corpus callosum.

Corpus Callosum.—This connecting band forms the roof of the lateral ventricles. It is about four inches in length and varies from an inch and a half to two inches in width, presenting in front a bend, or genu (*genu corporis callosi*), below which it terminates in the tuber cinereum through the lamina cinerea.

Posteriorly it forms a thick, rounded fold—the splenium (*splenium corporis callosi*), or pad—which is continuous with the *fornix.*

The peduncles of the corpus callosum (*gyrus subcallosus* or *pedunculus corporis callosi*) are two reflected bundles of white matter given off near the anterior termination of the corpus,

and each passing backward across the anterior perforated space of its own side to the *fissure of Sylvius.*

The superior surface of the *corpus callosum* shows a de-

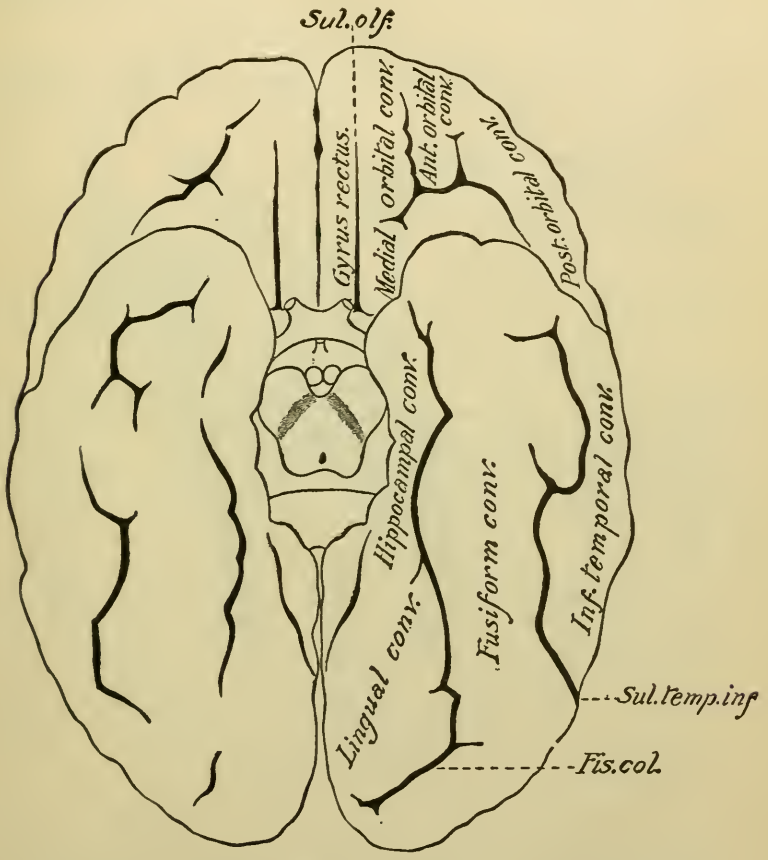

FIG. 108.

Inferior aspect of cerebral hemisphere. *Sul. olf.*, olfactory sulcus; *Sul. temp. inf.*, inferior temporal sulcus; *Fis. col.*, collateral fissure. (*Whitehead, after Van Gehuchten.*)

pression—the raphé—bounded on each side by elevated bands, the *striæ longitudinales*, or nerves of Lancisi. External to these are the *striæ longitudinales laterales.* On either side of the

raphé are many transverse lines—the lineæ transversæ, which indicate the direction of the fibers of the *corpus*.

The cerebral commissures are connecting bands of gray and white matter, pursuing either a transverse or anteroposterior course.

Transverse:—

Anterior (*commissura anterior cerebri*), middle, gray, or soft commissure (*massa intermedia* or *commissura mollis*), and posterior commissure;
Corpus callosum;
Optic chiasm (*chiasma opticum*);
Fornix;
Pons Varolii;
Posterior medullary velum (*velum medullare posterius*).

Anteroposterior:—

Corpus callosum (nerves of Lancisi);
Fornix;
Fasciculus uncinatus (*uncinate fasciculus*);
Tænia semicircularis (*striæ terminalis*);
Callosal convolution (*gyrus fornicatus*);
Inferior longitudinal fasciculus (*fasciculus longitudinalis inferior*);
Olfactory tracts (*tractus olfactorius*);
Crura cerebri (*pedunculi cerebri*);
Peduncles of pineal gland (*habenula*);
Processus e cerebello ad testes.

VENTRICLES OF THE BRAIN.

The interior of the brain contains five distinct cavities, named the *ventricles* of the *brain*, situated as follows: Two lateral ventricles (*ventriculus lateralis*), in the upper part, within the substance of the hemispheres, the third ventricle (*ventriculus tertius*) between the optic thalami at the base of the brain, the fourth ventricle (*ventriculus quartus*) between the medulla oblongata and the cerebellum, and the fifth ventricle within the septum lucidum between the two lateral ventricles.

The ventricles intercommunicate—the two lateral ventricles with the third by means of the foramen of Monro (*foramen interventriculare*), the third with the fourth ventricle by means of the iter a tertio ad quartum ventriculum (*aquæductus cerebri*), and, in the fetus, with the fifth, and through the infundibulum with the cavity of the pituitary body.

The lateral ventricle (*ventriculus lateralis*) is bounded as follows:—

The *roof*, the corpus callosum; the *floor* is formed by the following parts from before backward: corpus striatum, tænia semicircu-

laris, optic thalamus, choroid plexus, corpus fimbriatum and fornix; *internally*, by the septum lucidum; *externally*, in front and behind by the brain-substance. *Each lateral ventricle presents three cornua—the anterior cornu, posterior cornu, or digital cavity, and the middle cornu.*

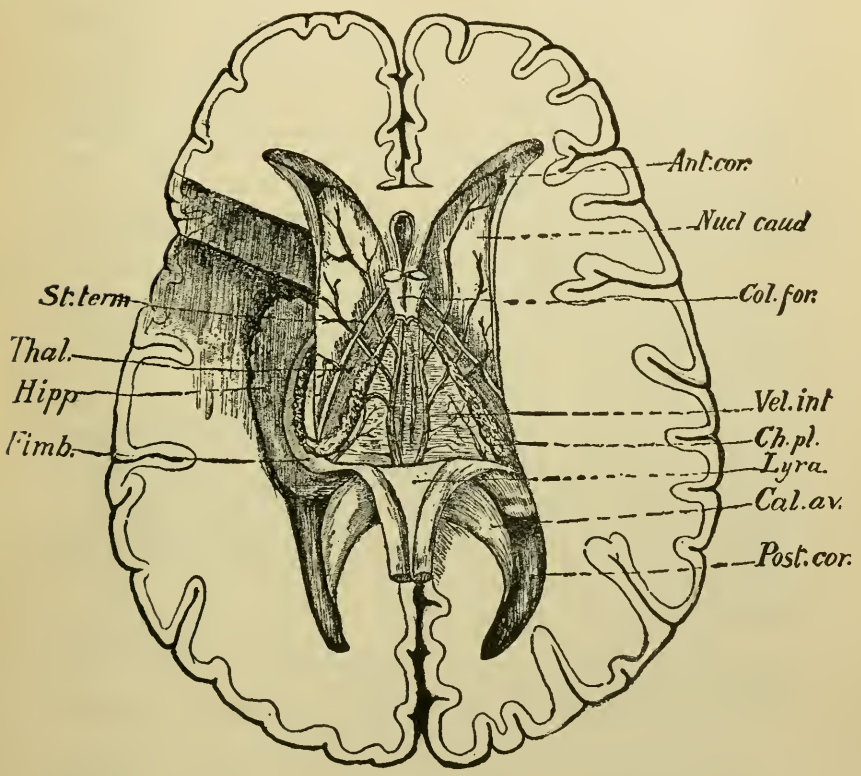

FIG. 109.

The lateral ventricles and choroid plexus. *St. term.*, stria terminalis; *Thal.*, thalamus; *Hipp.*, hippocampus; *Fimb.*, fimbria; *Ant. cor.*, anterior cornu of lateral ventricle; *Nucl. caud.*, nucleus caudatus; *Col. for.*, columns of the fornix; *Vel. int.*, velum interpositum; *Ch. pl.*, choroid plexus; *Cal. av.*, calcar avis; *Post. cor.*, posterior cornu of lateral ventricle (*Whitehead, after Gray.*)

The anterior cornu (*cornu anterius*) curves outward and forward over the corpus striatum and into the anterior lobe.

The middle cornu (*cornu inferius*) passes into the middle lobe, descending to the transverse fissure at the base of the brain.

Its course is backward, outward, downward, forward and inward (B., O., D., F., I.).

The posterior cornu (*cornu posterius*) runs backward into the posterior lobe, its course being backward, outward and inward (B., O., I.).

Parts of Lateral Ventricle—Corpus Callosum.—Described above.

Septum Lucidum (*septum pellucidum*).—Forms the internal boundary of the lateral ventricle. It consists of two layers of white and gray matter, and is attached above to the under surface of the corpus callosum, below to the fornix, and anteriorly to the prolongation of the corpus callosum.

Between the laminæ forming the septum is a narrow interval—the fifth ventricle.

The Corpus Striatum.—Situated in the lateral ventricle, its broad end directed forward into the fore part of the body and anterior cornu of the ventricle, its narrow end directed outward and backward, and separated from its fellow by the thalami optici.

The intraventricular portion is called the caudate nucleus (*nucleus caudatus*), the extraventricular, the lenticular nucleus (*nucleus lentiformis*), the two separated by the internal capsule.

The internal capsule (*capsula interna*) is a large layer of white fibers, derived from the medulla and crura cerebri, separating the lenticular nucleus from the caudate nucleus anteriorly, and the lenticular nucleus from the optic thalamus posteriorly.

The external capsule (*capsula externa*) is a small layer of white fibers on the outer surface of the corpus striatum, between the lenticular nucleus and the claustrum.

The *claustrum* is a convoluted layer of gray fibers between the external capsule and the island of Reil.

The Tænia Semicircularis, or Horny Band of Tarinus stria terminalis).—A band of medullary substance in the furrow between the corpus striatum and the optic thalamus. Its anterior portion descends with the anterior pillar of the fornix, its posterior portion passes into the descending horn. Beneath it is the vena corporis striati.

The choroid plexus (*plexus chorioideus*), a vascular membrane, occupying the margin of a fold of pia mater, known as the velum interpositum (*tela chorioidea superior;* or, *tela chorioidea ventriculi tertii*). It runs across the floor of the lateral ventricle, and communicates with its fellow of the op-

posite side through the foramen of Monro. Posteriorly it descends into the middle horn of the lateral ventricle.

The corpus fimbriatum (*tænia hippocampi* or *tænia fimbriæ*), a narrow white band behind the choroid plexus. It is the lateral edge of the posterior pillar of the fornix.

The *fornix*, a lamella of white fibrous matter, beneath the corpus callosum, continuous with it posteriorly, but separated from it anteriorly by the septum lucidum. It consists of two symmetrical halves which join to form the body (*corpus fornicis*), each half having an anterior and posterior *crus* where they do not join.

The anterior crura (*columnæ fornicis*) curve down to the base of the brain, where each crus spreads out and curves upon itself to form the corpus albicans of that side. From this point it passes to the corresponding optic thalamus.

The posterior crura (*crura fornicis*), at their commencement, are joined to the under surface of the corpus callosum. They pass downward into the descending horns of the lateral ventricles, being continuous with the concave borders of the hippocampi majores.

The lateral edge of the posterior crus is called the corpus fimbriatum.

The lyra is a series of lines, some transverse, others longitudinal and oblique, on the under surface of the fornix, between the diverging posterior crura.

Optic Thalamus (*thalamus*).—The thalami optici are two large ganglionic masses, situated between the diverging portions of the corpora striata. Each thalamus rests upon the corresponding crus cerebri.

The thalamus is bounded externally by the corpus striatum and tænia semicircularis, and internally forms the lateral boundary of the third ventricle.

Its upper surface is partly covered by the fornix. Its under surface forms the roof of the descending horn of the lateral ventricle.

Its posterior and inferior part exhibits two rounded eminences, the external (*corpus geniculatum laterale*) and internal (*corpus geniculatum mediale*) geniculate bodies. Its anterior extremity forms the posterior boundary of the foramen of Monro, which foramen connects the two lateral ventricles with the third.

Velum interpositum (*tela chorioidea ventriculi tertii*), a vascular membrane, reflected from the pia mater into the interior of the brain through the transverse fissure. It passes

beneath the posterior border of the corpus callosum and fornix, and above the corpora quadrigemina, the pineal gland and the optic thalami. It forms the roof of the third ventricle (*plexus chorioidea ventriculi tertii*). Its anterior extremity passes on each side into the corresponding lateral ventricle, forming the anterior extremity of the choroid plexus. The vascular fringes of the velum interpositum projecting into the third ventricle are called the choroid plexuses of the third ventricle.

It has two veins, the venæ Galeni (*vv. cerebri internæ*), which run along its under surface and are formed by the veins of the choroid plexuses and the venæ corporis striata (*v. corporis striata*). The venæ Galeni unite to form a single trunk —vena magna Galeni—(*v. cerebri magna*) and empty into the straight sinus.

The posterior cornu (*cornu posterius*) of the lateral ventricle runs into the *substance* of the posterior lobe. On the floor of this horn is an eminence corresponding to a sulcus between two convolutions, and called the hippocampus minor (*calcar avis*).

Between the posterior and middle (*cornu inferius*) horns is another eminence—the *eminentia collateralis,* or *pes accessorius.*

The hippocampus major, or cornu ammonis (*hippocampus*), a white eminence running the entire length of the floor of the middle horn. This eminence is the doubled-in surface of the gyrus fornicatus.

The lower extremity of the hippocampus major is called the pes hippocampus (*digitationes hippocampi*).

The fascia dentata (*fascia dentata hippocampi*), the gray and serrated edge of the middle lobe. It is really external to the cavity of the middle cornu.

The third ventricle (*ventriculus tertius*) is a mere fissure in the median line of the cerebrum, situated between the optic thalami. It communicates with the lateral ventricle by the foramen of Monro and with the fourth ventricle by the iter a tertio ad quartum ventriculum. The cavity is crossed by three commissures—the anterior commissure, a white, rounded cord; the middle or soft commissure, composed of gray matter; and the posterior commissure, a white band connecting the two optic thalami. It is bounded by the following structures:—

The *roof*, by the velum interpositum, suspending the choroid plexuses of the third ventricle, and *laterally* the peduncles of the pineal gland; *floor*, by the parts inclosing the interpeduncular space at the base of the brain, viz.: the lamina cinerea, tuber cinereum and infundibulum, corpora albicantia and the posterior perforated space; *laterally*,

by the optic thalami; *in front*, by the anterior commissure and anterior crura of the fornix; *behind*, the posterior commissure and the iter a tertio ad quartum ventriculum.

THE FOURTH VENTRICLE (*ventriculus quartus*) is a diamond-shaped cavity between the cerebellum behind and the posterior surface of the medulla oblongata and pons in front. It is inclosed behind by the pia mater, which contains an opening for the exit and entrance of the subarachnoid fluid from the subarachnoidean space of the brain and spinal cord, and a vascular fold of pia mater—the choroid plexus. Its lower

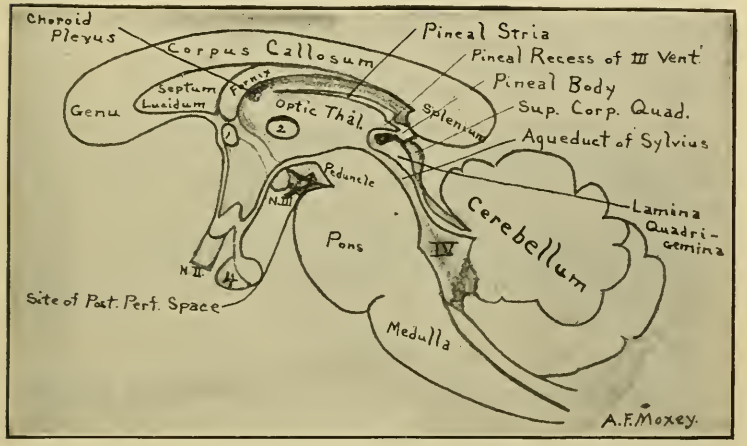

FIG. 110.

Mesial section of brain and brain stem. 1, anterior commissure; 2, middle commissure; 3, posterior commissure; 4, pituitary body; IV, fourth ventricle.

angle is continuous with the central canal of the spinal cord; and from the resemblance it bears to a writing-pen, the name *calamus scriptorius* is applied. It communicates in front with the third ventricle by the iter a tertio ad quartum ventriculum. It is bounded as follows:—

The *roof*, valve of Vieussens (*velum medullare anterius*) and the cerebellum, containing in front the foramen of Magendie (*apertura mediatis ventriculi quarti*), by which it communicates with the subarachnoidean space; the *floor*, of rhomboidal outline, is traversed by a vertical median fissure (*sulcus longitudinalis fossæ rhomboideæ*) continuous with the central canal of the cord. At the broadest part of the ventricle are a series of transverse white lines or striæ medullares, de-

rived from the cochlear root and nucleus. These striæ divide the floor into two triangles, a *superior* and an *inferior*. The *inferior* triangle presents a groove, the *fovea inferior*, whose diverging limbs below form the so-called *ala cinerea*, which is a darker colored, triangular space. There are in this locality several *eminences*, corresponding with the nuclei of origin of the pneumogastric, glossopharyngeal and other cranial nerves. The *superior* triangle presents an elevation, produced by underlying white fibers, the fasiculus teres (*colliculus facialis*). Above and external to the fasciculus teres is a depression, the *fovea superior;* and just above this is a bluish area, the *locus cæruleus*. This mottled appearance is caused by the presence of the *substantia ferruginea*, a peculiar pigment of some of the nerve cells and in them, one of the roots of the trifacial nerve terminates. *Anteriorly*, the pons Varolii and medulla oblongata; *posteriorly*, the cerebellum; *laterally*, the processus e cerebello ad testes, the restiform bodies, and posterior pyramids of the medulla.

Its lining membrane is continuous with that of the third ventricle.

THE FIFTH VENTRICLE (*cavum septi pellucidi*) is a narrow fissure, formed within the two laminæ of the septum lucidum, being originally a part of the great longitudinal fissure. It is bounded:—

Above, by the under surface of the corpus callosum;
Below, by the anterior part of the fornix;
Laterally, by the lateral ventricles, from which it is separated by the septum lucidum.

It is not lined with epithelium.

THE MESENCEPHALON includes those portions of the brain substance which connect the cerebrum, cerebellum and medulla oblongata together, and comprises the following structures:—

Crura cerebri, before described (*ante,* p. 306).

The *valve of Vieussens,* or *anterior medullary velum,* is a thin layer of white matter stretched between the processes e cerebello ad testes, and forming the roof of the iter a tertio ad quartum ventriculum. It presents an elevated ridge descending on its upper part from the corpora quadrigemina—the *frænulum.*

Corpora or *tubercula quadrigemina,* or optic lobes, are four spherical eminences, placed in pairs above the valve of Vieussens, and behind the third ventricle, beneath the posterior border of the corpus callosum.

The two anterior are called the nates (*colliculi superiores*), the two posterior the testes (*colliculi inferiores*). The brachia anterior—(*brachium quadrigeminum superius*) and posterior—*brachium quadrigeminum inferius*) are two white cords con-

necting them with the optic thalamus and beginning of the optic tracts.

The *processus e cerebello ad testes* connect them with the cerebellum.

To the outer side of the optic lobes are two small masses called the corpus geniculatum externum (*corpus geniculatum laterale*) and internum (*corpus geniculatum mediale*).

The pineal gland, or epiphysis cerebri (*corpus pineale*), is a small reddish, conical body, resting upon and between the nates. It represents the rudiment of a median eye of certain extinct lizards and amphibia (Spencer). It is attached to the cerebrum by its two peduncles (*habenula*), and is held in position by a fold of the pia mater. It contains a cavity, filled with a viscid fluid and secretory matter composed of phosphate and carbonate of lime, phosphate of magnesia, ammonia, and a little animal matter—the *acervulus cerebri.*

THE INTERNAL STRUCTURE OF THE MEDULLA OBLONGATA.

The anterior and lateral pyramidal tracts of the cord are continued into the medulla oblongata as the pyramids. The lateral pyramidal tracts decussate in the lower part of the medulla.

The anterior ground bundle is continued upward into the medulla as the posterior longitudinal bundle. It lies behind the pyramids in the medulla.

The sensory columns of the cord (Goll and Burdach) are continued into the medulla oblongata and terminate in the funiculus gracilis and cuneatis. They increase in size and each develops a nucleus: the clava and cuneate nucleus, respectively. These fibers partly form the restiform bodies.

The decussation of the sensory fibers takes place at a higher plane than that of the motor fibers. It is also called the decussation of the fillet and it consists of the decussating fibers derived from the clava and the cuneate nucleus. These fibers are called deep arcuate fibers. After decussating the fibers are continued upward behind the pyramids, displacing backward the posterior longitudinal bundle (*fasciculus longitudinalis medialis*).

In the medulla on cross-section are seen the olivary bodies (*nucleus olivaris inferior*), which contain the dentate nuclei.

The restiform bodies (*corpus restiforme*), or inferior cerebellar peduncles, are formed by the direct cerebellar tract, the superficial or external arcuate fibers (*fibræ arcuatæ externæ*), the

internal arcuate fibers (*fibræ arcuatæ internæ*), and the cerebello-olivary fibers.

The *formatio reticularis* is seen behind the pyramids and the *olivary bodies* in the medulla oblongata. It is composed of the deep arcuate fibers, fibers of Gowers's tract and the antero-lateral ground-bundle.

The *gray matter* of the *cord* is continued into the medulla. The *anterior horns* are cut off and displaced by the decussation of the lateral pyramidal tract and the *posterior horns* are displaced outward by the increase in size of the *posterior sensory tracts.* The latter are known as the *nucleus of Rolando* and are capped by the *substantia gelatinosa Rolandi.*

The central canal is expanded into the fourth ventricle. The gray matter forms nuclei for the cranial nerves in the floor of the fourth ventricle.

THE INTERNAL STRUCTURE OF THE PONS VAROLII.

On cross-section the pons is seen to consist of a dorsal *tegmental* part, and a ventral part, or crusta (*pars basilaris pontis*).

The *crusta* is composed of transverse fibers (fibers from the cerebellum to the pons and from the nucleus pontis to the cerebellum), superficial (*fibræ pontis superficiales*) and middle, which go to form the *middle cerebellar peduncles; longitudinal fibers,* which belong to the pyramidal tracts, much scattered; and *gray matter,* which here forms a nucleus called the *nucleus pontis.*

The *tegmentum* of the pons contains a thick layer of *gray matter,* which forms the floor of the fourth ventricle, and from which cranial nerves take their origin; formatio reticularis, which is the continuation upward of the same from the medulla; the superior olivary nucleus (*nucleus olivaris superior*); the posterior longitudinal bundle (*fasciculus longitudinalis medialis*); the fillet (*lemniscus*); the superior cerebellar peduncle (*brachium conjunctivum*); and the corpus trapezoides.

The fillet occupies a position between the crusta and tegmentum, and to differentiate it from a tract that makes its appearance above the nucleus of the third nerve is called the mesial fillet (*lemniscus medialis*).

The other tract is named the lateral fillet.

The lateral fillet (*lemniscus lateralis*) is composed of longitudinal fibers which take origin from the nucleus of the eighth cranial nerve (*cochlearis*) of the same side, from that

of the opposite side, and from the superior olive. They end in the inferior quadrigeminal body, the internal geniculate body, and a few in the superior quadrigeminal body.

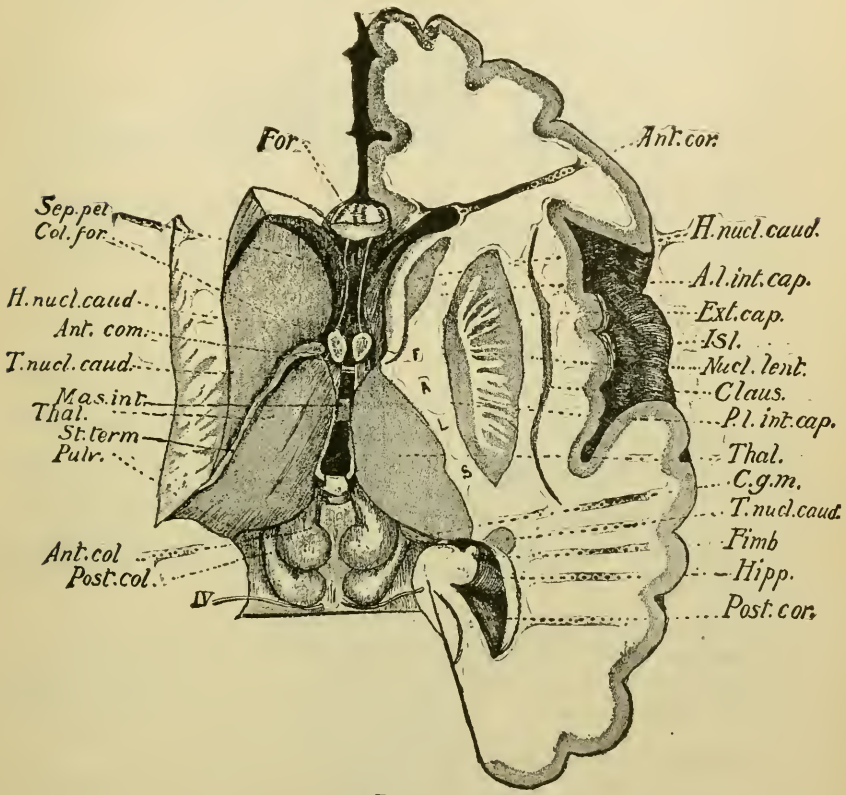

FIG. 111.

Interior of mesencephalon. *For.*, fornix; *Sep. pel.*, septum pellucidum; *Col. for.*, column of fornix; *H. nucl. caud.*, head of nucleus caudatus; *Ant. com.*, anterior commissure; *T. nucl. caud.*, tail of nucleus caudatus; *Mas. int.*, massa intermedia; *Thal.*, thalamus; *St. term.*, stria terminalis; *Pulv.* pulvinar; *Ant. col.*, anterior colliculus; *Post. col.*, posterior colliculus; *IV*, Trochlear nerve; *Ant. cor.*, anterior cornu of lateral ventricle; *A. l. int. cap.*, anterior limb of internal capsule; *Ext. cap.*, external capsule; *Isl.*, island of Reil; *Nucl. lent.*, nucleus lentiformis; *Claus.*, claustrum; *P. l. int. cap.*, posterior limb of internal capsule; *Hipp.*, hippocampus; *Post. cor.*, posterior cornu of lateral ventricle. (*Whitehead, after Landois.*)

The mesial fillet has been described. It takes its origin in the medulla from the cuneate and gracile nuclei of the opposite

side. Some of its fibers end in the superior quadrigeminal body, but the remainder pass through the subthalamic tegmental region into the posterior part of the lateral nucleus of the optic thalamus. Some end here, while some are continued through the thalamus, enter the corona radiata, and pass to the posterior central gyrus of the Rolandic region.

THE STRUCTURE OF THE CEREBELLUM.

On section the gray matter of the cerebellum is found to occupy the cortex (*substantia corticalis*); to its arborescent appearance the term *arbor vitæ* has been applied.

The white matter, medullary body, of each hemisphere contains a nucleus of gray matter: the corpus dentatum (*nucleus dentatus*).

The middle peduncles connect the cerebellum with the pons.

The inferior peduncles, or restiform bodies, or crura ad medullam (*corpora restiformia*), connect the medulla and cord with the cerebellum.

The superior peduncles (*brachia conjunctiva cerebelli*) connect the cerebellum with the cerebral cortex. After decussating below the corpora quadrigemina some of the fibers pass to the opposite red nucleus (*nucleus tegmenti*) in the tegmentum of the crura cerebri passing through the optic thalamus to end in the Rolandic region, and others end in the optic thalamus. Each superior peduncle contains both afferent and efferent fibers.

The cerebellar cortex consists of two layers: an outer, *molecular* layer, and an inner, *granular* layer. Between these two layers is a single layer of large cells, the corpuscles of Purkinje.

THE STRUCTURE OF THE MID-BRAIN.

The mid-brain consists of a dorsal part, the corpora quadrigemina, and a ventral part, the crura cerebri.

It is tunneled by the aqueduct of Sylvius, which connects the fourth ventricle with the third ventricle.

The upper end of the crura cerebri is encircled by the optic tract.

On section the crura cerebri show a ventral and lateral portion,—the tegmentum,—and a dorsal portion, the lamina quadrigemina. The ventral portion contains the *substantia nigra*. The fissure of Sylvius is surrounded by gray matter, from which the third and fourth cranial nerves take origin.

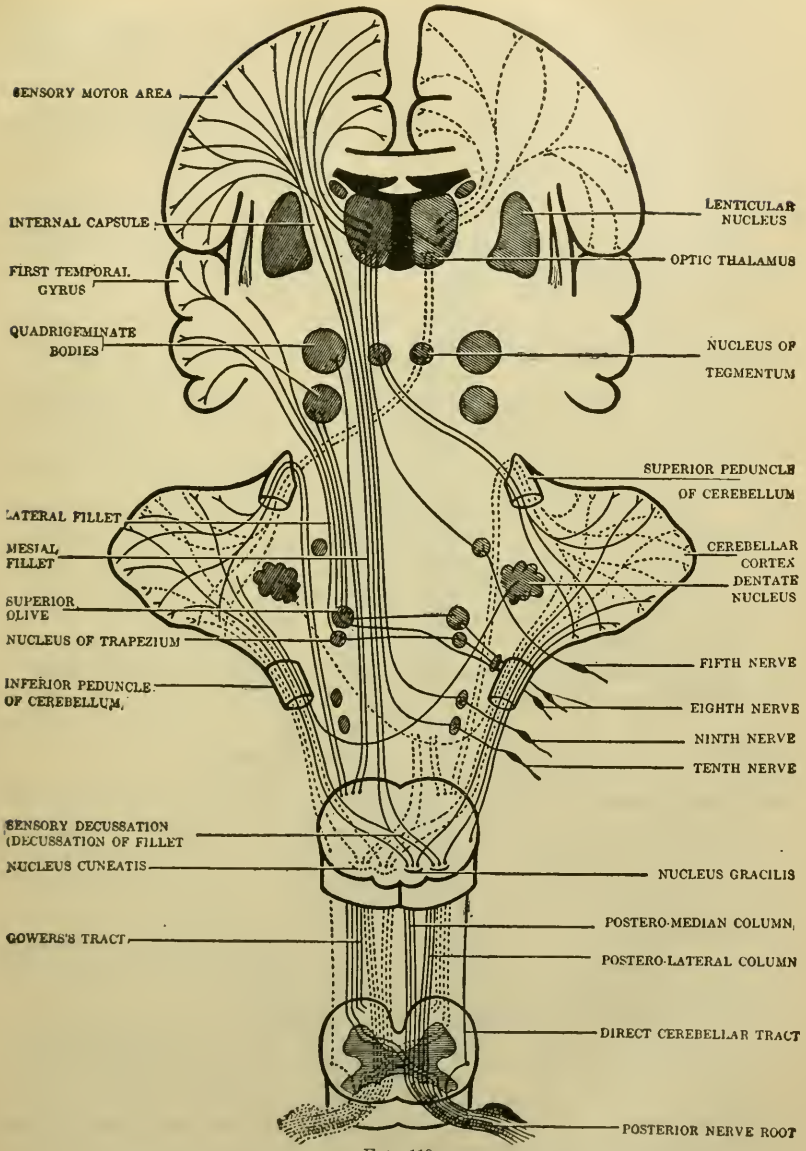

FIG. 112.

Diagram of sensory tracts from spinal cord to brain (original).

The inferior or posterior quadrigeminal bodies contain the fibers of the lateral fillet posteriorly and the brachium laterally.

The superior or anterior quadrigeminal bodies consist of four strata: stratum zonale, stratum cinereum, stratum opticum and stratum lemnisci. The mesial and upper fillet in part end in the latter, which also contains large nerve cells.

Some fibers from the occipital lobe and fibers from the retina, conveyed by the superior brachium, end in the superior quadrigeminal bodies.

The superior cerebellar peduncles have been described; they connect the cerebellum with the cerebral cortex.

The red nucleus (*nucleus tegmenti*) is found in the tegmentum. Some of the fibers of the superior cerebellar peduncles end there.

The posterior longitudinal bundle lies in the tegmentum and is the continuation upward of the tract of the same name in the medulla and pons. It is connected with the nuclei of the motor nerves of the muscles of the eyeball.

The lateral fillet is continued upward from the pons in the tegmentum. Its connections with the superior olivary nuclei and the nuclei of the eighth nerve have been described.

The mesial fillet likewise is continued upward from the pons in the tegmentum of the crura. The course of the fibers has been described.

The crusta of the crura contains the pyramidal fibers and the corticopontine fibers.

THE STRUCTURE OF THE CEREBRUM.

On cross-section the cut brain surface shows an outer gray cortex and the inner white matter and cavities (*centrum ovale*), one to each hemisphere: the lateral ventricles. The white matter contains certain masses of gray matter: the optic thalami and the corpora striata, which latter are on each side of the brain divided into the caudate and lenticular nuclei by the internal capsule. Between the optic thalamus and caudate nucleus on the inside and the lenticular nucleus on the outside passes the broad band of white fibers known as the internal capsule (*capsula interna*). As it nears the cortex the fibers spread out. To this is given the name corona radiata. Between the external capsule (*capsula externa*) and the cortex of the island of Reil is seen a thin sheet of gray matter: the claustrum.

The white matter between the claustrum and the lenticular nucleus is known as the *external capsule.* On horizontal section

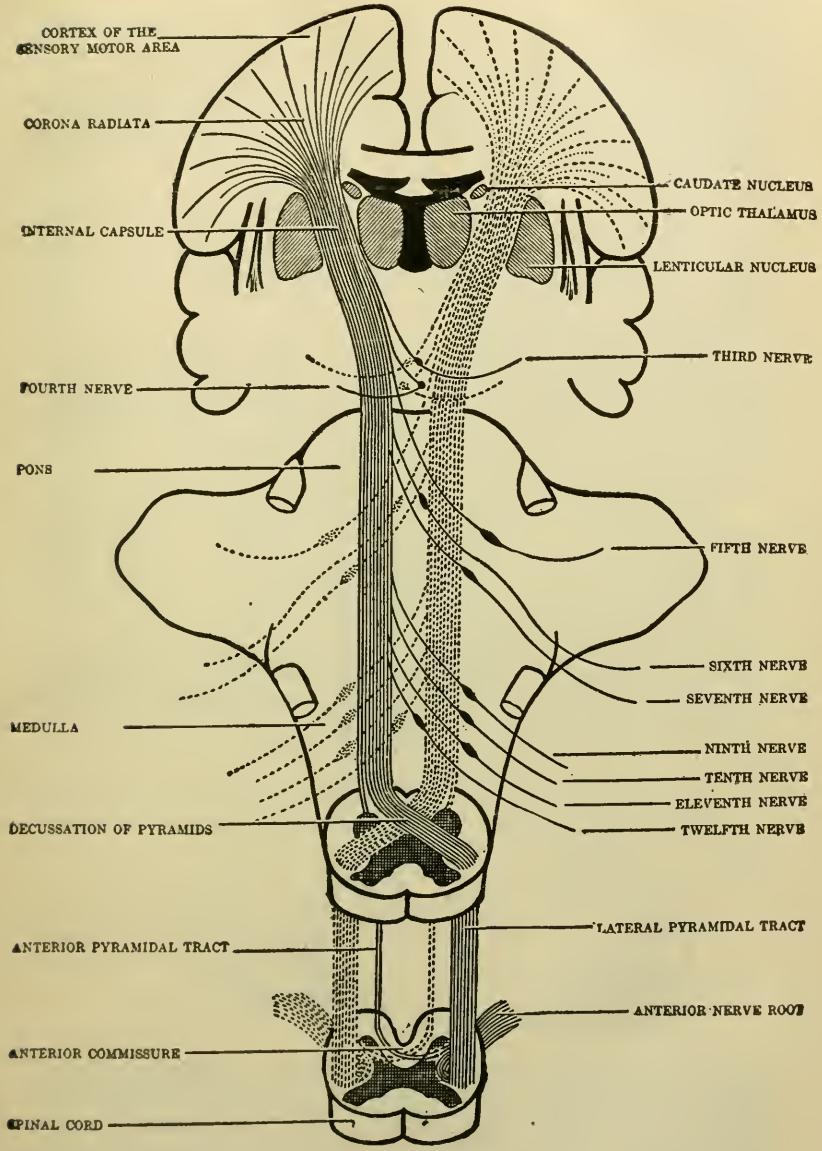

FIG. 113.

Diagram of motor tracts from brain to spinal cord (original).

of the brain the internal capsule is seen to be bent upon itself, the interval between the optic thalamus and the caudate nucleus. This bend is called the genu (*genu capsulæ internæ*). One-third of the capsule lies in front of this bend, and is called the anterior limb (*pars frontalis capsulæ internæ*); the portion behind the genu is called the posterior limb (*pars occipitalis capsulæ internæ*).

The anterior limb contains (1) fibers that pass from the optic thalamus to the lenticular and caudate nucleus, (2) fibers that pass from the optic thalamus to the cortex of the frontal lobe, and (3) fibers that pass from the cortex of the frontal lobe to the nucleus pontis.

The posterior limb contains (1) a continuation upward of a portion of the mesial fillet and the superior cerebellar peduncles, (2) the pyramidal tracts or motor fibers from the Rolandic area, (3) the fibers of the optic radiation (*radiatio occipitothalamica*), (4) the fibers of the auditory radiation (*radiatio temporothalamica*), and (5) the temporopontine tract.

The opposite sides of the brain are connected by the commissural fibers. Convolutions on the same side are connected by association fibers. Projection fibers are those which unite the cerebral cortex with nuclei in lower levels. They pass principally through the corona radiata.

The cerebral cortex consists of five layers: the stratum zonale, the layer of small pyramidal cells, the layer of large pyramidal cells, the layer of polymorphous cells and a layer of fusiform cell-bodies.

CRANIAL NERVES.

The cranial nerves (*nervi cerebrales*) consist of twelve pairs, as follows:—

1. Olfactory,
2. Optic,
3. Motores oculorum,
4. Pathetici,
5. Trifacial,
6. Abducentes,
7. Facial (portio dura),
8. Auditory (portio mollis),
9. Glossopharyngeal,
10. Pneumogastric (vagus, or par vagum),
11. Spinal accessory,
12. Hypoglossal.

1. Olfactory nerve (*n. olfactorius*), special nerve of smell. A number of nerves (20) arise from the olfactory bulb or lobe of the brain. *Superficial origin* of the tract by roots: internal from frontal lobe, middle or gray root from the olfactory tubercle (*trigonum olfactorium*) between the other roots

of the tract, and external from the middle lobe; *deep origin,* from gyrus fornicatus, uncinate gyrus of limbic lobe; *course,* roots unite, pass forward, and form bulbus olfactorius (from this the olfactory nerves are given off); *exit,* foramina of cribriform plate of ethmoid; *distribution,* by three groups to mu-

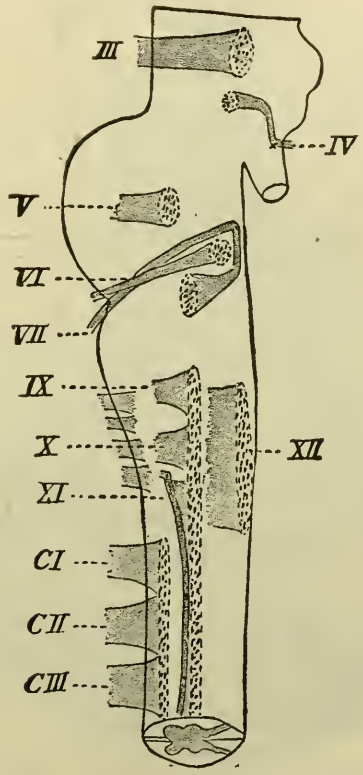

FIG. 114.

Scheme of the nuclei and root-fibers of the cranial nerves. (*Whitehead, after Edinger.*)

cous (Schneiderian) membrane of nares, inner to septum nasi, middle to roof of nasal fossa, outer to superior turbinated bone.

2. OPTIC NERVE (*n. opticus*), special nerve of sight; *superficial origin,* optic chiasma or commissure formed by union of the optic tracts. The commissure and tracts contain intercere-

bral fibers, the cerebroretinal fibers of the same side, and the cerebroretinal fibers of opposite sides. *Deep origin,* the optic tracts arise from optic thalamus, the upper corpora quadrigemina and corpora geniculati; *course,* diverge and pass for-

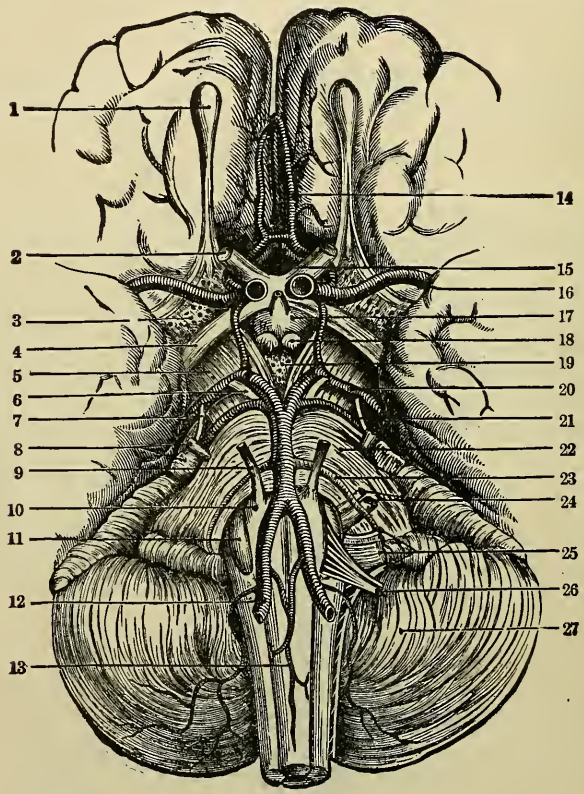

FIG. 115.

Base of brain and cranial nerves; 1, olfactory bulb; 2, optic nerves; 4, tractus opticus; 5, crus cerebri; 6, third pair of nerves; 7, fourth pair of nerves; 8, fifth pair of nerves; 9, sixth pair of nerves; 10, pyramid; 11, olivary body; 22, pons Varolii; 24, seventh and eighth pairs of nerves; 25, ninth, tenth and eleventh pairs of nerves; 26, twelfth pair of nerves; 27, cerebellum.

ward; *exit,* optic foramen; *distribution,* to ganglion cells in the retina.

3. MOTOR OCULI (*n. oculomotorius*), motor nerve; *superficial origin,* inner surface of crus cerebri; *deep origin,* from the

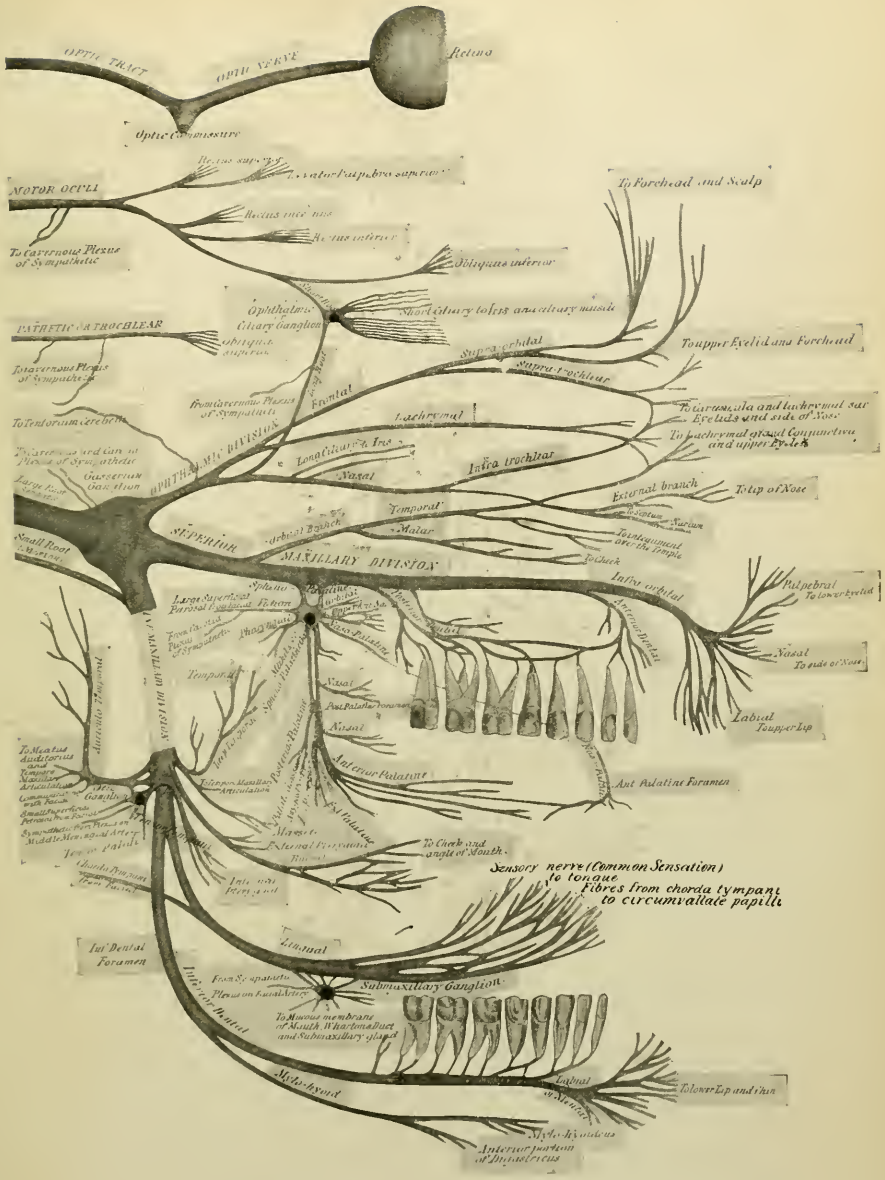

FIG. 116.

Optic, oculomotor, trochlear, and trifacial nerves.

oculomotor nucleus in floor of aqueduct of Sylvius; *course,* from inner side of crus cerebri passes forward, descends along external wall of cavernous sinus; *exit,* sphenoidal fissure between two heads of external rectus muscle; *distribution,* by superior and inferior divisions, to all the ocular muscles (including the iris) *except* the external rectus and superior oblique.

4. Trochlear (*n. trochlearis*—pathetic), motor nerve; *superficial origin,* from valve of Vieussens, on outer side of crus cerebri; *deep origin,* from floor of aqueduct of Sylvius; *course,* outer side of crus cerebri, through outer wall of cavernous sinus; *exit,* sphenoidal fissure; *distribution,* to superior oblique muscle.

5. Trifacial, or Trigeminus (*n. trigeminus*), common sensation, taste and motion; *superficial origin,* by two roots, like a spinal nerve, from the side of the pons Varolii; *deep origin,* the motor root, from (1) a nucleus in the floor of the aqueduct of Sylvius (descending motor root), and (2) from a nucleus in the pons (these join to form the motor root); the sensory root ends in two terminal nuclei—(1) the sensory nucleus of the fifth nerve in the pons, and (2) the substantia gelatinosa Rolandi in the pons, medulla and the spinal cord as far down as the second cervical nerve; *course,* passes forward to apex of petrous portion of temporal bone, where the sensory root enters Gasserian ganglion, the motor passing beneath, and later joins a branch of the ganglion. It divides into three branches—ophthalmic, superior maxillary and inferior maxillary; *exit,* ophthalmic by sphenoidal fissure, superior maxillary by foramen rotundum, inferior maxillary by foramen ovale.

Ophthalmic nerve (*n. ophthalmicus*), entirely sensory, supplies lachrymal gland, upper eyelid, skin and muscles of forehead, eyebrow, nose, eyeball (ciliary muscle, iris, etc.), mucous membrane of eyelids and nose and the ciliary ganglion.

Its branches are:—

Lachrymal (*n. lacrimalis*);
Frontal (*n. frontalis*);
Nasal (*n. nasociliaris*).

Superior maxillary nerve (*n. maxillaris*), entirely sensory also; supplies sensation to upper jaw, teeth, hard and soft palates, tonsils, gums, antrum of Highmore, muscles, skin and mucous membrane of lower eyelid, muscles and skin of cheeks and upper lip, and mucous membrane of floor of nares.

Its branches are:—

Meningeal (*n. meningeus medius*),
Orbital (*n. zygomaticus*),
Spheno-palatine (*n. sphenopalatini*),
Posterior superior dental (*rami alveolares superiores posteriores*),
Middle superior dental (*ramus alveolaris superior medius*),
Anterior superior dental (*ramus alveolaris superior anteriores*),
Palpebral (*rami palpebrales inferiores*),
Nasal (*rami nasales interni*),
Labial (*rami labiales superiores*).

Inferior maxillary nerve (*n. mandibularis*) consists of two portions: anterior or motor, and posterior or sensory, having a threefold function, because one of its branches, the lingual, is joined by the chorda tympani nerve (given off from the facial nerve), which conveys gustatory fibers to the anterior two-thirds of the tongue. It supplies motion to all the muscles of mastication (except to buccinator), anterior belly of digastric and mylohyoideus; sensation to skin of ear, lower part of face, lower lip and tongue. Previous to its division, the primary trunk gives off the recurrent (*n. spinosus*) and the internal pterygoid (*n. pterygoideus internus*). Immediately below the base of the skull it divides into an anterior and a posterior portion. Its branches are:—

Anterior Portion.

Masseteric (*n. massetericus*),
Deep temporal (*nn. temporales profundi*) (2),
Buccal (*n. buccinatorius*),
Pterygoid (*n. pterygoideus externus*),

Posterior Portion.

Auriculotemporal (*n. auriculotemporalis*),
Inferior dental (*n. alveolaris inferior*),
Lingual (*n. lingualis*).

The fifth nerve has four ganglia connected with it:—

(*a*) Ophthalmic, or lenticular (*ganglion ciliare*);
(*b*) Sphenopalatine, or Meckel's (*ganglion sphenopalatinum*);
(*c*) Otic, or Arnold's (*ganglion oticum*);
(*d*) Submaxillary (*vide* Sympathetic System) (*ganglion submaxillare*).

6. Abducens (*n. abducens*), motor; *superficial origin,* pyramidal body and pons Varolii; *deep origin,* floor of fourth ventricle; *course,* passes forward in cavernous sinus; *exit,* sphenoidal fissure; *distribution,* to external rectus muscle.

7. Facial (*n. facialis*), motor nerve; *superficial origin,* lateral tract of medulla and pons Varolii; *deep origin,* from a nucleus in the pons, deeply placed, from which the fibers ascend

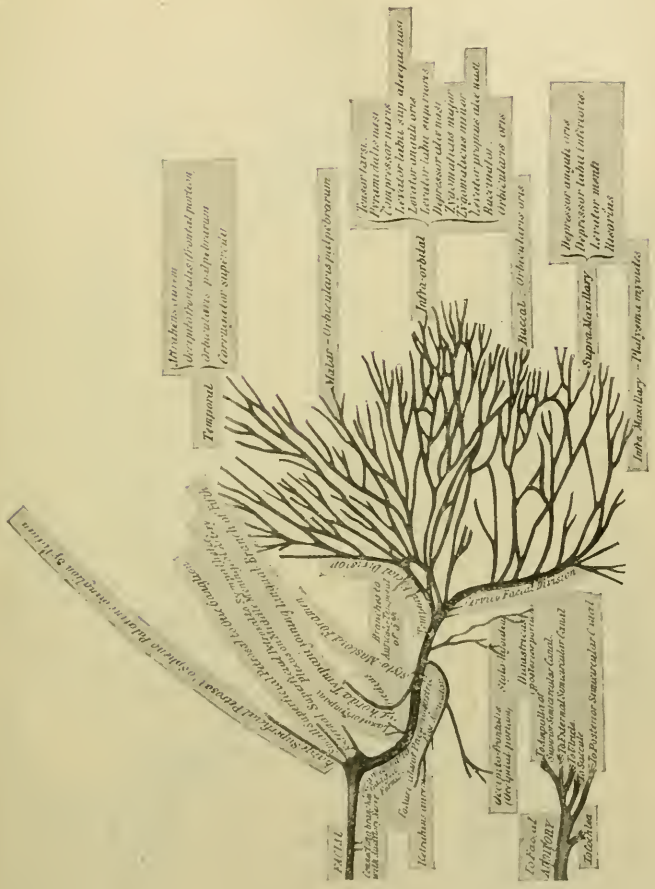
Temporal
Malar - Orbicularis palpebrarum
Infra-orbital
Buccal - Orbicularis oris
Supra-Maxillary
Infra-Maxillary - Platysma myoides
Cervico Facial Division
Temporal Facial Division
Occipito-frontalis (Occipital portion)
Stylo-Hyoidea
Stylo-Mastoid Foramen
Hetrahus auris
FACIAL
To Facial AURICULAR
To Lachrymal
To Posterior Semicircular Canal
To Posterior Semicircular Canal
To Sacculus
To Cochlea

FIG. 117.

close to the floor of the fourth ventricle, where they form the eminentia teres, arch over the nucleus of the sixth nerve, and then emerge (this nerve carries some sensory fibers, probably gustatory fibers from the tongue, through the chorda tympani nerve to the pars intermedia [*n. intermedius*], near the nucleus of the ninth nerve); *course,* forward and outward, through internal auditory meatus, aqueductus Fallopii and inner wall of tympanum; *exit,* stylomastoid foramen; *distribution,* to muscles of expression, buccinator, and platysma, posterior belly of digastric, stylohyoid attrahens and retrahens aurem muscles, to laxator tympani and stapedius through tympanic branch, dorsal surface of tongue through chorda tympani, and levator palati, and azygos uvulæ muscles through Vidian. In its course through the temporal bone it communicates with many important nerves; in the internal auditory meatus, with auditory (*portio mollis*); in aqueductus Fallopii, with otic ganglion, by the small petrosal; Meckel's ganglion, by the large petrosal nerve; the sympathetic of the great meningeal, by the external petrosal nerve; and at its exit from the stylomastoid foramen, with the glossopharyngeal, pneumogastric, auriculotemporal, auricularis magnus and the carotid plexus. Its branches are:—

In Aqueductus Fallopii.

Tympanic (*n. stapedius*).
Chorda tympani.

After Exit from Stylomastoid Foramen.

On the Face.

- Temporofacial,
  - Temporal (*rami temporales*).
  - Malar (*rami zygomatici*).
  - Infraorbital (*rami buccales*).
- Cervicofacial,
  - Buccal (*rami buccales*).
  - Supramaxillary (*ramus marginalis mandibulæ*).
  - Inframaxillary (*ramus colli*).
- Posterior auricular,
- Stylohyoid (*ramus stylohyoideus*),
- Digastric (*ramus digastricus*).

8. Auditory (*n. acusticus*), special nerve of hearing, consists of two portions—(1) cochlear, or auditory portion, and (2) vestibular, or fibers whose function is to localize position.

The former pass from the cochlea to the (1) accessory auditory nucleus in the medulla, and (2) to the lateral acoustic tubercle in the medulla. These fibers, by means of the lateral fillet, communicate with the inferior corpora quadrigemina.

The vestibular fibers (*fibræ vestibularis*) pass from the vestibule to the external and internal dorsal nuclei in the floor of the fourth ventricle, and by the sensory decussation to the nucleus cuneatus.

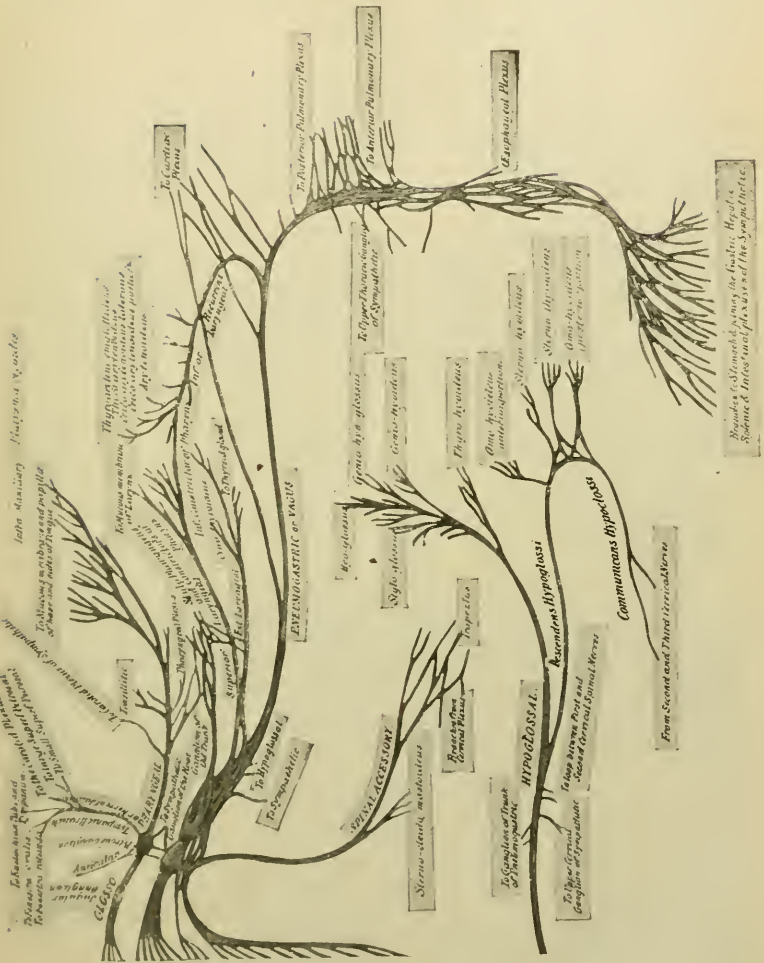
To Cardiac Plexus
To Posterior Pulmonary Plexus
To Anterior Pulmonary Plexus
Œsophageal Plexus
To Upper Thoracic Ganglion of Sympathetic
Branches to Stomach & pass thro the Gastric Hepatic Splenic & Intestinal plexuses of the Sympathetic
Iris
Ciliary Nerves
Superior Cervical Ganglion
Pharyngeal Plexus
Tonsillitic
To Hypoglossal
To Sympathetic
Ganglion of Trunk of the Sympathetic
To Upper Cervical Ganglion of Sympathetic
Branches from Cervical Plexus
Sterno-cleido mastoideus
SPINAL ACCESSORY
HYPOGLOSSAL
Descendens Hypoglossi
Communicans Hypoglossi
From Second and Third Cervical Nerves
Genio hyoideus
Thyro hyoideus
Sterno hyoideus
Stylo glossus
Hyo glossus
Genio hyo glossus
Tongue
Epiglottis
Larynx
Trachea
Œsophagus
Aorta
Heart
Lungs
Diaphragm
Liver
Spleen
Stomach
Pancreas
Kidneys
Bladder
Uterus
Testicle
Penis
Scrotum
Thigh
Leg
Foot
Arm
Hand
Face
Head
Neck
Back
Chest
Abdomen
Pelvis

FIG. 118.

Superficial origin, from groove between olivary and restiform bodies; *course,* winds around restiform body, and passes forward to internal auditory meatus, with the facial; *distribution,* to internal ear by two branches:—

Vestibular, and Cochlear (*vide* Ear, p. 370).

9. Glossopharyngeal (*n. glossopharyngeus*), or ninth, nerve of motion, common sensation, and taste; *superficial origin,* from medulla oblongata, between olivary and restiform bodies; *deep origin,* from motor and sensory gray nuclei in floor of fourth ventricle; *course,* passes outward across flocculus; *exit,* jugular foramen, in separate sheath, in front of pneumogastric and spinal accessory, having two gangliform enlargements upon it—jugular, and the petrous or ganglion of Andersch; *distribution,* to mucous membrane of fauces, tonsil, pharynx and middle ear, muscles of the pharynx, and special sense of taste to the base and sides of the tongue. Its branches are:—

Tympanic (Jacobson's), (*n. tympanicus*),
Carotid branches (*n. caroticotympanicus superior et n. caroticotympanicus inferior*),
Muscular branches (*ramus stylopharyngeus*),
Pharyngeal branches (*rami pharyngei*),
Tonsillar branches (*rami tonsillares*),
Lingual branches (*rami linguales*).

10. Pneumogastric, vagus, or par vagum (*n. vagus*), tenth nerve, motor and sensory; *superficial origin,* from groove between olivary and restiform bodies by a dozen filaments; *deep origin,* from nuclei in floor of fourth ventricle; *course,* passes outward across the flocculus; *exit,* jugular foramen in a common sheath with the spinal accessory nerve; *distribution* (not definitely known), motor nerve to the organs of respiration and voice, and a motor and sensory nerve to heart, esophagus, pharynx and stomach. It branches are:—

Meningeal (*ramus meningeus*),
Auricular (Arnold's) (*ramus auricularis*),
Pharyngeal (*ramus pharyngeus*),
Superior laryngeal,
Recurrent laryngeal (*n. laryngeus inferior*),
Cervical cardiac (*rami cardiaci superiores*),
Thoracic cardiac (*rami cardiaci inferiores*),
Anterior pulmonary,
Posterior pulmonary,
Esophageal (*rami esophagei*),
Gastric (*rami gastrici*).

It also communicates with the left hepatic sympathetic plexus.

11. Spinal accessory (*n. accessorius*), eleventh, motor nerve; *superficial origin,* from lateral tract of medulla and spinal cord as low as sixth cervical nerve; *deep origin,* spinal portion from anterior horn of gray matter; accessory portion from gray nucleus in floor of fourth ventricle; *course,* the spinal portion enters the skull through the foramen magnum, and joins the accessory portion in the jugular foramen; *exit,* jugular foramen in sheath with the pneumogastric; *distribution,* to sternocleidomastoid and trapezius muscles, communicating with the cervical plexus and pharyngeal and laryngeal branches of pneumogastric.

12. Hypoglossal (*n. hypoglossus*), or twelfth nerve, motor nerve of tongue; *superficial origin,* from groove between olivary and pyramidal bodies by about a dozen filaments; *deep origin,* from gray nucleus at lowest part of floor of fourth ventricle; *exit,* anterior condyloid foramen; *distribution,* to the omohyoid (both bellies), sternohyoid, sternothyroid, thyrohyoid, and muscles of the tongue—styloglossus, hyoglossus, geniohyoid, genio-hyoglossus, communicating with the pneumogastric, sympathetic, first and second cervical and gustatory nerves. Its branches are:—

Descendens hypoglossi (*ramus descendens*),	Muscular,
Thyrohyoid (*ramus thyreohyoideus*),	Meningeal.

Membranes of the Cord.—The membranes of the spinal cord are three—the dura mater, arachnoid and pia mater.

Dura mater (*dura mater spinalis*) is a loose fibrous sheath, continuous with the dura of the brain, and from which it differs in not inclosing the venous sinuses, not dipping into the fissures of the cord, and not being adherent to the bony canal. From the latter it is separated by the venous plexuses (*plexus venosi vertebrales interni*) and some connective tissue.

It extends the whole length of the canal, from the foramen magnum (to which it is attached) to the top of the sacrum.

Arachnoid (*arachnoidea spinalis*) is a delicate serous sac, continuous above with the cerebral arachnoid, inclosing the pia mater, from which it is separated by an interval—the subarachnoidean space (*cavum subarachnoideale*). It is filled with the cerebrospinal fluid (*liquor cerebrospinalis*). The outer surface of the arachnoid is in contact with the dura, the space between them being called the subdural space (*cavum subdurale*).

Pia mater (*pia mater spinalis*) is a fibrous membrane, closely adhering to the cord and forming its neurilemma. Over the anterior median fissure it is strengthened by a fibrous band

—the *linea splendens*—and laterally has the *ligamentum denticulatum*. It terminates below the cord as the *filum terminale* —a slender filament.

THE SPINAL CORD.

The spinal cord (*medulla spinalis*) is the elongated portion of the cerebrospinal axis contained in the spinal canal. Its length is about sixteen to eighteen inches, extending from the medulla above to the lower border of the first lumbar vertebra below, where it terminates in the *cauda equina* by a slender prolongation of gray substance, called the *conus medullaris*.

It presents two enlargements, the upper or cervical (*intumescentia cervicalis*), extending from the third cervical to the second dorsal vertebra, and the lower or lumbar (*intumescentia lumbalis*), about the position of the second or third dorsal vertebra. It is divided into two lateral halves by the anterior (*fissura mediana anterior*) and posterior median fissures (*sulcus medianus posterior*), united in center by the commissure. The lateral portions are subdivided by anterolateral (*sulcus lateralis anterior*) and posterolateral fissures (*sulcus lateralis posterior*) into anterior lateral and posterior lateral columns, and posteriorly a narrow fissure separates the posterior median column from the posterior median fissure. The gray substance occupies the center of the cord, and is arranged into two crescentic masses connected together by the gray commissure (*commissura grisea*). The posterior horn (*columna grisea posterior*) forms the apex cornu (*apex columna grisea posterior*), from which arises the posterior root of the spinal nerves. The anterior horn (*columna grisea anterior*) is thick and short, and affords origin to the anterior root of the nerve. The gray commissure contains throughout its whole length a minute canal—the central canal, or ventricle of the cord (*canalis centralis*), continuous above with the fourth ventricle.

SPINAL NERVES.

The spinal nerves (*nervi spinales*) consist of thirty-one pairs, arranged in the following order: cervical, eight pairs; dorsal, twelve pairs; lumbar, five pairs; sacral, five pairs; coccygeal, one pair.

Each of the spinal nerves arises by two roots, an anterior (*radix anterior*) or motor and a posterior (*radix posterior*) or sensory. The fibers of the anterior root arise from the anterolateral columns, originating deeply in the gray matter of the

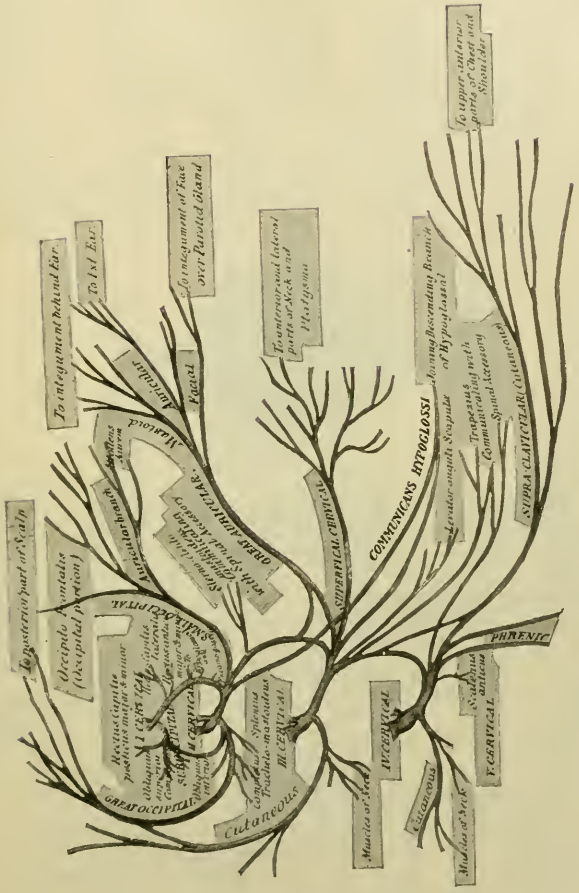
To posterior part of Scalp
Occipito Frontalis (Occipital portion)
To integument behind Ear
To 1st Ear
To integument of Face over Parotid Gland
To anterior and lateral parts of Neck and Platysma
To upper anterior parts of Chest and Shoulder
Auricular
Facial
Mastoid
Auricular branch
GREAT AURICULAR
with Spinal Accessory
SUPERFICIAL CERVICAL
COMMUNICANS HYPOGLOSSI
Arising Descending Branch of Hypoglossal
Levator anguli Scapulæ
Trapezius
Communicating with Spinal Accessory
SUPRA-CLAVICULAR (Cutaneous)
PHRENIC
Sedentus anticus
V. CERVICAL
IV. CERVICAL
Muscles of Neck
Cutaneous
Muscles of Neck
Splenius
Trachelo-mastoideus
III. CERVICAL
Cutaneous
GREAT OCCIPITAL
Rectus Capitis posticus major & minor
M. CERVICAL
SMALL OCCIPITAL

FIG. 119.

cord. The posterior roots arise at the posterolateral fissure, also originating deeply in the gray matter of the cord. The posterior roots have each a ganglion (*ganglia spinales*) developed upon it—except sometimes the first cervical. These roots unite and the nerve then subdivides into two branches, both having motor and sensory fibers. The posterior branches are small; they supply the skin and muscles of the back.

The anterior branches supply the neck, front and sides of the trunk, and the extremities.

Cervical Plexus (*plexus cervicalis*).—The cervical plexus is formed by the anterior divisions of the first to the fourth cervical nerves. It is covered by the sternomastoid muscle, and

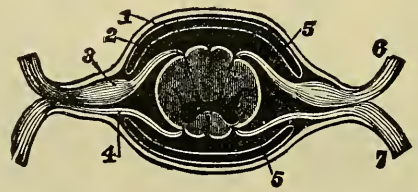

Fig. 120.

Section of spinal cord and membranes: 1, dura mater; 2, arachnoid membrane; 3, ganglion on posterior root; 4, anterior root of spinal nerve; 5, 5, subarachnoid space; 6, posterior branch of spinal nerve; 7, anterior branch of spinal nerve.

rests upon the scalenus medius and levator anguli scapulæ muscle. It gives off:—

Superficial.

Superficialis colli (*n. cutaneus colli*),
Auricularis magnus (*n. auricularis magnus*),
Occipitalis minor (*n. occipitalis minor*),
Supraclavicular (*nn. supraclaviculares*).

Deep.

Deep (Internal Series)
Communicating,
Muscular,
Phrenic (*n. phrenicus*),
Communicantes hypoglossi,
Deep (External Series)
Communicating,
Muscular.

The *phrenic nerve*, or *internal respiratory of Bell*, is derived from the third and fourth cervical nerves, with a branch from the fifth. It descends into the chest between the subclavian artery and vein, between the pericardium and the pleura, to the diaphragm, to which it is distributed (*rami*

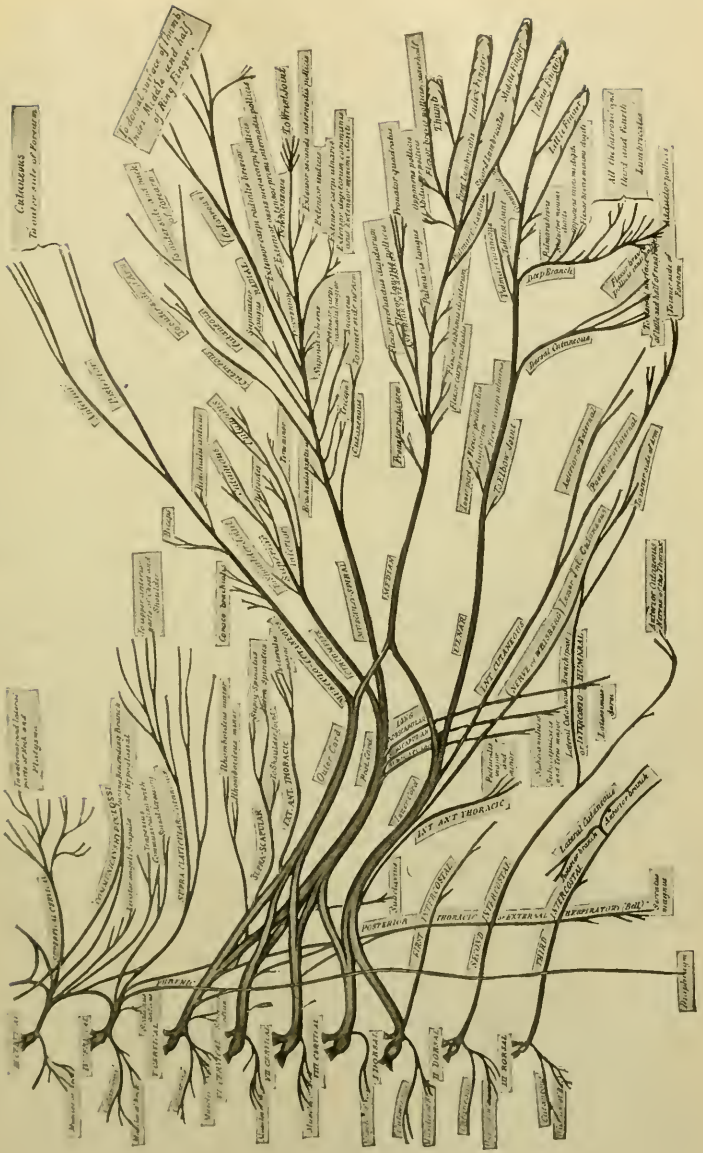

FIG. 121.

phrenicoabdominales). The course of the two nerves differs in the thorax (*vide* Mediastinum).

The brachial plexus (*plexus brachialis*) is formed by the anterior branches of the four lower cervical and the first upper dorsal nerves—the fifth, sixth and seventh forming one cord, and the eighth cervical and first dorsal another cord. Below the line of the clavicle (*pars infraclavicularis*) both these trunks divide, the adjacent cords of the two upper uniting to form the posterior (*fasciculus posterior*), and the remaining cords forming the outer (*fasciculus lateralis*) and inner (*fasciculus medius*) cords respectively, receiving their names from their relative position to the subclavian artery. Each of these cords again bifurcates, the adjacent divisions at the outer ending of the cords, uniting over the artery to form the median nerve, the other divisions forming the musculocutaneous, ulnar, circumflex and musculospiral, the two latter being the divisions of the posterior cord. Its branches are:—

Above the clavicle (*pars supraclavicularis*):—

Communicating, arises from the fifth cervical, and passes to the phrenic;

Muscular (*rami musculares*), supply the scaleni, rhomboidii, longus colli and subclavius;

Posterior thoracic (*n. thoracalis longus*), long *thoracic,* or *external respiratory of Bell,* arises by five roots from the fifth to seventh cervical nerves, which unite within the scalenus medius muscle and descend to supply the serratus magnus;

Suprascapular (*n. suprascapularis*), passes beneath the trapezius, through the suprascapular notch, to supply the shoulder-joint and supraspinatus muscle.

Below the clavicle (*pars subclavicularis*):—

The anterior thoracic nerves (*nn. thoracales anteriores*) are two in number: an external branch from the outer cord and an internal from the inner cord. The former supplies the pectoralis major and the latter the pectoralis minor, and sending branches to the pectoralis major.

The subscapular nerves (*nn. subscapulares*) are three in number. The upper subscapular supplies the subscapular muscle, the lower subscapular nerve supplies the teres major and subscapularis, the middle or long subscapular supplies the latissimus dorsi.

The circumflex nerve (*n. axillaris*) accompanies the posterior circumflex artery, passing through the space formed between the teres major, teres minor and long head of the triceps to supply the shoulder joint and skin over the shoulder and the

neighboring muscles. It gives off two branches, an upper and a lower branch.

The musculocutaneous nerve (*n. musculocutaneus*) pierces the coracobrachialis muscle and descends the arm to supply the brachialis anticus, biceps, coracobrachialis, and the skin of the forearm. At the outer border of the tendon of the biceps, above the elbow, it becomes superficial and divides into two branches —the anterior descending the radial side of the forearm to the wrist and supplying the skin of that part, the posterior branch descending the back part of the radial side of the forearm to the wrist. It supplies skin of lower third of forearm.

The internal cutaneous nerve (*n. cutaneus antibrachii medialis*) descends the inner side of the arm together with the basilic vein to about its middle, where it becomes cutaneous, supplying the skin of this region. It has an anterior and a posterior branch.

The lesser internal cutaneous nerve of Wrisberg (*n. cutaneus brachii medialis*) is derived from the inner cord, and receives filaments from the eighth cervical, first dorsal and the intercostohumeral nerve, and is distributed to the skin on the inner side of the arm.

The median nerve (*n. medianus*), formed by a root from the outer and inner cord of the brachial plexus, descends the arm, crossing the brachial artery from its outer to its inner side at the bend of the elbow. Its branches are:—

Muscular (*rami musculares*) branches, supply all the superficial anterior muscles except the flexor carpi ulnaris;

Anterior interosseous (*n. interosseus antibrachii volaris*), supplies all the deep anterior muscles except the inner half of the flexor profundus digitorum;

Palmar cutaneous (*ramus cutaneus palmaris n. mediani*), crosses above the annular ligament, divides into two branches to supply the ball of the thumb and the palmar surface of the hand;

Branches to the muscles of the thumb (*rami musculares*), supply the opponens, outer head of the small flexor, and the abductor;

Digital branches (*nn. digitales volares proprii*), supply both sides of the thumb, index and middle and the radial side of the ring finger.

The ulnar nerve (*n. ulnaris*) descends the inner side of the axillary artery to the middle of the arm, where it crosses the internal head of the triceps, and accompanies the inferior profunda artery to the elbow, where it passes between the heads of the flexor carpi ulnaris. Its branches are, in the forearm:—

Articular (elbow), supplies the elbow joint;

Muscular (*rami musculares*), to inner half of the deep flexors and flexor carpi ulnaris;

Cutaneous (*ramus cutaneus palmaris*), supplies the skin of the palm;

Dorsal cutaneous (*ramus dorsalis manus*), supplies both sides of the little finger and the ulnar side of the ring finger;

Articular (wrist), supply the wrist joint.

In the hand:—

Superficial palmar (*ramus superficialis n. ulnaris*), supplies the skin of both sides of the little and the ulnar side of the ring finger and palmaris brevis muscle;

Deep palmar (*ramus profundus n. ulnaris*), supplies the interossei, lumbricales, adductor pollici, and inner head of flexor brevis pollicis.

The musculospiral nerve (*n. radialis*), derived from the posterior cord of the brachial plexus, descends the arm in front of the teres major and latissimus dorsi muscle, accompanies the superior profunda artery through the musculospiral groove to the outer side of the elbow, between the supinator longus and the brachialis anticus, where it divides into the radial and posterior interosseous nerves. Its branches are:—

Muscular (*rami musculares n. radialis*), supply the supinator longus, external carpi radialis longior, triceps, anconeus and brachialis anticus;

Radial (*ramus superficialis n. radialis*), descends in the course of the radial artery to three inches above the wrist, where it becomes superficial, and supplies the adjoining sides of the thumb and index, index and middle, middle and ring fingers.

Cutaneous, supply the outer side of the arm, elbow, and radial side of forearm and wrist;

Posterior interosseous (*ramus profundus n. radialis*), passes through the supinator brevis muscle, and supplies, as it descends, all the posterior brachial and radial muscles, except those supplied by the muscular branches of the ulnar. It has a ganglion upon it.

Dorsal Nerves.—The posterior divisions of the dorsal nerves (*nn. thoracales*) subdivide into the external and internal branches to supply the muscles of the skin of the back. The anterior (*rami anteriores*) divisions of the dorsal nerves, intercostal nerves (*nn. intercostales*), twelve in number, supply the walls of the abdomen and thorax. They are divided into two sets—the upper six, distributed for the most part to the walls of the chest, and the lower six, to the walls of the chest and abdomen. The upper six dorsal nerves run between the two sets of the intercostal muscles, accompanied by the intercostal vessels, to supply the skin over the front of the chest and the mammæ. Their branches are:—

Lateral cutaneous (*rami cutanei laterales pectorales*), divide into two branches, anterior and posterior;

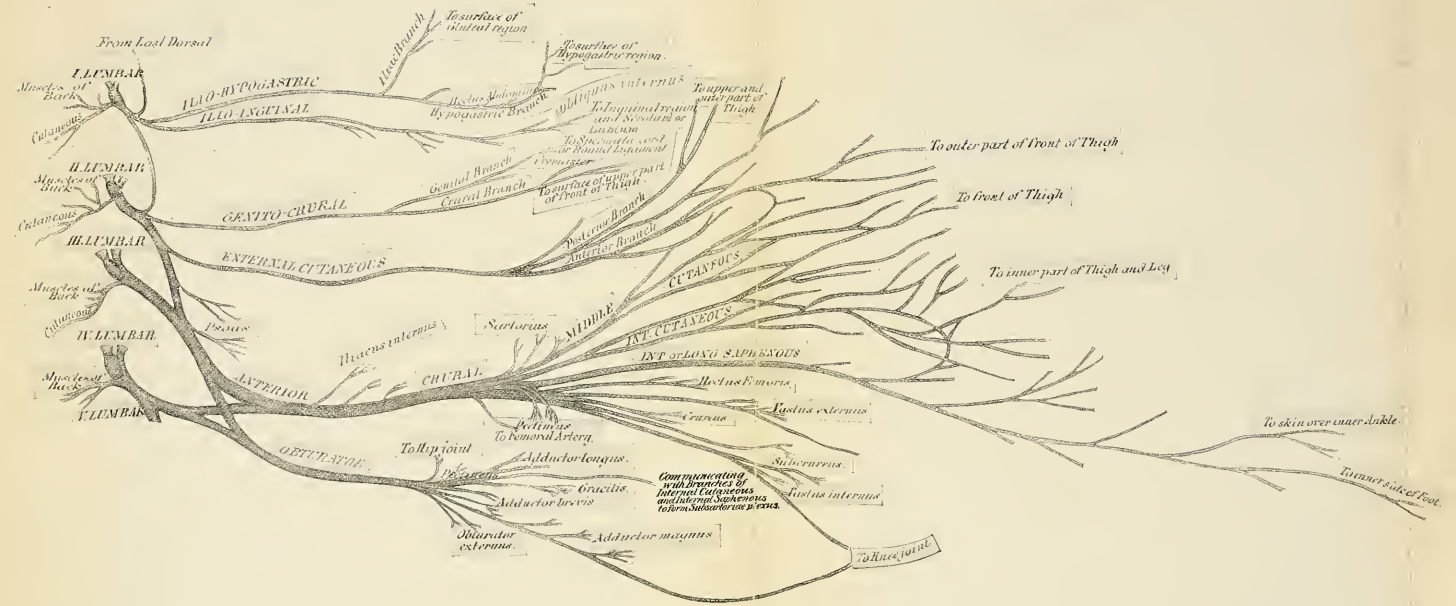

FIG. 112.

Lumbar plexus and branches.

Anterior branches (*rami anteriores*), to the skin of the chest and mammæ principally;

Posterior branches (*rami posteriores*), to the skin over the scapular and lower dorsal regions.

The first intercostal nerve (*n. intercostalis*) is not distributed to the skin, but crosses the axilla under the name of the intercostohumeral nerve; it joins the brachial plexus. The lower six dorsal nerves have received the name of *lower,* or *abdominal intercostal nerves,* from their distribution. The last dorsal one is of large size, and gives off a branch, the dorsilumbar nerve, to join the lumbar plexus.

Lumbar Nerves (*nn. lumbales*).—The posterior (*rami posteriores*) divisions of the lumbar nerves have the same distribution as the other spinal nerves. The anterior divisions of the upper four lumbar nerves unite to form the lumbar plexus. The fifth, with a branch from the fourth, joins the sacral nerves to form the lumbosacral cord.

The lumbar plexus (*plexus lumbalis*) is formed by the communicating loops from the anterior branches of the first four lumbar nerves and a branch from the last dorsal.

Its branches are:—

1. Iliohypogastric (*n. iliohypogastricus*), divides into two branches:—

(*a*) Iliac branch (*ramus cutaneus lateralis*), supplies the skin of the gluteal region and the oblique muscles of the abdomen;

(*b*) Hypogastric branch (*ramus cutaneus anterior*), supplies the skin of the hypogastric region and the oblique muscles.

2. Ilioinguinal (*n. ilioinguinalis*), supplies the skin of the inner and upper part of the thigh, the scrotum, and labium (in female).

3. Genitocrural (*n. genitofemoralis*), passes through the psoas muscle and divides into two branches:—

(*a*) Genital branch (*n. spermaticus externus*), follows the spermatic cord to supply the cremaster muscle; in female, supplies round ligament;

(*b*) Crural branch (*n. lumboinguinalis*), descends in the sheath of the femoral vessels to supply the skin in front of the thigh.

4. External cutaneous (*n. cutaneus femoris lateralis*) emerges below the anterior superior spine of ilium and divides into:—

(*a*) Anterior branch, to skin of outer and front aspect of thigh;

(*b*) Posterior branch, to skin of outer and back aspect of thigh.

5. Obturator (*n. obturatorius*), follows the brim and outer wall of pelvis to foramen (obturator), which it pierces to enter thigh.

(*a*) Anterior branch (*ramus anterior*), supplies the femoral artery;

(*b*) Posterior branch (*ramus posterior*), supplies the adductor muscles;

(*c*) Articular branch, supplies the synovial membrane of knee joint.

6. Accessory obturator (*n. obturatorius accessorius*), sends a branch to the hip joint and one to join the anterior branch of the obturator nerve.

7. Anterior crural (*n. femoralis*), the largest branch of the lumbar plexus, descends through the psoas muscle, beneath Poupart's ligament, into the thigh, where it divides into an anterior or cutaneous branch, and a posterior or muscular branch. It supplies all the muscles and the front of the thigh, excepting the tensor vaginæ femoris, gives branches to the knee, and supplies the skin of the inner side in front of the thigh, and to the leg and foot. Its branches from the anterior division are:—

(*a*) Middle cutaneous, to sartorius muscle and skin of front of thigh;

(*b*) Internal cutaneous, supplies the skin in the inner aspect of the leg;

(*c*) Long saphenous (*n. saphenus*), or internal saphenous, passes through Hunter's canal, accompanies the internal saphenous vein, to supply the skin of the inner side of the foot.

From the posterior division:—

(*a*) Muscular, to the muscles of the anterior and lateral aspects of the thigh;

(*b*) Auricular, to the knee joint.

The sacral nerves (*nn. sacrales*), five in number, divide into anterior and posterior nerves. The upper four sacral nerves, with the fifth lumbar, and a filament from the fourth, (the latter two forming the lumbosacral cord) together make the sacral plexus (*plexus sacralis*). It lies upon the anterior surface of the pyriformis muscle, and is separated from the viscera, the sciatic and pudic branches of the internal iliac artery by the pelvic fascia. Its branches are:—

1. Muscular (*rami musculares*), supply the obturators, gemelli, quadratus femoris and pyriformis.

2. Superior gluteal (*n. glutæus superior*), supplies the glutei muscles and tensor vaginæ femoris.

3. Pudic (*n. pudendus*), accompanies the internal pudic artery, passing out of the great sacrosciatic foramen, around the spine of the ischium to re-enter the lesser sacrosciatic foramen. It gives off:—

(*a*) Inferior hemorrhoidal (*n. hæmorrhoidalis inferior*), supplies the skin of the anus;

(*b*) Perineal (*n. perinei*), follows the course of the superficial perineal artery to supply the perineal structures generally;

(*c*) Dorsal nerve of the penis (*n. dorsalis penis*), follows the course of the corresponding artery to supply the skin of the glans, prepuce and penis generally.

4. Small sciatic (*n. cutaneus femoris posterior*), supplies the skin of the thigh, leg, perineum and the gluteus maximus muscle. Its branches are:—

(*a*) Inferior gluteal, to the gluteus maximus;

(*b*) Internal cutaneous branches (*nn. clunium inferiores laterales*), to the skin of the inner and upper part of the thigh, and one branch, the *inferior pudendal*, supplies the skin of the scrotum in the male and labium in the female;

(*c*) Ascending cutaneous branches supply the skin over the gluteus maximus.

5. The great sciatic nerve (*n. ischiadicus*), the largest in the body, passes out of the great sacrosciatic foramen, and descends between the tuberosity of the ischium and the great trochanter to the lower third of the thigh, where it divides into the internal and external popliteal. It gives off:—

(*a*) Muscular branches (*rami musculares*), to the muscles on the inner and posterior aspect of the thigh;

(*b*) Articular branches, to the hip joint.

The internal popliteal (*n. tibialis*), descends through the popliteal space to the arch of the soleus muscle, where it becomes the posterior tibial. It gives off:—

(*a*) Articular branches (*rami articulares*), to knee joint;

(*b*) Muscular branches (*rami musculares*), to the muscles on the posterior aspect of the leg;

(*c*) External, or short saphenous nerve (*n. suralis*), passes between the two heads of the gastrocnemius muscle, and descends the leg, receiving the communicans peronei branch from the external popliteal, around the outer malleolus to supply the skin of the outer side of the foot.

The *posterior tibial* nerve descends the leg in company with the posterior tibial vessels to below the inner ankle, where it divides into the external and internal plantar nerves. It gives off:—

1. Muscular branches (*rami musculares*), to the deep muscles of the calf;
2. Internal cancaneal (*rami calcanei mediales*), supplies the skin on the inner side of the sole and heel;
3. Articular branch, to ankle joint.

The internal plantar (*n. plantaris medialis*) accompanies the corresponding artery to the inner side of the foot and gives off:—

1. Cutaneous branches;
2. Muscular branches;
3. Articular branches;
4. Four digital branches, supplying both sides of the first three toes and the inner side of the fourth.

The external plantar (*n. plantaris lateralis*) supplies by a superficial branch the outer side of the fourth and both sides of the fifth toes, and gives off a deep, or muscular, branch.

The external popliteal or peroneal nerve (*n. peronæus communis*) descends to the inner side of the biceps tendon, pierces the peroneus longus about one inch below the head, and divides into the anterior tibial and musculocutaneous. It gives off:—

1. Articular branches (*rami articulares*), to knee joint;
2. Cutaneous branches (*n. cutaneus surœ lateralis*), one of which is the communicans peronei (*ramus anastomoticus peronœus* or *communicans fibularis*), which joins the short saphenous.

The anterior tibial (*n. peronœus profundus*) accompanies the corresponding artery on its outer side to the ankle, where, after giving off an articular branch, it divides into:—

1. External or tarsal branch, to the tarsal and metatarsal joints, and
2. Internal, to the dorsal adjoining sides of the great and second toes.

The musculocutaneous (*n. peronœus superficialis*) gives off:—

1. Internal branches (*n. cutaneus dorsalis medialis*), supply skin of inner side of foot and ankle, and inner side of great toe;
2. External branch (*n. cutaneus dorsalis intermedius*), to the dorsum of the adjacent sides of the second, third, fourth and fifth toes.



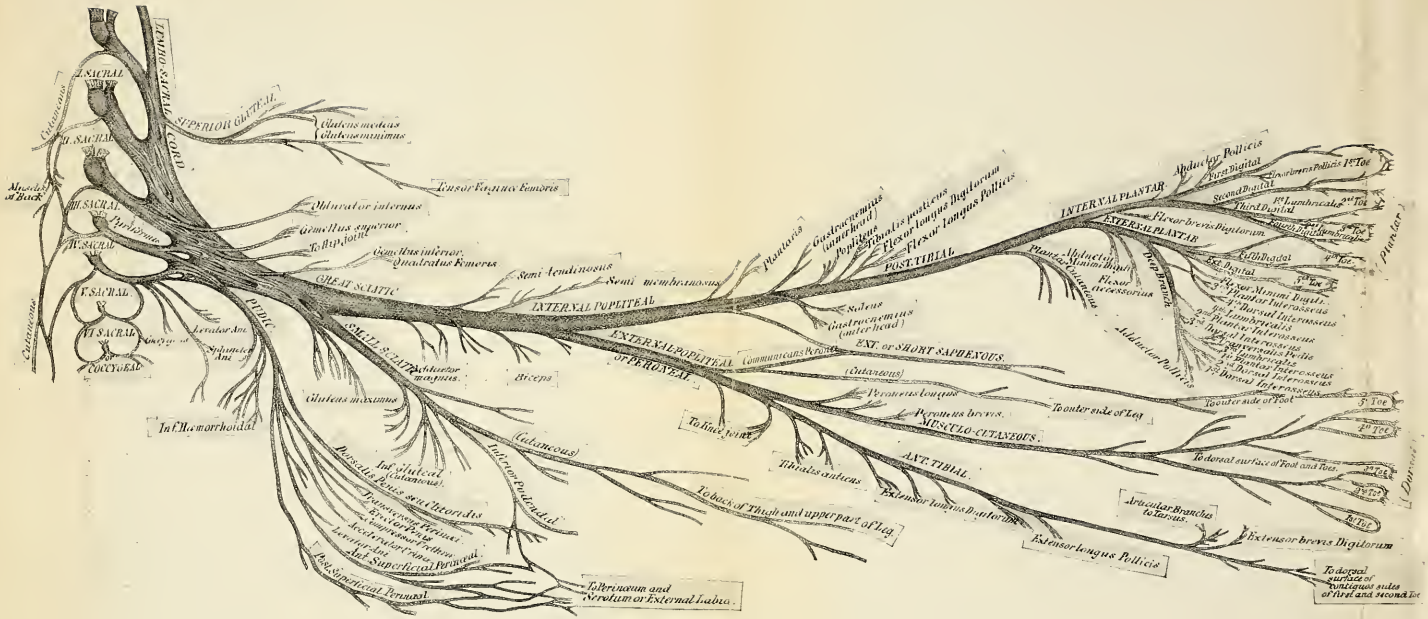

FIG. 123.

Sacral plexus and branches.

Table of the Spinal Nerves.

- **First cervical nerve,**
  - Posterior division (suboccipital), → Complexus, recti and obliqui muscles.
  - Anterior division (occipital), → Unites with the second cervical nerve, and supplies the anterior recti and rectus lateralis muscles.
- **Second cervical nerve,**
  - Posterior division,
    - External branch, → Splenius, complexus, trachelomastoid muscles.
    - Internal branch, (great occipital), → With branch from third cervical, supplies the skin of the scalp.
  - Anterior division,
    - Small occipital,
    - Branch to superficial cervical,
    - Branch to great auricular,
    - Branch to communicans noni.
- **Third cervical nerve,**
  - Posterior divison,
    - External and internal branches, → Splenius, semispinalis, complexus, trachelomastoid muscles.
  - Anterior divison, → Branches to form the great auricular, superficial cervical, and communicantes minor.
- **Fourth to eighth cervical nerves,**
  - Posterior divisions,
    - Internal branches, → Muscles of the side of the neck.
    - External branches, → Skin and larger muscles of the neck.
  - Anterior division of fourth,
    - Branch to phrenic,
    - Branches to the trapezius, scalenus medius, levator anguli scapulæ muscles.
  - Anterior divisions, fifth to eighth, → Unite with the first dorsal nerve to form the brachial plexus.

- **Cervical plexus,**[1]
  - Superficial branches,
    - Ascending,
      - Superficialis colli,
      - Auricularis magnus,
      - Occipitalis minor.
    - Descending,
      - Supraclavicular.

[1] Formed by the anterior divisions of the first to the fourth cervical nerves.

TABLE OF THE SPINAL NERVES.—*(Continued.)*

- Cervical plexus (*continued*)
  - Deep branches
    - Internal set
      - Communicating
      - Muscular
        - Recti muscles.
      - Phrenic
      - Communicans noni.
    - External set
      - Muscular
      - Communicating.
- Brachial plexus,[1]
  - Above the clavicle
    - Communicating → To phrenic.
    - Muscular → Scaleni, rhomboidei, longus colli, subclavius.
    - Posterior thoracic → Serratus magnus. (External respiratory nerve of Bell.)
    - Suprascapular → Shoulder joint and supraspinatus muscle.
  - Below the clavicle
    - Anterior thoracic
      - External branch → Pectoralis major.
      - Internal branch → Pectoralis minor, Pectoralis major.
    - Three subscapular
      - Upper → Subscapular muscle.
      - Lower → Teres major.
      - Middle → Latissimus dorsi.
    - Circumflex
      - Upper, Lower → Shoulder joint, and muscles and skin about it.
    - Musculocutaneous
      - Anterior branch → Integument of palmar surface of the wrist.
      - Posterior branch → Integument of dorsal surface of the wrist.

[1] Formed by the anterior branches of four lower cervical and first dorsal nerves.

TABLE OF THE SPINAL NERVES.—*(Continued.)*

- Brachial plexus, below the clavicle, *contin'd*,
  - Internal cutaneous, Anterior and posterior branches — Integument of inner side of the arm.
  - Lesser internal cutaneous (Wrisberg's) — Integument of the inner side of the arm.
  - Median,
    - Muscular — Superficial anterior muscles, except flexor carpi ulnaris.
    - Anterior interosseous — Deep anterior muscles, except the inner half of flexor profundus digitorum.
    - Palmar cutaneous — Ball of thumb and palmar surface of the hand.
    - Branch to the muscles of the thumb — Opponens, outer head of small flexor and abductor.
    - Digital branches — Both sides of thumb, index and middle fingers and radial side of ring finger.
  - Ulnar, in forearm,
    - Articular — (Elbow).
    - Muscular — Inner half of deep flexors and flexor carpi ulnaris.
    - Cutaneous — Skin of the palm.
    - Dorsal cutaneous — Both sides of little finger and ulnar side of ring finger.
    - Articular — (Wrist).
  - Ulnar, in hand,
    - Superficial palmar — Skin of both sides of little finger, ulnar side of ring finger and palmaris brevis muscle.
    - Deep palmar — Interossei lumbricales, adductor pollicis, inner head of flexor brevis pollicis.

TABLE OF THE SPINAL NERVES.—*(Continued.)*

- **Brachial plexus, below the clavicle, *cont'd*,**
  - **Musculo-spiral,**
    - Muscular branches, → Supinator longus, extensor carpi radialis longior, triceps, anconeus, brachialis anticus.
    - Radial, → Supplies adjoining sides of thumb and index finger, index and middle, middle and ring fingers.
    - Cutaneous, → Inner side of arm, elbow, radial side of forearm and wrist.
    - Posterior interosseous, → Posterior brachial and radial muscles, except those supplied by ulnar (muscular branches).
- **Dorsal nerves,**
  - Posterior divisions,
    - External branches,
    - Internal branches,

    → Muscles and skin of the back.
  - Anterior divisons,[1]
    - Upper six (thoracic intercostals),
      - First intercostal crosses the axilla to join the lesser internal cutaneous (Wrisberg's).
      - Lateral cutaneous,
        - Anterior, → Skin of chest and mammæ.
        - Posterior, → Skin over scapula and lower dorsal region.
    - Lower six (thoracico-abdominal intercostals), → The last dorsal gives off the dorsilumbar to the quadratus lumborum muscle.
- **Lumbar nerves,**
  - Posterior divisions,
    - External branches,
    - Internal branches,

    → Muscles of the skin of the back.
  - Anterior divisions, → The four upper unite to form the lumbar plexus. The fifth, with a branch from the fourth, joins the sacral nerves to form the lumbosacral cord.

[1] To the walls of chest and abdomen.

TABLE OF THE SPINAL NERVES.—*(Continued.)*

- Lumbar plexus,
  - Ilio-hypogastric,
    - Iliac, — Skin of gluteal region, oblique muscles of abdomen.
    - Hypogastric, — Skin of hypogastric region and oblique muscles.
  - Ilio-inguinal, — Skin of inner and upper part of thigh, scrotum, labium (in female).
  - Genito-crural,
    - Genital, — Cremaster muscle, round ligament (in female).
    - Crural, — Skin of front of thigh.
  - External cutaneous,
    - Anterior, — Skin of outer front aspect of thigh.
    - Posterior, — Skin of outer back aspect of thigh.
  - Obturator,
    - Anterior, — Femoral artery.
    - Posterior, — Adductor muscles.
    - Articular, — Synovial membrane of knee-joint.
  - Accessory obturator, — Branch to hip-joint, branch to anterior branch of obturator nerve.
  - Anterior crural,
    - Anterior division,
      - Middle cutaneous, — Sartorius muscle, skin of thigh (ant.).
      - Internal cutaneous, — Skin of inner aspect of leg.
      - Long saphenous, — Skin of inner side of foot.
    - Posterior division,
      - Muscular, — Muscles of the anterior and lateral aspect of thigh.
      - Articular, — Knee joint.

TABLE OF THE SPINAL NERVES.—*(Continued.)*

- **Sacral nerves,**
  - Posterior divisions,
    - External and internal branches, → Muscles and skin of the back.
  - Anterior divisions, → The four upper joining with the lumbosacral cord form the sacral plexus.

- **Sacral plexus,**
  - Muscular, → Obturators, gemelli, quadratus femoris and pyriformis.
  - Superior gluteal, → Glutei muscles and tensor vaginæ femoris.
  - Pudic,
    - Inferior hemorrhoidal, → Skin of the anus.
    - Perineal, → Perineal structures.
    - Dorsal nerve of the penis, → Skin of the penis.
  - Articular → To hip joint.
  - Small sciatic,
    - Inferior gluteal, → Gluteus maximus.
    - Internal cutaneous,
      - Branch to skin of inner and upper part of thigh.
      - Inferior pudendal, skin of scrotum, labium in female.
    - Ascending cutaneous, → Skin over gluteus maximus.
  - Great sciatic.
    - Articular, → Hip joint.
    - Muscular, → Muscles of inner and posterior part of thigh.
    - Bifurcation, → External, Internal, → Popliteal.

- **Internal popliteal,**
  - Articular branches, → To knee joint.
  - Muscular branches, → To muscles of the posterior aspect of the leg.

TABLE OF THE SPINAL NERVES.—*(Continued.)*

- Internal popliteal (*continued*),
  - Communicans poplitei, → Skin of outer side of the foot.
  - Posterior tibial (continuation),
    - Muscular, → Deep muscles of the calf.
    - Plantar cutaneous, → Skin of inner side of sole and heel.
    - Articular, → To ankle joint.
    - Bifurcation,
      - Internal plantar,
      - External plantar.
    - Internal plantar,
      - Cutaneous,
      - Muscular,
      - Articular,
      - Four digital.
    - External plantar, → Supplies the outer side of the fourth and both sides of the fifth toes. Muscular branch.

- External popliteal (peroneal),
  - Articular, → To knee joint.
  - Two cutaneous, → Communicans peronei.
  - Anterior tibial,
    - External or tarsal branch, → Tarsal and metatarsal joints.
    - Internal branch, → Inner and dorsal, adjoining sides of great and second toes.
  - Musculo-cutaneous,
    - Internal branches, → To skin of inner side of foot and ankle.
    - External branch, → To dorsum of adjacent sides of third, fourth and fifth toes.

THE SYMPATHETIC NERVOUS SYSTEM.

The sympathetic system (*sympatheticus*), like the cerebrospinal axis, is double, consisting of a gangliated cord (*truncus sympatheticus*) on each side, extending the entire length of the vertebral column, and numerous nerve fibers, both *communicating,* by which it anastomoses with the cerebrospinal axis, and *distributory,* by which the blood vessels and viscera are supplied.

Branches of the gangliated cords ascend through the carotid canal to communicate with the ganglia of the fifth cranial nerve, and also with each other through the *ganglion of Ribes,* situated upon the anterior communicating artery. They also communicate below in the ganglion impar (*ganglion coccygeum impar*), located in front of the coccyx.

The ganglia of each cord correspond very nearly in position and number to the vertebræ, except in the cervical region, where there are but three: cervical three, dorsal twelve, lumbar four, sacral five.

From the gangliated cords three important plexuses are given off—the cardiac, solar, and hypogastric—situated in the thoracic, abdominal and pelvic cavities, respectively.

Cranial Ganglia—Ganglia Connected with the Fifth Cranial Nerve.—Besides the Gasserian ganglion upon the root there are four—ophthalmic, sphenopalatine, otic and submaxillary—each of which has three branches of communication or *roots*—motor, sensory and sympathetic—besides several branches of distribution.

The ophthalmic, or ciliary ganglion (*ganglion ciliare*), is situated in the orbit between the external rectus muscle and optic nerve upon the first division of the fifth cranial nerve.

Its sensory root (*radix longa ganglii ciliaris*) is from the nasal branch of ophthalmic, motor root (*radix brevis ganglii ciliaris*) from the motor oculi or third, and sympathetic from the cavernous plexus.

Its branches are the short ciliary nerves (*vide* Eye).

Sphenopalatine, or Meckel's (*ganglion sphenopalatinum*), the largest, is situated in the sphenomaxillary fossa upon the superior maxillary, or second division of the fifth.

Its sensory root is derived from the superior maxillary, its motor root, from the facial, through means of the Vidian, and its sympathetic from the carotid plexus. Its branches are:—

1. Ascending (*rami orbitales*);

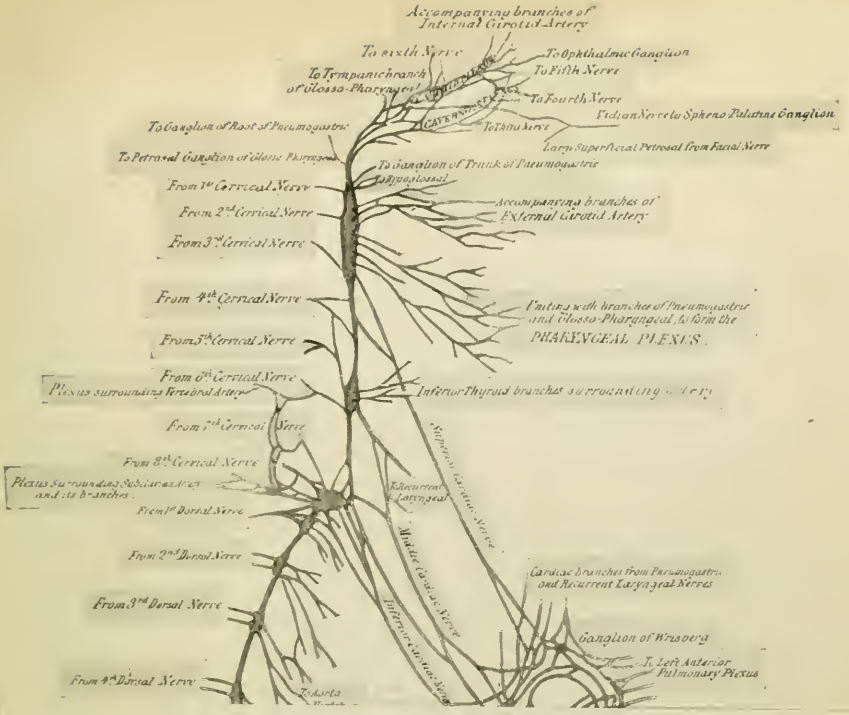
Accompanying branches of Internal Carotid Artery
To sixth Nerve
To Ophthalmic Ganglion
To Tympanic branch of Glosso-Pharyngeal
To Fifth Nerve
To Fourth Nerve
Vidian Nerve to Spheno Palatine Ganglion
To Ganglion of Root of Pneumogastric
To Third Nerve
Large Superficial Petrosal from Facial Nerve
To Petrosal Ganglion of Glosso Pharyngeal
To Ganglion of Trunk of Pneumogastric
From 1st Cervical Nerve
To Hypoglossal
From 2nd Cervical Nerve
Accompanying branches of External Carotid Artery
From 3rd Cervical Nerve
From 4th Cervical Nerve
Uniting with branches of Pneumogastric and Glosso-Pharyngeal, to form the PHARYNGEAL PLEXUS.
From 5th Cervical Nerve
From 6th Cervical Nerve
Plexus surrounding Vertebral Artery
Inferior Thyroid branches surrounding Artery
From 7th Cervical Nerve
Superior Cardiac Nerve
From 8th Cervical Nerve
Plexus Surrounding Subclavian Artery and its branches.
Recurrent Laryngeal
From 1st Dorsal Nerve
Middle Cardiac Nerve
From 2nd Dorsal Nerve
Cardiac branches from Pneumogastric and Recurrent Laryngeal Nerves
From 3rd Dorsal Nerve
Inferior Cardiac Nerve
Ganglion of Wrisberg
To Left Anterior Pulmonary Plexus
From 4th Dorsal Nerve
To Aorta

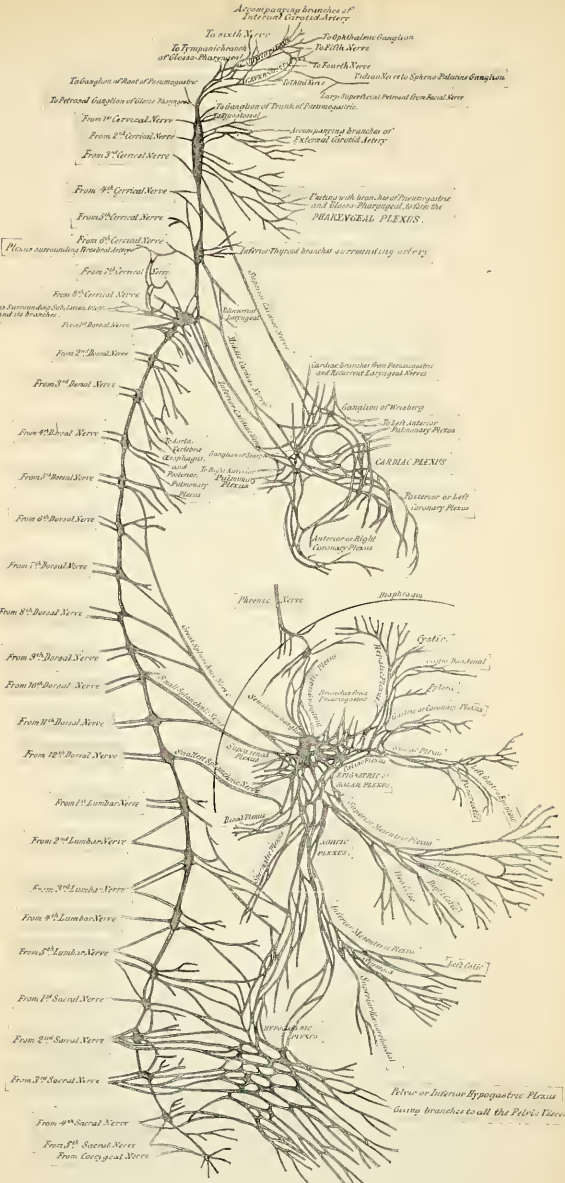

FIG. 124.
The sympathetic system.

2. Descending, or palatine (*nn. palatini*),
   - Anterior, or large palatine (*n. palatinus anterior*),
   - Middle, or external palatine (*n. palatinus medius*),
   - Posterior, or small palatine (*n. palatinus posterior*),

3. Internal,
   - Posterior superior nasal (*rami nasales posteriores superiores*),
   - Nasopalatine (*n. nasopalatinus*),

4. Posterior,
   - Vidian (*n. canalis pterygoidea*),
   - Large superficial petrosal (*n. petrosus superficialis major*),
   - Deep petrosal (*n. petrosus profundus*),
   - Pharyngeal branch.

The Vidian nerve (*n. canalis pterygoidea*) passes from the back part of Meckel's ganglion through the foramen lacerum medium, where it divides into the large superficial and deep petrosal nerves. It gives off the upper posterior nasal branches to the mucous membrane of septum, orifice of Eustachian tube, and roof of the nose. Or, more correctly, the Vidian is formed by the union of the great petrosal (large superficial petrosal) from the facial and the large deep petrosal from the carotid sympathetic, runs forward through the Vidian canal, and joins the sphenopalatine ganglion (Meckel's). In this description, the nerves given off to the nasal mucous membrane must be considered branches from the ganglion inclosed in the same sheath.

The large superficial petrosal branch (*n. petrosus superficialis major*) enters the cranium through the foramen lacerum medium, passes beneath the dura mater and Gasserian ganglion, enters the hiatus Fallopii, receives a branch from the tympanic branch of the glossopharyngeal (Jacobson's), and through the aqueductus Fallopii to terminate in the geniculate ganglion of the facial nerve.

The large deep petrosal branch (*n. petrosus profundus*) crosses the foramen lacerum medium to the carotid canal, where it joins the carotid plexus of the sympathetic.

The *pharyngeal* or *pterygopalatine* nerve descends from the back part of the ganglion through the pterygopalatine canal, to supply the upper part of the pharynx.

Besides the Vidian and its branches there are two other petrosal nerves (*vide* Facial Nerve), the small and external petrosal.

The *small petrosal* connects the geniculate ganglion of the facial, within the aqueductus Fallopii, with the otic ganglion.

The *external petrosal* connects the geniculate ganglion of the facial, within the same canal, with the sympathetic plexus of the middle meningeal plexus.

The otic or Arnold's ganglion (*ganglion oticum*) is placed below the foramen ovale upon the inferior maxillary nerve, or third division of the fifth.

Its sensory root is derived from the auriculotemporal branch of the inferior maxillary; the motor root, from the internal pterygoid branch of the same; the sympathetic root, from the plexus on the middle meningeal artery. Branches are distributed to the tensor palati (*n. tensoris veli palatini*) and tensor tympani (*n. tensoris tympani*) muscles.

The submaxillary ganglion (*ganglion submaxillare*) is placed above the deep portion of the submaxillary gland.

Its sensory root is derived from lingual branch of inferior maxillary; its motor root, from the facial nerve through a branch of the chorda tympani; and its sympathetic, from the plexus of the facial artery.

Besides these ganglia, situated upon branches of the trifacial nerve, the following are found within the cavity of the cranium:—

Ganglion of Ribes, on the anterior communicating artery;
Ganglion of Bidder, on the middle meningeal artery;
Ganglion of Laumonier, on the internal carotid artery;
Ganglion of Cloquet, on the nasopalatine nerve in the incisor fossa;
Ganglion of Bochdaleck, near the sphenopalatine ganglion.

Cervical Ganglia.—The cervical ganglia consist of three,—superior, middle, inferior,—of which the superior is the largest and the middle the smallest. These are connected above with the cranial ganglia, below with the thoracic ganglia, and communicate with each other.

The superior cervical ganglion (*n. caroticus internus*) lies opposite the second or third cervical vertebra, behind the internal carotid artery. It is connected with the middle ganglion, the upper four cervical, and tenth and twelfth cranial nerves, distributes branches to the carotid (internal), cavernous (*plexus cavernosus*) and pharyngeal plexuses, and gives off the superior cardiac nerve to the cardiac plexus (*plexus caroticus internus*).

The middle cervical ganglion (*ganglion cervical medium*) lies upon inferior thyroid artery, opposite fifth cervical vertebra. It is connected with the upper and lower ganglia and spinal

nerves, and gives off the middle cardiac nerve (*n. cardiacus medius*) to cardiac plexus.

The inferior cervical ganglion (*ganglion cervicale inferius*) lies internal to the superior intercostal artery, below the last cervical vertebra. It is connected to the middle ganglion, first thoracic, lower cervical nerves, forms the vertebral plexus, and gives off the inferior cardiac nerve (*n. cardiacus inferior*) to cardiac plexus.

Thoracic ganglia (*pars thoracalis*) lie upon the heads of the ribs on each side of the vertebral column. They are connected with the inferior cervical ganglion above, the lumbar ganglion below, the dorsal spinal nerves behind, and give off internal branches divided into two sets of six each—upper and lower.

Internal branches from upper set are distributed to the pulmonary and aortic plexuses (*plexus aorticus thoracalis*), and internal branches from lower set unite to form the three splanchnic nerves—great splanchnic (*n. splanchnicus major*), lesser splanchnic (*n. splanchnicus minor*), renal splanchnic,—distributed respectively to the semilunar ganglion, renal and suprarenal plexuses, and to renal and celiac plexuses.

The lumbar ganglia (*pars lumbalis*) lie along inner margin of the psoas muscle. They communicate above and below with the other ganglia and with the lumbar spinal nerves, and give off internal branches which form the hypogastric plexus.

The sacral ganglia (*pars sacralis*) are situated internal to the anterior sacral foramina. They unite below in front of the coccyx in the coccygeal ganglion, or *ganglion impar*. They communicate with the sacral nerves, join the pelvic plexus, and send branches on the middle sacral artery.

Cardiac Plexus (*plexus cardiacus*).—The cardiac plexus, formed from the superior, middle and inferior cardiac nerves from the cervical ganglia, and the cardiac branches from the pneumogastric and recurrent laryngeal, consists of two portions —the superficial and deep.

The *superficial cardiac plexus,* situated beneath the arch of the aorta, is formed by the left superior cardiac nerve and the left inferior cervical cardiac nerve, and contains the cardiac ganglion of Wrisberg (*ganglion cardiacum* [Wrisbergi]). It forms part of the anterior coronary plexus, and sends branches to the left anterior pulmonary plexus.

The *deep cardiac plexus* lies between the arch of the aorta and trachea, and receives all the cardic nerves except the two mentioned above. It forms part of the anterior coronary

(*plexus coronarius cordis anterior*) and posterior coronary (*plexus coronarius cordis posterior*) plexuses.

The solar plexus (*plexus cœliacum*), or "abdominal brain," consists of ganglia and a network of nerve branches, formed chiefly from the branches of the two great splanchnic nerves and branches from the right pneumogastric. It is situated between the aorta and the crura of the diaphragm and the stomach, and surrounds the superior mesenteric artery and celiac axis.

Its ganglia are two crescentic ganglionic masses—the *semilunar* ganglia (*ganglia cœliaca*)—the largest in the body—situated in front of the crura of the diaphragm. They are composed of small ganglia aggregated together. From the solar plexus and semilunar ganglion are derived numerous branches which are distributed as plexuses over all the abdominal arteries, as follows:—

Cœliac (*plexus cœliacus*),
Gastric (*plexus gastricus superior*),
Hepatic (*plexus hepaticus*),
Splenic (*plexus lienalis*),
Phrenic (*plexus phrenicus*),
Suprarenal (*plexus suprarenalis*),
Renal (*plexus renalis*),
Spermatic (*plexus spermaticus*),
Aortic (*plexus aorticus abdominalis*),
Superior mesenteric (*plexus mesentericus superior*),
Inferior mesenteric (*plexus mesentericus inferior*),
Ovarian (*plexus arteriæ ovaricæ*),

The hypogastric plexus (*plexus hypogastricum*) is situated below the bifurcation of the aorta, in front of the sacrum, and is formed by branches from the lumbar ganglia and aortic plexus. It divides into two parts which, with branches from the sacral ganglia and nerves, become the pelvic plexuses.

The inferior hypogastric or pelvic plexus on each side gives off the following branches:—

Vaginal plexus,
Inferior hemorrhoidal (*plexus hæmorrhoidalis inferior*),
Prostatic plexus (*plexus prostaticus*), { Small cavernous nerves (*n. cavernosus penis minor*), Large cavernous nerves (*n. cavernosus major*), } to penis,
Vesical plexus (*plexus vesicalis*),
Uterine plexus.

ORGANS OF SPECIAL SENSE.

THE NOSE.

THE nose (*organon olfactus*), the special organ of smell, consists of two parts.—the external prominence, or nose proper, and the internal cavities, or nasal fossæ.

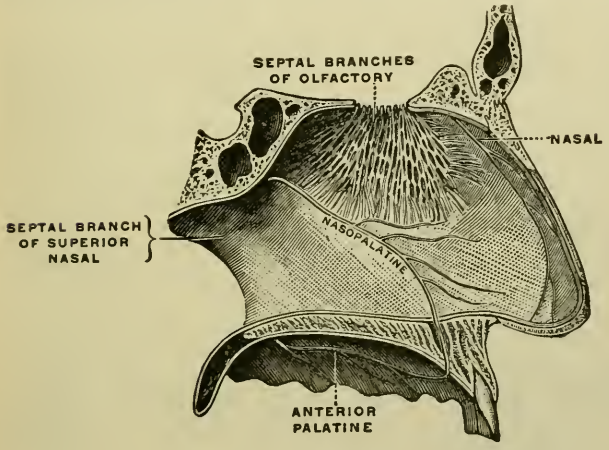

FIG. 125.

The olfactory nerves and nerves of common sensation to the nose. (*Eckley.*)

The *nose proper* is made up of a cartilago-osseous framework covered with muscles (*vide* Muscles) and skin, and lined with mucous membrane. The osseous portion is formed by the margins of the anterior meatus (*vide* Osteology).

The cartilaginous portion consists of an upper (*cartilago nasi lateralis*) and lower lateral cartilage (*cartilago alaris major*) on either side, and the nasal septum dividing the nasal cavity into two nasal fossæ (*cavum nasi*).

Arteries are from nasal branch of ophthalmic and infra-orbital, nasal artery from superior coronary, and branches of the lateralis nasi.

Veins empty into the ophthalmic and facial veins.

Nerves from infratrochlear, infraorbital and facial.

The nasal fossæ (*cavum nasi*) are the two bony cavities already described (*vide* page 45). They are lined throughout with mucous membrane (*membrana mucosa nasi*) called *Schneiderian membrane,* which is continuous with the antrum of Highmore, frontal, ethmoidal and sphenoidal sinuses, with the conjunctiva through the lachrymonasal duct, with the pharynx through the posterior nares (*choanæ*), and with cavity of the tympanum through the Eustachian tube. Its epithelium is columnar, ciliated in the lower part and in the sinuses, and is columnar, but not ciliated, in the membrane to which the olfactory nerve is distributed.

Arteries are anterior and posterior ethmoidal from the ophthalmic to the roof, frontal and ethmoidal sinuses, sphenopalatine from the internal maxillary to the mucous membrane of the spongy bones, septum, and meatuses, and alveolar from the internal maxillary to the antrum.

Veins empty into facial, ophthalmic, and beginning of great longitudinal sinus.

Nerves are:—

Olfactory, or first cranial, the special nerve of smell, is distributed over the upper third of the septum and superior turbinated bones.

Anterior dental branch of superior maxillary to the inferior turbinated bone and inferior meatus.

Nasal branch of ophthalmic, to the outer walls and septum. Besides these, the sphenopalatine ganglion, the Vidian, the superior nasal branch, nasopalatine and anterior palatine also send branches to the parts.

THE EYE.

The organs of sight comprise the eyeballs (*bulbus oculi*) and their appendages and the optic nerves.

The eye is a spherical organ, situated in the anterior part of the skull, protected in front by several appendages, acted upon by muscles, and supplied by blood vessels and nerves.

Within the orbit it rests upon a bed of fat, from which it is separated by a membranous sac—the capsule of Tenon (*fascia bulbi* [Tenoni]).

It presents the following:—

Diameters.—Anteroposterior, in the adult, .950 inch; transverse, .925; vertical, .915; oblique, .943.

FIG. 126.

Nasal meatuses and accessory cavities. 1, right termination of the left frontal sinus; 2, right frontal sinus; 3, probe extending from the right frontal sinus through the infundibulum into the right nasal fossa; 4, ethmoid cells; 5, large opening into the maxillary sinus; 6, anterior antrum of the sphenoid bone; 7, posterior sphenoid antrum; 8, middle nasal meatus; 9, inferior meatus; 10, inferior turbinated bone; 11, probe extending through the nasal duct. (*Bishop.*)

Anterior and *posterior poles* are the geometric centers of the cornea and fundus respectively.

Optic axis (*axis optica*) is a straight line passing through the cornea and posterior pole of the eye.

Line of vision, or visual axis (*linea visus*), is an imaginary line which connects the point of fixation with the fovea cen-

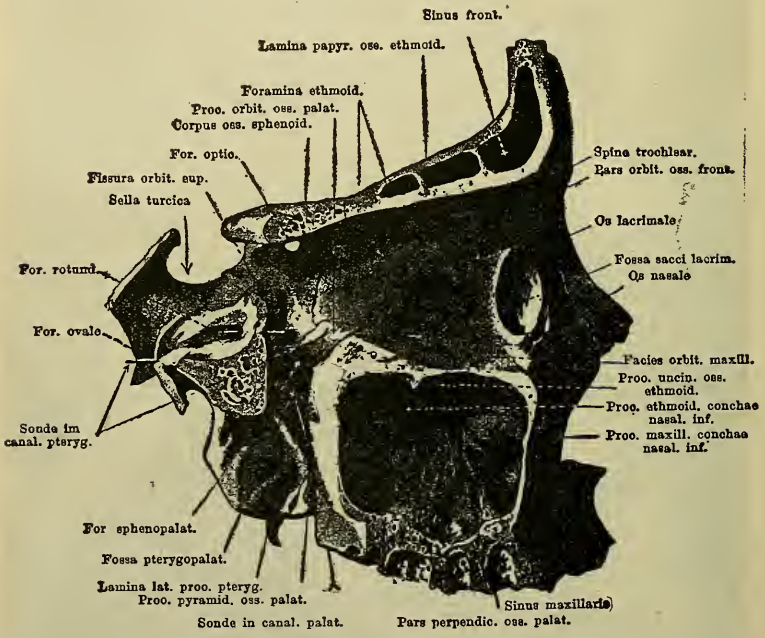

FIG. 127.

Inner wall of orbit and adjacent parts. (*His.*) (*Ball.*)

tralis, through the nodal point, usually to the outer side of the center of the pupil. It forms with the optic axis as it cuts the cornea, the *visual angle*—an angle of from 3° to 7°.

Nodal point is an imaginary point—the center of curvature of the refracting media—where all the luminous rays pass without deviation.

Equatorial plane, an imaginary plane passing through the center of the eyeball at right angles to the optic axis, dividing the globe into two hemispheres—the anterior and posterior.

Equator is the line upon the surface of the globe where the equatorial plane cuts it.

Meridional planes are imaginary anteroposterior planes coinciding with the axis.

Meridians are the lines upon the surface where these meridional planes cut it.

The capsule of Tenon, tunica vaginalis oculi (*fascia oculi* [Tenoni]), is a fascia between the eyeball and the walls of the orbit, isolating the eyeball and allowing free movement.

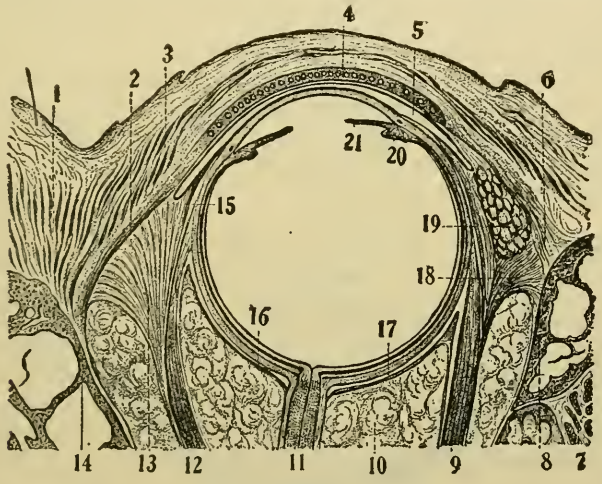

Fig. 128.

Horizontal section of right orbit. 1, Horner's muscle; 2, septum orbitale; 3, fibers of the orbicularis palpebrarum muscle; 4, tarsal plate; 5, conjunctival sac; 6, outer palpebral ligament; 7, temporal muscle; 8, wall of the orbit; 9, external rectus muscle; 10, orbital fat; 11, optic nerve; 12, internal rectus muscle; 13, inner check ligament; 14, inner wall of the orbit; 15, attachment of the capsule of Tenon (16) to the conjunctiva; 17, Tenon's space; 18, outer check ligament; 19, lachrymal gland; 20, ciliary process; 21, iris. (*Ball after Gerlach.*)

It is continuous in front with the subconjunctival connective tissue, and behind with the dura mater, through the sphenoidal fissure and optic foramen, and consists of two layers—a visceral layer investing the posterior portion of the eyeball, and a parietal layer lining the cushion of fat on which the eye rests.

The inner aspect is lined with flattened endothelial cells, and incloses a lymph space communicating with *subdural* and *subarachnoidean* lymph spaces of the optic nerve sheath. It sup-

ports the lachrymal gland, is strengthened by numerous fibrous bands, and is pierced by the ocular muscles, inclosing them in imperfect sheaths.

The *capsule of Bonnet* is the name given to the portion posterior to the passage of the tendons, and

The *capsule of Tenon* is then applied to the anterior socket-like half.

The eyeball (*bulbus oculi*) is composed of a large, opaque segment of a sphere, forming about five-sixths of the globe, for the protection of its contents, and a smaller transparent segment of a sphere, implanted upon and continuous with it in

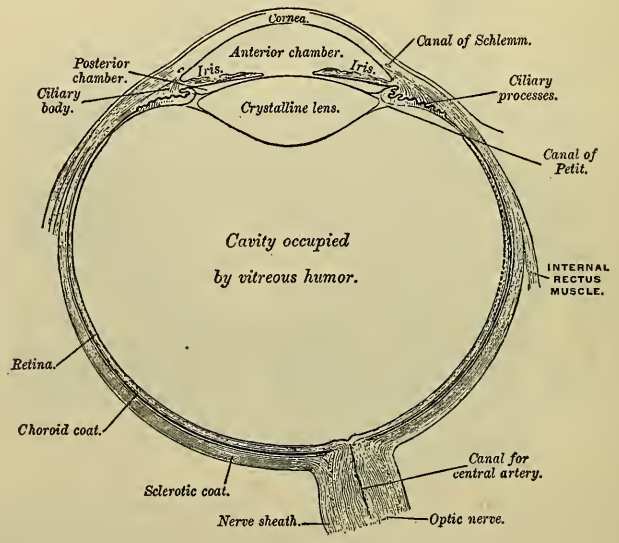

FIG. 129.

front. The optic nerves enter the eyeballs to their nasal side, in the direction of the axes of the orbit.

It is composed of three tunics or coats:—

1. Sclerotic and cornea,
2. Choroid, iris and ciliary processes,
3. Retina;

And three humors, or refracting media:—

1. Aqueous humor,
2. Crystalline lens (and capsule),
3. Vitreous humor, or body.

The sclerotic coat, so called from its extreme hardness, is thicker behind (one twenty-fifth of an inch) than in front (one-sixtieth of an inch), and presents two surfaces for study—the external and internal.

The *external surface* is smooth and white, and has attached to it the various muscles of the eye.

The *internal surface* is grooved for the passage of the ciliary nerves, and connected to the choroid by a fine areolar layer—the lamina fusca (*laminæ fasciæ scleræ*).

Behind, and a little to the nasal side, where the optic nerve enters, it presents a perforated appearance—the *lamina cribrosa*—the larger opening of which—the porus opticus—transmits the arteria centralis retinæ; the others transmit the ciliary vessels and nerves. It is continuous in front with the cornea, overlapping it a little on its outer margin.

In *structure* it is made up of white, fibrous tissue, with a small quantity of elastic fibers and connective-tissue corpuscles.

The *arteries* are from the anterior and short posterior ciliary.

The *veins*—venous blood removed by venæ vorticosæ and the anterior ciliary.

The *nerves* are from the ciliary.

The cornea is the convex, transparent, nearly circular tissue forming the anterior one-sixth of the globe. It is from one twenty-second to one thirty-second of an inch in thickness. Its thickness at the periphery is 1.12 millimeters, hence its posterior surface is more curved than the anterior. Its transverse diameter is a little greater than the vertical, owing to the overlapping of the sclerotic above and below. It is composed of four layers:—

1. Conjunctival epithelium, or anterior layer (*epithelium corneæ*),
2. Cornea proper, or substantia propria, { Anterior elastic lamina (*lamina elastica anterior*),
3. Posterior elastic lamina (*lamina elastica posterior*), } Cornea proper;
4. Endothelial lining (*endothelium cameræ anterioris*), } Membrane of Descemet.

The *conjunctival epithelium* consists of several layers of cells (columnar, polyhedral and squamous) covering the anterior surface of the cornea, continuous with the conjunctiva.

The *anterior elastic lamina* is the name given to the outer epithelial layer of the cornea proper.

The *cornea proper* is made up of a transparent fibrous structure, identical with the sclerotic, and consisting of about sixty layers or lamina, connected by a cement substance inclosing *corneal spaces*, each of which contains a *corneal corpuscle.*

The *posterior elastic lamina* consists of an elastic homogeneous membrane, internal to the proper structure of the cornea, and constituting, with the epithelial lining, the *membrane of Descemet,* or *Démours.*

The *structure* of the cornea is non-vascular, being nourished by channels representing lymphatic vessels, and continuous with the corneal spaces. The nerves derived from the ciliary nerves are numerous, and form between the outer surface of the cornea proper and the epithelial covering the *subepithelial plexus,* from which is given off the *intraepithelial* plexus.

The second tunic consists of the choroid, lining the sclerotic coat throughout; the iris, the circular curtain suspended in the aqueous humor and perforated by the pupil; and the ciliary ligament and muscle at the junction of the two.

The choroid (*choroidea*) is a dark, reddish-brown, highly vascular membrane, lining the sclerotic coat from the optic nerve to the ciliary ligament, where it projects backward in a number of processes, the *ciliary processes.* It is in contact externally with the sclerotic, to which it is attached by the membrana fusca, and internally with the retina.

The *structure* consists chiefly of a dense capillary network.

The *choroid proper* consists of an external and an internal layer, and is separated from the sclerotic by the *lamina suprachoroidea,* continuous with the lamina fusca of the sclerotic, and from the pigmentary layer of the retina by the *lamina vitrea.*

The *external layer* or the *lamina vasculosa* consists of a capillary network, derived from the larger branches of the short ciliary arteries, inclosing between the meshes large, star-shaped pigment cells, which are connected together by a delicate stroma. They terminate in the *venæ vorticosæ,* which emerge through the sclerotic midway between the optic nerve and the margin of the cornea.

The *internal* layer is also composed of a fine capillary network, derived from the short ciliary arteries, and continuous in front with the vessels of the ciliary processes. It is called the tunica Ruyschiana (*lamina choriocapillaris*).

The *lamina basalis,* or *membrane of Bruch,* is a thin, structureless layer, separating the pigmentary layer of the retina from the stroma of the choroid.

The *arteries* are from posterior ciliary, short ciliary (principally in the external layer), and recurrent branches of long and anterior ciliary.

The *veins* converge from the venæ vorticosæ to form four or five trunks, which pierce the sclerotic midway between the optic nerve and corneal margin to join the cavernous sinus.

The *nerves* are the long and short ciliary.

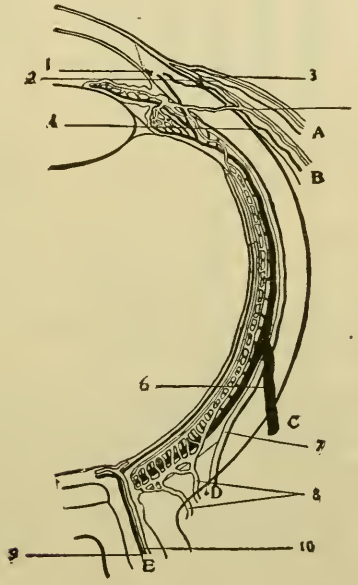

FIG. 130.

Vessels of the eye. *A*, conjunctival vessels; *B*, anterior ciliary vessels; *C*, vena vorticosa; *D*, posterior ciliary arteries; *E*, central retinal vessels. (*Ball.*)

The ciliary processes (*processus ciliares*) are a series of sixty to eighty pigmented vascular processes arranged circularly around the lens behind the iris, and composed of the two internal layers of the choroid folded inward. They are continuous in front with the iris, and are connected behind with the suspensory ligament of the lens.

The *structure* is similar to that of the choroid.

THE IRIS is a thin, circular curtain, suspended in the aqueous humor, between the lens and cornea, and perforated by a circular aperture—the pupil (*pupilla*).

Its circumference is connected with the choroid, and also by means of the ciliary ligament with the sclerotic and cornea. The sclerotic contains in this position, near its junction with the cornea, a circular canal (lymph canal, or venous sinus), the sinus circularis iridis, or canal of Schlemm (*sinus venosus sclerœ*).

The circumference of the iris is also connected in front with the cornea by pectinate ligament (*ligamentum pectinatum iridis*), derived from the membrane of Descemet.

The *structure* is composed of four elements:—

1. A basement membrane and polyhedral cells, continuous with the membrane of Descemet;

2. Stroma (*stroma iridis*) consisting of bundles of fibrous tissue and cells;

3. Muscular fibers, { Circular fibers (*m. sphincter pupillæ*), forming the sphincter of the pupil; Radiating fibers (*m. dilator pupillæ*), forming the dilator of the pupil;

4. *Pigment*, consisting of polyhedral or round pigment cells, distributed for the most part to the posterior surface, which, from its deep-purple tint, has been called the uvea.

The *arteries* are from the long and anterior ciliary and from the ciliary processes (from the short ciliary).

The *veins* join those of the ciliary processes and anterior ciliary veins.

The *nerves* are the long ciliary from the nasal branch of the ophthalmic (first division of fifth), and ciliary branches from the lenticular or ophthalmic ganglion.

The circular fibers are supplied by the fibers from the third or motor oculi, the radiating fibers are supplied by the sympathetic.

The *membrana pupillaris* is a delicate, vascular membrane, closing the pupil in the fetus, continuous at its margin with the iris. It usually disappears about the eighth month, but occasionally persists.

The ciliary muscle (*m. ciliaris*) is a grayish, circular band of unstriated fibers, attached to the fore part of the choroid. It consists of two sets of fibers—the external radiating fibers (*fibræ meridianales* [Bruckei]), *dilator pupillæ*—arising from the junction of the sclerotica and cornea, and is inserted into the choroid opposite the ciliary processes; the internal circular

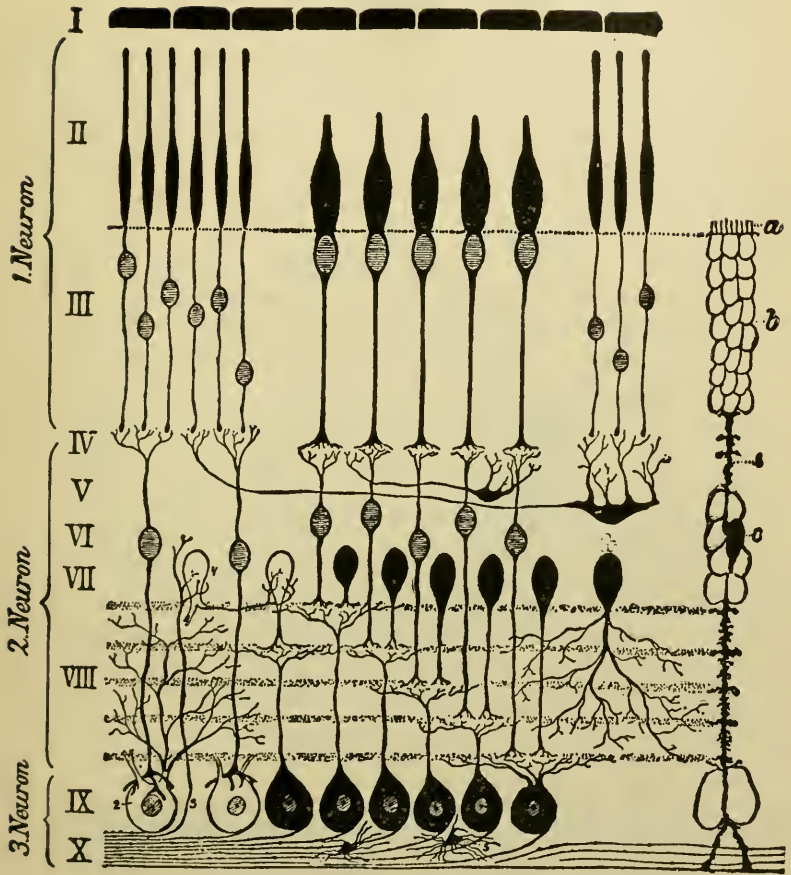

FIG. 131.

The structure of the human retina. I, pigment epithelium layer; II, rods and cones; III, granules of the visual cells; IV, outer plexiform layer; V, layer of horizontal cells; VI, layer of bipolar cells; VII, layer of amacrine cells; VIII, inner plexiform layer; IX, ganglion cell layer; X, layer of nerve fibers; 1, diffuse amacrine cell; 2, diffuse ganglion cell; 3, centrifugal nerve fiber; 4, amacrine association fibers; 5, neuroglia cells; 6, Müller's radial fibers. (*Ball after Greeff.*)

fibers (*fibræ circulares* [Mülleri]), *sphincter pupillæ,* pursue a circular course around the insertion of the iris.[1]

It is the muscle of accommodation, its contraction drawing on the ciliary processes, relaxing the circular fibers described as the ligament of the lens, and allowing the anterior surface of the lens to become more convex by its inherent elasticity.

THE RETINA is a delicate, white, nervous membrane, the

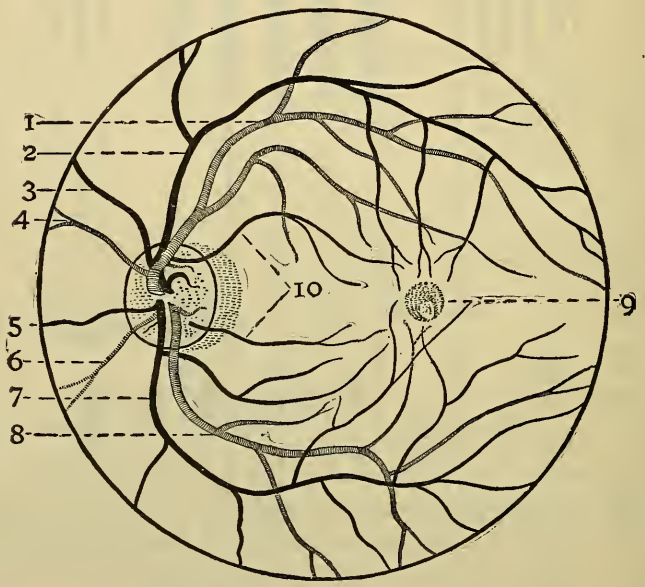

FIG. 132.

Diagram of the retinal vessels. 1, superior temporal artery; 2, superior temporal vein; 3, superior nasal vein; 4, superior nasal artery; 5, inferior nasal vein; 6, inferior nasal artery; 7, inferior temporal vein; 8, inferior temporal artery; 9, macula lutea; 10, macular veins. (*Ball.*)

expansion of the optic nerve. It lines the eyeball, being in contact externally with the choroid and internally with the vitreous body. It terminates in front near the ciliary body in

[1] Quite recently it has been the consensus of opinion among anatomists that the circular fibers are but partially attached to the radiating fibers, pursuing a circular course around the attachment of the iris. These circular fibers are sometimes designated the "ring muscle" of Müller, and were formerly described and regarded as the "ciliary ligament."

an irregular margin, the *ora serrata,* but is prolonged forward as the *pars ciliaris* to the iris. Its internal posterior surface presents at a point corresponding to the axis of the eyeball a small, round, elevated spot of yellowish color (*macula lutea*), or *yellow spot* of Sömmering, in the center of which is the *fovea centralis,* a central depression, the region of most acute vision, and about one-tenth of an inch to its nasal side, at a point corresponding to the axis of the orbit, the entrance of the optic nerve, an oval, bluish-white depression, with distinct, often pigmented margins, a region destitute of vision and called the optic disk (*porus opticus*). Its center presents the arteria centralis retinæ, giving branches to the upper and lower nasal side of the macular region.

The *structure* of the retina is exceedingly complex, consisting microscopically of ten distinct layers from within outward, as follows:—

1. *Membrana limitans interna*, the most internal layer of the retina, forms the base of the connective-tissue framework of the retina, from which it is derived.

2. The *fibrous layer* consists of nerve fibers, the termination of the optic nerve fibers.

3. The *vesicular layer*, composed of a layer of large, flask-shaped ganglionic cells. It is wanting in the macular region.

4. The *inner molecular layer* is composed of a layer of glandular-like structure, forming a reticulum inclosing minute granules.

5. The *inner nuclear layer* is composed of three sets of nuclear bodies, the first resembling bipolar nerve cells, the second without branches, and third continuous with the radiating fibers, or fibers of Müller.

6. The *outer molecular layer* resembles closely the inner molecular layer, from which it differs only by containing branched stellate cells.

7. The *outer nuclear layer* is composed of several layers of nuclear cells, separable into two kinds, the *rod granules* and *cone granules*, both continuous with the rods and cones of Jacob's membrane.

8. The *membrana limitans externa* is, like the internal limiting membrane, derived from the radiating fibers, or fibers of Müller.

9. *Jacob's membrane*, or the layer of rods and cones, consists of two distinct kinds of cells—the rods and cones, distributed alternately throughout this layer, the rods being much more numerous.

The rods are solid, stand perpendicularly to the surface, and consist of two portions—an outer striated and an inner granular.

The cones are flask-shaped, with their pointed extremities toward the choroid. They also consist of two portions—an outer striated and an inner granular.

10. The *pigmentary layer* was formerly described as a layer of the choroid. It has received the name of *tapetum nigrum*, consisting of a layer of pigmented hexagonal epithelial cells.

In many of the lower animals, this layer on the posterior surface is destitute of pigment, and is called from its iridescent lustre the *tapetum lucidum.*

The *radiating fibers*, or *fibers of Müller*, consist of connective-tissue fibers, connecting all the layers together, and forming the membrana limitans interna and the membrana limitans externa.

The *structure* of the retina at the *macula lutea* differs in the following manner: the cones only, of Jacob's membrane are present; the vesicular layer consists of several strata, and in the outer nuclear layer only the cone fibers are present.

At the fovea centralis only the cones of Jacob's membrane, the outer nuclear layer, and the internal granular layer are present.

The *arteria centralis retinæ* supplies only as far as the inner nuclear layer.

THE HUMORS OF THE EYE.

THE AQUEOUS HUMOR (*humor aqueus*) is a transparent, alkaline, serous fluid, small in quantity, weighing four to five grains, and filling the anterior and posterior chambers of the eye. It is composed of water, 96.7; extractive matters, principally chloride of sodium and albumin, 0.1.

The anterior chamber (*camera oculi anterior*) is the space (about 2.7 millimeters in depth) between the iris and the cornea.

The posterior chamber (*camera oculi posterior*) is the space between the anterior surface of the lens and the iris. It amounts to a space only at the circumference, the two being in contact at the posterior surface.

THE CRYSTALLINE LENS (*lens crystallina*) is a biconvex, transparent, elastic body, suspended with its capsule (*capsula lentis*), surrounded by the ciliary processes. It is more convex on its posterior surface (anterior surface has an average radius of 10 millimeters, the posterior 6 millimeters), and is received into a hollow depression in the hyaloid membrane.

It measures about one-third inch in diameter, one-fourth inch in axis, and weighs from four to four and one-half grains.

Its index of refraction increases from the periphery to the center, with an average of 1.4371.

Its composition consists of about 60 per cent. water; soluble albuminous matter, 35 per cent.; insoluble albuminous matter, 2.5 per cent.; cholesterin and fat, 2 per cent.

The *structure of the lens* consists of concentric laminæ, made up of hexagonal prisms, about one-five-thousandth inch in breadth, united laterally by dentated margins, and curving

round the borders of the lens. The laminæ are arranged into three triangular segments.

The central portion, or *nucleus*, is unstratified, while the outer layers, or *cortex*, each contain a nucleus, forming a nuclear layer.

The capsule of the lens (*capsula lentis*) is a clear, elastic, brittle membrane, inclosing the lens, and held in position by the suspensory ligament. Its anterior layer is thicker, and is attached to the lens by a layer of polygonal nucleated cells, which break down post-mortem to form the *liquor Morgagni*.

The canal of Petit (*spatia zonularia*) is about one-tenth inch in diameter, encircling the capsule of lens. Its base is formed by the capsule, and it is bounded in front by suspensory ligament, behind by the hyaloid membrane of the vitreous humor.

The suspensory ligament, or zonula of Zinn (*zonula ciliaris*), is a thin, transparent structure, extending from the margins of the hyaloid fossa, where it is continuous with hyaloid membrane, to the anterior margin of the lens.

The vitreous humor, or body (*corpus vitreum*), is a clear, albuminous fluid, filling the cavity of the retina, hollowed out in front—hyaloid fossa (*fossa hyaloidea*)—for the lens, and inclosed in the hyaloid membrane (*membrana hyaloidea*). It is composed of water, with a few salts and a little albumin.

Its structure is finely reticular, particularly in the fetus.

The canal of Stilling, canal of Cloquet, or hyaloid canal (*canalis hyaloideus*), is a canal extending in the fetus from the entrance of the optic nerve to the lens, containing fluid, and lined by a fold of hyaloid membrane.

In the fetus a canal extends parallel but independent of this, and transmits a minute artery to the capsule of the lens.

The hyaloid membrane (*membrana hyaloidea*) is a delicate capsular membrane, investing the vitreous body, excepting its anterior surface, sends fibrous septa into the structure of the vitreous, and is continuous in front with the posterior capsule, and with the anterior capsule through the suspensory ligament.

MUSCLES OF THE EYEBALL.

Rectus Superior (*m. rectus superior*).—*Origin,* sheath of the optic nerve and upper margin of optic foramen; *insertion,* into upper surface of sclerotic coat, three or four lines from corneal margin; *action,* rotates the eyeball upward; *nerve,* third cranial.

Rectus Inferior (*m. rectus inferior*).—*Origin,* from lower and inferior part of optic foramen (ligament of Zinn—*annulus tendineus communis*); *insertion,* into lower surface of sclerotic; *action,* rotates the eyeball downward; *nerve,* third cranial.

Rectus Internus (*m. rectus internus*).—*Origin,* same as

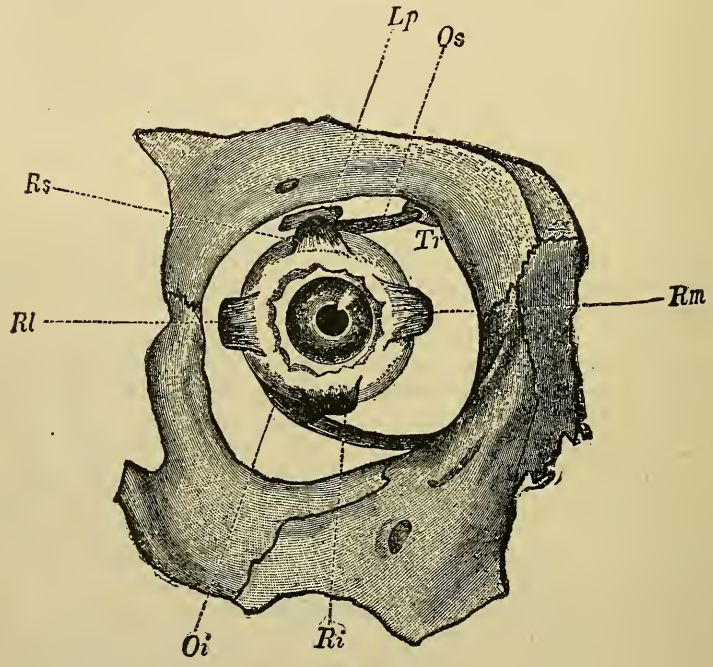

Fig. 133.

The orbital muscles. *Lp,* levator palpebræ superioris; *Os,* superior oblique; *Rs,* superior rectus; *Rl,* external rectus; *Oi,* inferior oblique; *Ri,* inferior rectus; *Rm,* internal rectus; *Tr,* trochlea. (*Ball.*)

inferior rectus; *insertion,* into inner surface of sclerotic; *action,* rotates the eyeball inward; *nerve,* third cranial.

Rectus Externus (*m. rectus lateralis*).—*Origin,* by two heads—lower, from ligament of Zinn and lower margin of sphenoidal fissure; upper, from outer margin of optic foramen; *insertion,* into outer surface of sclerotic; *nerve,* abducens, or sixth cranial. Passing between the two heads are the ophthalmic vein, the third, nasal branch of fifth and sixth nerves.

Superior Oblique (*m. obliquus superior*).—*Origin,* from inner margin of optic foramen. Its tendon passes through a pulley (*trochlea m. obliqui superior*) near the internal angular process of the frontal bone; *insertion,* into sclerotic between external and superior recti, midway between entrance of optic nerve and the cornea; *action,* rotates the eyeball on its axis; *nerve,* fourth, or patheticus.

Inferior Oblique (*m. obliquus inferior*).—*Origin,* orbital plate of superior maxilla; *insertion,* near that of superior

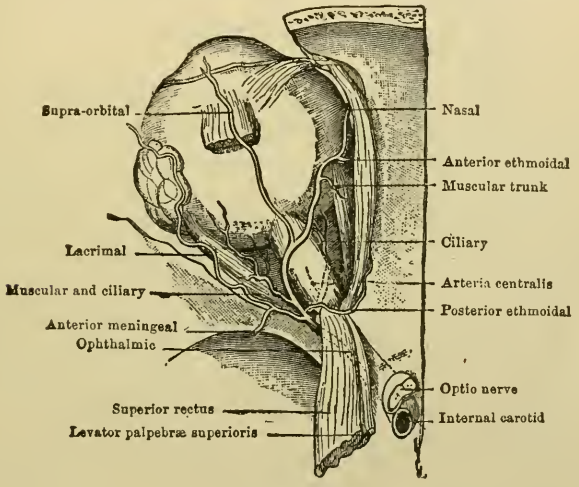

Fig. 134.

Ophthalmic artery and branches. (*Ball, after Merkel and Kallius.*)

oblique, between external and superior recti; *action,* rotates the eyeball on its axis; *nerve,* third cranial.

The arteries of the globe of the eye are:—

1. The *short ciliary,* enter through the sclerotic around the optic nerve, to supply the choroid and ciliary processes.

2. The *long ciliary arteries,* two in number, pierce the sclerotic, run forward between the choroid and sclerotic to the ciliary muscle, which they supply, and where they form an anastomotic circle about the iris.

3. The *anterior ciliary arteries,* five or six in number, enter the sclerotic in front, supply the ciliary process, and anastomose about the iris.

4. The *arteria centralis retinæ* supplies the retina, dividing into four or five branches, which enter as deeply as the inner nuclear layer.

The *other arteries* supplying the eye and its appendages are derived from the *ophthalmic* branch of the internal carotid (the same source as the ciliary arteries), the *anterior cerebral* branch of the internal carotid, and the *infraorbital* branch of the internal maxillary.

The branches of the ophthalmic are:—

Lachrymal;
Supraorbital;
Anterior and posterior ethmoidal;
Palpebral;
Frontal;
Nasal. (For description see Arterial System.)

The *veins* of the eyeball emerge as the *venæ vorticosæ,* unite with the other veins to form two main trunks—the *ophthalmic* and *inferior ophthalmic* veins—to terminate in the cavernous sinus. The ophthalmic vein anastomoses freely with the angular vein, the commencement of the facial at the inner angle of the orbit.

The *nerve* of *special sense,* the optic or second cranial, supplies the eye and its appendages; *motor nerves,* the third and fourth; branches of the fifth and sixth, and filaments from the sympathetic.

Sensory nerve, ophthalmic division of the trifacial, or fifth cranial (*vide* Cranial Nerves).

Sympathetic branches, derived chiefly from the ciliary ganglion, Meckel's ganglion, and the cavernous and carotid plexuses (*vide* Cranial Sympathetic Ganglion).

APPENDAGES OF THE EYE.

The appendages of the eye (*tutamina oculi*) include: The eyebrows (*supercilia*), the eyelids (*palpebræ*), conjunctiva, and the lachrymal apparatus (*apparatus lacrimalis*); lachrymal gland, lachrymal sac, nasal duct.

The eyebrows (*supercilia*) are the elevated arches of skin surmounting the upper margins of the orbits, covered with short, thick hairs.

The eyelids (*palpebræ*) are two movable folds, covering and protecting the front of the eye. The upper lid (*palpebra superior*) is larger, longer, and more movable, being supplied with a special muscle—the levator palpebræ superioris.

The lids are separated by an elliptical fissure—the *fissura palpebrarum*—and connected at their angles of junction by the outer (*angulus oculi lateralis*) and inner (*angulus oculi medialis*) canthi.

On the nasal side the lids are separated by a triangular space—the *lacus lacrimalis*—at the outer angles of which are the *lachrymal papillæ*, surmounted by the *punctum lacrimale*, the commencements of the lachrymal canal. The *lacus lacrimalis* is filled by the *caruncula lacrimalis*, a mass of follicles resembling the Meibomian glands, and covered by the conjunctiva.

The *structure* of the *eyelids*, from without inward, is as follows:—

Skin, subcutaneous areolar tissue, fibers of the orbicularis muscle, tarsal cartilage, fibrous membrane, Meibomian glands, vessels and nerves;

The *skin* is thin, and attached by a very loose areolar tissue to the muscle beneath;

The fibers of the orbicularis are pale, thin, and act involuntarily;

The *tarsal cartilages* are two plates of firm connective tissue; the superior (*tarsus superior*), the larger, is semilunar in shape, the inferior (*tarsus inferior*) is elliptical. The inner margins are fixed to the orbit by tendo oculi;

The *fibrous membrane of the lids*, or *tarsal ligament*, passes over the anterior surface of the tarsal cartilage, being attached to its free margin below and to the margin of the orbit externally;

The Meibomian glands (*glandulæ tarsales* [Meibomi]), about thirty in number in the upper, a few less in the lower lid, are arranged vertically on the inner surface of the cartilages; they are straight, sebaceous follicles, into which open a number of secondary follicles, terminating above in a blunt extremity, and opening below on the free margin of the lids by small foramina, corresponding to the number of tubules;

The eyelashes (*cilia*), are arranged on the free border of the lids in two or three rows.

The conjunctiva is the mucous lining membrane of the front of the eye. It consists of two portions—the *bulbar*, reflected over the sclerotic and cornea, and the *palpebral* portion, lining the internal surface of the lids.

The bulbar portion (*tunica conjunctiva bulbi*) is loosely connected with the sclerotic, but over the cornea it becomes very thin, consisting only of the epithelial layer.

The palpebral portion (*tunica conjunctiva palpebrarum*) is thick, highly vascular, and contains many papillæ. At the inner angle of the eye it forms a semilunar fold, the plica semilunaris (*plica semilunaris conjunctivæ*)—the rudiment of the nictitating membrane of birds, the *membrana nictitans*.

The point of reflection is called the *fornix conjunctivæ,* and the reflected portions the *superior* and *inferior palpebral folds.*

The lachrymal apparatus (*apparatus lacrimalis*) consists of the lachrymal gland, canals, sac and nasal duct.

The lachrymal gland (*glandula lacrimalis*) is an oval, glandular body, about the shape and size of an almond, situated in a depression in the upper surface of the orbit near the external angular process.

The anterior portion of the gland is sometimes described

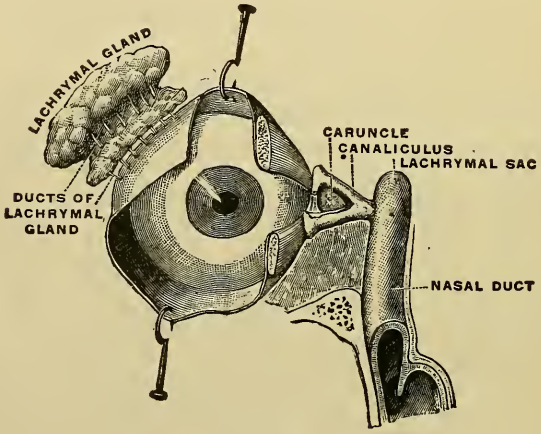

Fig. 135.

The lachrymal apparatus. (*Gerrish, after Testut; Eckley.*)

as a separate lobe—the palpebral portion of the gland, or accessory gland of Rosenmüller (*glandula lacrimalis inferior*); the back part of the gland is designated the superior lachrymal gland (*glandula lacrimalis superior*).

The gland is attached to the bony roof of the orbit by the *tarso-orbital fascia.*

The *ducts,* seven to ten in number, open upon the conjunctiva near its point of reflection by minute orifices arranged in a row.

The *lachrymal canals* commence at the puncta lacrimalia, at the summits of the lachrymal papilla (*carunculus lacrimalis*), and descend by two *canaliculi* to empty into the lachrymal sac.

The superior canal (*ductus lacrimalis superior*) descends obliquely inward and downward, while the inferior (*ductus*

lacrimalis inferior) descends at first and then passes nearly horizontally inward.

The lachrymal sac (*saccus lacrimalis*) is the oval, dilated, upper portion of the nasal duct, lodged in a deep groove formed by the nasal process of the superior maxilla and the lachrymal bone. It is crossed by the tensor tarsi muscle, which acts as a compressor, and receives a fibrous expansion from the tendo oculi.

Its *structure* is made up of a fibrous elastic coat, lined by mucous membrane continuous with the nose and conjunctiva.

The nasal duct (*ductus nasolacrimalis*) is a membranous tube about three-quarters of an inch in length, extending from the lachrymal sac to the inferior meatus of the nose, and lining the bony lachrymonasal canal. It passes backward, downward, and outward, and is protected at its inferior extremity by a valve of mucous membrane—the valve of Hasner (*plica lacrimalis* [*Hasneri*]).

The mucous lining is continuous with that of the sac, but instead of having squamous epithelium it is ciliated in the duct.

THE EAR.

The ear (*organon auditus*)—the organ of hearing—is contained in the petrous and mastoid portions of the temporal bone, and consists of three divisions,—external ear, middle ear or tympanum and internal ear or labyrinth:—

1. External ear,
   - Auricle or pinna,
   - External auditory canal or meatus;
2. Middle ear or tympanum,
   - Membrana tympani,
   - Tympanic cavity,
   - Mastoid sinuses,
   - Eustachian tube;
3. Internal ear or labyrinth,
   - Osseous portion,
     - Vestibule,
     - Semicircular canals,
     - Cochlea;
   - Membranous portion,
     - Utricle,
     - Saccule,
     - Semicircular canals,
     - Cochlea.

The external ear includes two parts, the auricle and the external auditory canal.

AURICLE (AURICULA), OR PINNA.

The external prominent portion is composed of cartilaginous segments, connected together by ligaments and muscles richly supplied with blood vessels, nerves, and lymphatics, and covered with skin. It presents the following elevations and depressions:—

Fossa of the helix, a depression between the helix and antihelix;

Fossa of the antihelix (*fossa triangularis* [*auriculæ*]), a depression above the bifurcation of the antihelix;

Tragus, the prominence in front of the concha, usually covered with hair;

Antitragus, a small, conical eminence behind the tragus, from which it is separated by the incisura intertragica;

Lobule (*lobulus auriculæ*), the soft, rounded portion depending below the antitragus;

Concha, a deep cavity, surrounded by the helix, leading into the external meatus.

Muscles.—The muscles of the auricle include two sets, the extrinsic muscles, already described (*vide* Muscles), of which there are three—the attolens aurem, attrahens aurem and retrahens aurem—and the intrinsic muscles, but slightly developed, of which there are two sets, four on the anterior surface of the auricle—the tragicus (*m. tragicus*), antitragicus (*m. antitragicus*), helicis major (*m. helicis major*), and helicis minor (*m. helicis minor*)—and two on the posterior surface, transversus auriculæ (*m. transversus auriculæ*) and obliquus auriculæ (*m. obliquus auriculæ*).

Arteries, auricular branch, from the occipital; posterior auricular, from the external carotid; and anterior auricular, from the temporal. The *veins* correspond to the arteries.

Nerves, auricular branch, from the pneumogastric; auriculotemporal branch, from the inferior maxillary; occipitalis major and occipitalis minor; auricularis magnus, from the cervical plexus; and posterior auricular, from the facial.

AUDITORY CANAL, or *meatus auditorius externus* (*meatus acusticus externus*), is an osseocartilaginous canal, about one and one-fourth inches in length, extending from the concha to the tympanic membrane.

The osseous portion (*pars ossea tubæ auditivæ*, or *semicanalis tubæ auditivæ*) forms about two-thirds of the passage, and consists in greater part (anterior and lower) of a curved plate of bone—the *annulus tympanicus.*

The anterior and upper part of the ring presents two spines —*spina tympanica, major* and *minor*—for the ligaments of the malleus.

The *sulcus tympanicus* is a furrow on the inner edge of the ring, for the attachment of the tympanic membrane.

The cartilaginous portion (*pars cartilaginea tubæ auditivæ*) forms about one-third of the passage, and consists of the inverted cartilage of the tragus and concha, the upper and back part of which is deficient, the cleft being filled with fibrous tissue.

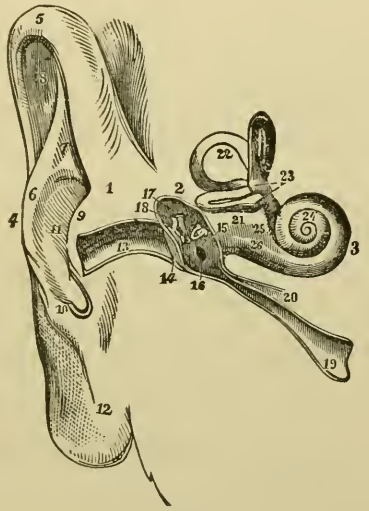

FIG. 136.

External, middle, and internal ear. 1, external ear; 2, middle ear; 3, internal ear; 4, pinna; 5, helix; 6, antihelix; 7 fossa navicularis; 8, fossa innominata; 9, tragus; 10, antitragus; 11, concha; 12, lobe; 13, meatus auditorius externus; 14, tympanic membrane; 15, promontory; 16, foramen rotundum; 17, posterior wall of the tympanum; 18, ossicula auditus; 19, Eustachian tube; 20, narrow canal; 21, vestibule; 22, semicircular canals, the superior, posterior, and horizontal; 23, ampullæ, 24, cochlea; 25, prominence caused by the scala vestibuli; 26, scala tympani. (*Boenning.*)

The *canal,* including the tympanic membrane, is lined throughout with skin, containing short hairs, vascular papillæ, sebaceous and ceruminous glands (*glandulæ ceruminosæ*).

Arteries—branches of the internal maxillary, posterior auricular and temporal branches of external carotid.

Nerves—from the auriculotemporal branch, the inferior maxillary and auricular branch of the pneumogastric.

MIDDLE EAR (AURIS MEDIA), OR TYMPANUM,

is an irregular cavity (*cavum tympani*), situated between the auditory canal and the labyrinth, communicating with the pharynx through the Eustachian tube, and also with the mastoid cells. It contains a chain of movable bones, part of the chorda tympani nerve, and is filled with air. Its average diameters are about half an inch in height and width, and a line or two in depth from without inward. It is lined with mucous membrane, continuous with that of the Eustachian tube and mastoid cells, and which is reflected over all the tympanic contents. It is bounded by a roof, floor and four walls, which present the following points:—

Roof (*paries tegmentalis*), a very thin plate of bone (*tegmen tympani*), separates the tympanum from the cranial cavity, and corresponds to a depression on the anterior wall of the petrous bone;

Floor (*paries jugularis*), forms the bottom of the jugular fossa, and presents:—

The *opening* for *Jacobson's nerve*, the tympanic branch of the glossopharyngeal (*n. tympanicus*).

Outer wall, formed by the tympanic membrane, Shrapnell's membrane, and the annulus tympanicus surrounding it:—

Notch of Rivinus (*incisura tympanica* [Rivini]), incomplete upper ring of bone;

Iter chordæ posterius (*canaliculus chordæ tympani*), gives entrance to chorda tympani nerve;

Iter chordæ anterius, or *canal of Huguier*, gives exit to same;

Glaserian fissure (*fissura petrotympanica* [Glaseri]), above and in front of annulus tympanicus, receives the anterior ligament of the malleus, the long process of the malleus, and the tympanic artery;

Pouches of the membrana tympani, are two or three pockets formed by the doubling of the mucous membrane around the chorda tympani nerve.

Inner wall (*paries labyrinthica*), separates the tympanum from the labyrinth:—

Fenestra ovalis (*fenestra vestibuli*), an oval window, leading to the vestibule, closed by the membrane to which the base of the stapes is attached;

Fenestra rotunda (*fenestra cochleæ*), a round window, leading to the scala tympani, but closed also by a membrane—*membrana tympani secundaria*.

Promontory (*promontorium*), two grooves, marking the first turn of the cochlea, and separating the fenestræ ovalis and rotunda;

Rounded eminence of the aqueductus Fallopii (*prominentia canalis facialis*), a small conical eminence above the fenestra ovalis, which contains within it the aqueductus Fallopii, the long canal for the facial nerve.

Posterior wall (*paries mastoidea*) :—

Openings of the mastoid cells, three or four in number, connect these sinuses with the tympanum.

Anterior wall (*paries carotica*), is a thin plate of bone, which separates the tympanum from the carotid canal.

Openings of the canal for tensor tympani (*semicanalis m. tensoris tympani*), lies above and parallel with the canal for the Eustachian tube, and transmits the tensor tympani muscle;

Opening of Eustachian tube (*tubæ auditiva* [*Eustachii*]), the larger of the two, is separated from the former by a thin plate of bone, the processus cochleariformis (*septum canalis musculotubarii*).

The tympanum is divided into two parts—the attic (*recessus epitympanicus*) of the tympanum and the atrium. The former is situated on a plane directly above the atrium, and is bounded above by the tegmen, externally by auditory plate, and internally by prominence of the tympanum. On the outer part of the attic is a smooth surface called the *scute* (Leidy).

The Eustachian tube (*tubæ auditiva* [*Eustachii*]) is an osseocartilaginous canal, one and one-half to two inches in length, extending from the tympanum to the pharynx.

It is about one-third osseous and two-thirds cartilaginous, and lined with ciliated epithelium continuous with the pharynx and tympanum. Its *pharyngeal orifice* is trumpet-shaped, and opens at the side of the pharynx, behind the inferior meatus.

Muscles of the *Eustachian tube:*—

Tensor palati (*m. tensor veli palatini*), the most important has been described (*vide* Palatal Region). Its action is to pull the anterior wall of the tube outward and downward, and widen the canal.

Internal Pterygoid (*vide* Muscles).—Some fibers are inserted into the floor of the tube. It acts as tensor of the fascia.

Ligamenta salpingopharyngeal, arises from the superior and middle constrictors of the pharynx, and is inserted by three to five tendinous cords into the pharyngeal orifice of the tube. Action, opens the tube.

Arteries of Eustachian Tube.—Pharyngeal from the external carotid, middle meningeal from the internal maxillary and small branches from the internal carotid.

Nerves, by branches from the glossopharyngeal, inferior maxillary, otic ganglion and facial nerve.

Membrana tympani is a thin, parchment-like membrane, stretched upon the annulus tympanicus, forming the bottom of the external auditory canal, and separating it from the tympanum. It is placed obliquely downward and inward at an angle of 45°.

Structure.—Its three layers are:—

External or *cuticular,* derived from the skin of the meatus;

Middle or *fibrous,* consisting of two sets of fibers, radiating and circular, the latter forming a tendinous ring around the margin;

Internal or *mucous,* continuous with the mucous membrane of the tympanum.

Its *outer surface* presents:—

Manubrium of *malleus,* projecting downward and backward;

Processus gracilis of *malleus,* projecting outward above the manubrium;

Umbo (*umbo membranæ tympanæ*), a depression of the membrane formed by the lower end of the manubrium;

Yellow spot, the cartilaginous end of the manubrium; *pyramid of light,* a triangular cone of reflected light in the antero-inferior quadrant of the membrane.

Inner surface (*vide* Outer Wall of Tympanum).

Arteries, tympanic branch of inferior, branch from the internal carotid.

Nerves, from the superficial temporal branch of the trifacial and from the tympanic plexus.

Ossicles of the Tympanum (Ossicula Auditus).

The small bones of the tympanum are three in number, and connect the membrana tympani with the membrane closing the fenestra ovalis. They are the

1. Malleus, or hammer, consists of a head (*capitulum mallei*), neck (*collum mallei*), manubrium or handle, processus gracilis (*processus anterior* [*Folii*]), and processus brevis (*processus lateralis*). The manubrium (*manubrium mallei*) is attached to the membrana tympani, and has the tendon of the tensor tympani attached. *Processus gracilis* is lodged in the Glaserian fissure.

2. Incus, or anvil, consists of a body (*corpus incudis*) and a long (*crus longum*) and short processes (*crus breve*). The

body articulates with the malleus and the long process by means of a rounded process. The os orbiculare (*processus lenticularis*) articulates with the head of the stapes.

3. Stapes, or stirrup, has a head (*capitulum stapedis*), neck, two branches or crura (*crura anterius et crura posterius*), which unite into a cross-piece or base (*basis stapedis*) The *neck* has inserted into it the stapedius muscle, and the *base* is fitted to the fenestra ovalis.

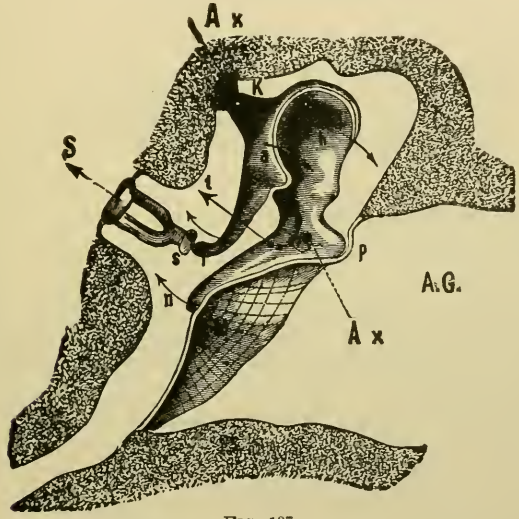

FIG. 137.

The auditory ossicles. *A. G.*, external meatus; *M*, membrana tympani; *u*, handle of the malleus and its short process (*p*); *h*, head of the malleus; *a*, incus; *K*, its short process, with its ligament; *l*, long process; *s*, os orbiculare; *S*, stapes; *Ax*, *Ax*, the axis of rotation of the ossicles, shown in perspective; *t*, line of traction of the tensor tympani. The other arrows show the movements of the ossicles when the tensor contracts. (*Boenning.*)

Ligaments of the ossicles (*ligamenta ossiculorum auditus*) :—

Anterior ligament of the malleus (*ligamentum mallei anterius*), extends from the neck of the malleus to the outer wall of the tympanum;

Superior ligament of the malleus—ligamentum mallei suspensorium (*ligamentum mallei superius*), suspends the head of the malleus to the roof;

Posterior ligament of the incus (*ligamentum incudis posterius*), attaches the short process to the posterior wall;

Superior ligament of the incus (*ligamentum incudis superius*), is merely a fold of mucous membrane; while the inner surface and cir-

cumference of the base of the stapes is connected to the margin of the oval window by means of the annular ligament of the stapes (*ligamentum annulare baseos stapedis*).

Muscles.—The tensor tympani and stapedius.

Tensor tympani (already described).

Stapedius (*m. stapedius*) arises from the hollow of the pyramid on the inner wall, and its tendon is inserted into the neck of the stapes. It is the smallest muscle in the human body. Nerve from the tympanic branch of facial.

Arteries:—

Tympanic branch of internal maxillary;
Stylomastoid branch of posterior auricular;
Petrosal branch of middle meningeal;
Tympanic branch from internal carotid;
Branch from ascending pharyngeal.

Veins accompany the corresponding arteries and empty into middle meningeal and pharyngeal.

Nerves:—

Chorda tympani, from the facial, enters the iter chordæ posterius, crosses the tympanum between the long process of the incus and the handle of malleus, and makes its exit at the iter chordæ anterius;

Tympanic branch of *glossopharyngeal* (Jacobson's nerve) enters the floor, supplies the fenestræ and mucous membrane of tympanum and Eustachian tube;

Tympanic branch from facial to the stapedius;

Branch from the otic ganglion to the tensor tympani.

The *tympanic plexus* is formed upon the surface of the promontory, from the following nerves:—

Jacobson's nerve, tympanic branch of the glossopharyngeal;
Branch of the superficial petrosal, from the facial;
Branches from the carotid plexus of the sympathetic.

INTERNAL EAR, OR LABYRINTH.

The internal ear (*auris interna*), the essential part of the organ of hearing, consists of three complex cavities within the petrous portion of the temporal bone, filled with fluid, the perilymph, and containing a membranous sac filled also with fluid, the endolymph, which receives the distributions of the auditory nerve.

Its divisions are:—

Osseous portion, { Vestibule, Semicircular canals, Cochlea;

Membranous portion, { Utricle, Saccule, Semicircular canals, Cochlea.

Vestibule (*vestibulum*), is a common cavity of communication between the bony parts of the internal ear. It is situated between the tympanum without, the cochlea behind, and the semicircular canals in front, and measures one-fifth of an inch in its anteroposterior and vertical diameters, and less from without inward. It presents:—

Fenestra ovalis (*fenestra vestibuli*) on its outer wall, closed by the stapes and its ligament;

Fovea hemispherica (*recessus sphæricus*), a circular depression on its inner wall for the saccule, and perforated by the macula cribrosa (*macula cribrosa media*), for the vestibular filaments of the auditory nerve;

Orifice of the *aquæductus vestibulæ,* on the inner wall for the transmission of a small vein;

Eminentia pyramidalis, a vertical ridge on the inner wall separating the two foveæ.

Fovea semielliptica (*recessus ellipticus*), in the roof lodges the utricle.

Semicircular canals (*canales semicirculares ossei*) are three canals, forming each two-thirds of a circle, one-twentieth of an inch in diameter, and named, from their position, the superior, posterior and external. They are placed nearly at right angles to each other and open into the vestibule by five apertures—two extremities uniting to form one.

The superior (*canalis semicircularis superior*) and posterior (*canalis semicircularis posterior*) are both vertical, the former being more anterior.

The external (*canalis semicircularis lateralis*) is placed horizontally, its arch directed backward.

Ampullæ, are the dilated, flask-shaped extremities of the tubes, and are about one-tenth of an inch in diameter.

The cochlea resembles closely a common snail's shell, placed with the base corresponding to the bottom of the meatus auditorius internus, and its apex directed outward and forward. It consists of two parallel tubes one and one-half inches in

length, one-tenth of an inch in diameter, wound spirally for two and one-half turns around a central pillar—the modiolus.

The modiolus, or columella (*basis modioli*), is broad at the base, but tapers gradually toward the apex, where it terminates within the last turn or cupola in the infundibulum, a funnel-shaped lamina of bone. Its interior is traversed by numerous canals for vessels and nerves, one of which—the *canalis centralis modioli*—runs nearly the whole length and transmits the *arteria centralis modioli.*

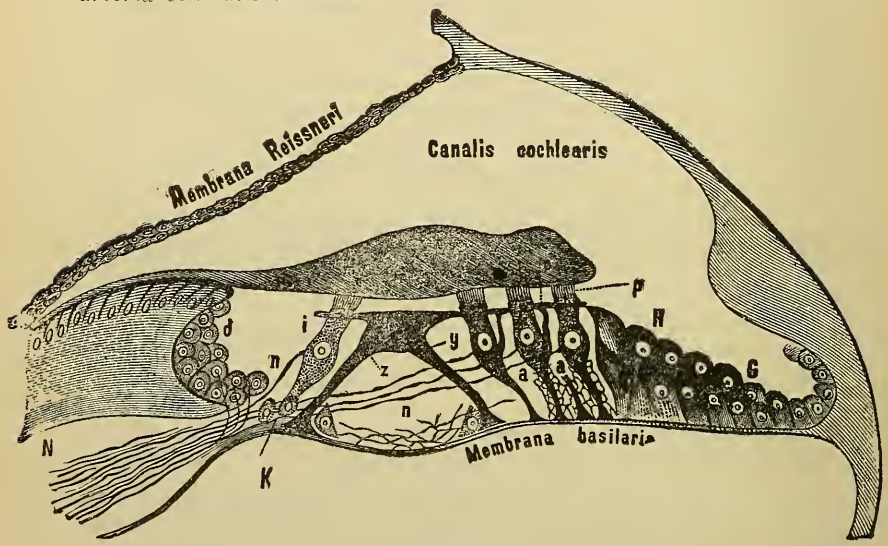

FIG. 138.

Organ of Corti. *N*, cochlear nerve; *K*, inner and, *P*, outer hair-cells; *n*, nerve fibrils terminating in *P*; *a*, *a*, supporting cells; *d*, cells in sulcus spiralis; *z*, inner rod of Corti; *Mb, Corti*, membrane of Corti, or the membrana tectoria; *o*, the membrana reticularis; *H*, *G*, cells filling up the space near the outer wall. (*Boenning.*)

Lamina spiralis, the partition between the two tubes, consists of two thin laminæ of bone filled with cancellous tissue—lamina spiralis ossea—projecting from the modiolus half-way to the outer wall, the lamina being completed by the *membrana basilaris.* The osseous lamina terminates in the cupola in a hook-like process—the hamulus (*hamulus laminæ spiralis*).

The *spiral canal,* between the modiolus and the outer wall, is divided by the lamina spiralis ossea and membrana basilaris into two canals, or *scalæ*—the upper scala vestibuli, and the lower scala tympani.

The first turn of the spiral canal presents three openings:—

1. *Fenestra rotunda*, a circular aperture communicating with the tympanum, and closed by the *membrana tympanum secundaria*.

2. *Fenestra ovalis*, an oval opening, communicating with the vestibule.

3. Aquæductus cochlearis (*apertura externa canaliculi cochleæ*), a small foramen opening on the inferior surface of the petrous portion of the temporal bone, and transmitting a small vein from the cochlea to the jugular vein.

Scala vestibuli, begins at the fenestra ovalis, and ascends in a spiral course above the lamina spiralis and membrana basilaris, to communicate with the scala tympani, through the helicotrema within the vestibule. It contains perilymph.

Scala tympani begins at the fenestra rotunda, and ascends in a spiral course below the scala vestibuli, from which it is separated by the osseomembranous lamina. It also contains perilymph.

Helicotrema is an opening within the cupola, by which the two scalæ communicate. It is formed by a deficiency of the osseous lamina.

Canalis spiralis modioli is a small canal which winds around the modiolus at the attachment of the osseous laminæ. It contains a gangliform swelling—ganglion spirale (*ganglion spirale cochleæ*)—from which nerves pass to the organ of Corti.

The membranous labyrinth (*labyrinthus membranaceus*) corresponds closely to the osseous, the vestibule consisting of two membranous sacs—the utricle and saccule—communicating with each other, and the former receiving the five openings of the membranous semicircular canals, the latter communicating with the membranous cochlea through the canalis reuniens (*ductus reuniens* [*Henseni*]). The membranous labyrinth is surrounded everywhere with perilymph (*perilympha*), filled with endolymph (*endolympha*), and is composed of three coats—an outer fibrous layer, middle or tunica propria and inner epithelial layer.

Utricle (*utriculus*), the larger of the two, is an elliptical sac lodged in the fovea hemielliptica. The semicircular canals communicate with it by five openings. Its wall is the thickest near the crista vestibuli, where the filaments of the nerve enter, the *macula acustica*.

Saccule (*sacculus*), is a hemispherical sac lodged in the fovea hemispherica. It communicates with the cochlea through a small duct—the canalis reuniens.

The *otoliths,* or *otoconia,* are small masses of crystals of lime carbonate, contained in the inner wall of the utricle and saccule opposite the distribution of the nerves.

Semicircular Canals (*ductus semicirculares*).—These are three membranous tubes corresponding exactly in shape, number and form with the bony canals in which they are contained. They are surrounded everywhere with perilymph, except at the ampullæ, where they are in contact with the bony canals. The inner, or epithelial, layer of the membrane in the ampullæ is covered with columnar ciliated epithelium—*auditory hairs.*

The membranous cochlea begins at the base and ascends in a spiral course within the osseous cochlea to terminate in the cupola. It includes only the canalis cochleæ—a part of the scala vestibulæ. As before stated, the membrana basilaris extends from the margin of the lamina spiralis ossea to the outer wall of the cochlea, dividing the cavity into the two scalæ—the scalæ vestibulæ above, the scalæ tympani below. The former is again subdivided by the membrane of Reissner (*membrana vestibularis* [*Reissneri*]) into two parts, the outer of which forms the *canalis cochleæ,* or *scala media*—the membranous cochlea proper—on the floor of which is the organ of Corti (*organon spirale* [*Cortii*]) covered by the membrana tectoria. The scalæ are lined with periostium and filled with perilymph. The scala tympani ends at the fenestra rotunda, but the scala vestibula communicates freely with the vestibula.

Limbus laminæ spiralis is the periosteal margin of the lamina spiralis ossea, and consists of an upper lip—the *labium vestibulare*—and a lower lip—the *labium tympanicum*—separated by a groove—the *sulcus spiralis.*

Membrana basilaris extends from the labium tympanicum to the outer cochlear wall, to which it is attached by the *ligamentum spirale* of Henle.

Membrane of *Reissner* arises from the middle of the vestibular lamina and passes obliquely at an angle of 40 degrees to the outer cochlear wall, separating the canalis cochleæ from the scala vestibula.

Canalis cochleæ extends as a spiral sac closed at both ends through the osseous cochlea, and contains the most important part of the labyrinth—the ultimate distribution of the auditory nerve in the organ of Corti. It is triangular on section, the membrana basilaris forming the base, the membrane of Riessner the inner side, and the periosteum of the cochlea its outer side.

Membrana tectoria, or *membrane of Corti,* is attached to the vestibular surface of the spiral lamina, in close proximity to

the attachment of the membrane of Reissner, and arches over to the outer cochlear wall, inclosing the organ of Corti, but not in contact with it.

Organ of Corti consists of two sets of pillars—the inner and outer rods of Corti—extending upward upon the vestibular surface of the membrana basilaris, and forming a series of arches. Between the bases of the arches is the *zona arcuata*. There are over three thousand arches, and within them is formed a tunnel extending the entire length of the lamina spiralis terminating at the hamular process.

Inner rods of Corti rest upon the basilar membrane. Their upper extremities resemble the proximal extremity of the ulna, and each has on its inner side a row of epithelial cells—the *inner hair cells*.

Outer rods of Corti are attached in a similar manner at the bases, and their extremities each resemble the head and bill of a swan, the former fitting into the cavity in the inner rods. On the outer side are four rows of ciliated cells—the *outer hair cells*.

Reticular membrane, lamina reticularis or membrane of Kölliker, is a delicate complex network of *phalanges*—fiddle-shaped structures—extending from the inner rods to the external row of the outer hair cells.

The internal auditory canal is a short canal about one-third of an inch in length, extending outward from the meatus auditorius internus (*meatus acusticus internus*), on the posterior surface of the petrous portion of the temporal bone, to terminate at a vertical, perforated plate—the *lamina cribrosa*. This plate is divided by a horizontal ridge—the falciform crest (*crista falciformis*)—into a lower and upper portion. The lower is perforated by numerous foramina for passage of the auditory artery and branches of the auditory nerve, some of which are arranged into a spiral-shaped depression, called the *tractus spiralis foraminosus;* the upper has one large opening—the commencement of the aqueductus Fallopii (*canalis facialis*) for portio dura, or seventh nerve.

Auditory Nerve (*n. acusticus*).—The auditory nerve enters the internal auditory meatus in company with the facial, and at the bottom divides into two branches—the vestibular and cochlear.

Vestibular nerve (*n. vestibularis*) subdivides into three branches, as follows:—

Superior, distributed to the utricle and ampullæ of the superior and external semicircular canals;

Middle, enters the bottom of the fovea hemispherica, and is distributed to the saccule; and the

Inferior is distributed to the ampulla of the posterior simicircular canal.

Cochlear nerve (*n. cochlearis*), ascends in the canals in the modiolus, and divides into numerous branches which pass between the plates of the lamina spiralis ossea, forming a plexus which contains the ganglia spirale (*ganglion spirale*), from which filaments are distributed to the outer and inner hair cells of the organ of Corti.

Arteries of Labyrinth:—

Internal auditory, from the basilar, divides into vestibular and cochlear branches, which accompany the corresponding nerves;

Stylomastoid, from the posterior auricular, enters through the stylomastoid foramen.

THE TONGUE.[1]

The tongue (*lingua*) is the organ of the sense of taste, and lies in the floor of the mouth. It is composed of a mass of muscles, the free surface of which is entirely invested with mucous membrane. It consists of three parts:—

Base, or root (*radix linguæ*), attached to the hyoid bone, the epiglottis and the soft palate;

Body (*corpus linguæ*), the back or dorsum of which is marked by a median line or *raphé,* terminating behind in a cavity—the foramen cecum (*foramen cæcum linguæ* [*Morgagnii*]).

Apex (*apex linguæ*), or tip, narrow and pointed, directed forward.

The mucous membrane (*tunica mucosa linguæ*) resembles skin, consisting of a *corium* or *mucosa,* containing numerous papillæ, and covered with epithelium. The papillæ (*papillæ linguæ*) are most numerous over the anterior two-thirds of the dorsum, and consist of three varieties:—

Circumvallate or papillæ maximæ (*papillæ vallatæ*), the largest, about ten in number, about one-twelfth inch wide, are arranged at the back part of the dorsum like the letter V with the apex directed backward;

Fungiform or papillæ mediæ (*papillæ fungiformes et papillæ lenticulares*), the medium, are scattered over the organ, especially at the tips and sides;

[1] *Vide* Lingual Muscles, page 135.

Filiform, conical or papillæ minimæ (*papillæ conicæ et papillæ filiformes*), the smallest, are distributed over the anterior two-thirds of the dorsum.

Mucous and serous glands and simple papillæ, such as are found in the skin, are also present.

Taste buds, minute, flask-shaped bodies, about one-three-hundredths of an inch in length, are situated in the circumvallate and fungiform papillæ.

Arteries are branches of the lingual, facial and ascending pharyngeal.

1. *Nerves.—Hypoglossal,* the principal motor nerve.

2. *Lingual branch of glossopharyngeal,* the special nerve of taste.

3. *Lingual branch of the trifacial,* to sides and anterior part; nerve of common sensation.

4. *Chorda tympani,* probably nerve of special sense.

5. *Superior laryngeal,* filaments from its internal branch to the base.

THE SKIN AND APPENDAGES.

The skin (*integumentum commune*), besides being the special organ of the sense of touch, is an absorbing and excretory organ, and protects the underlying structures.

It consists of two layers—the epidermis or cuticle, and the derma or true skin. The appendages are the nails, hair, sudoriferous and sebaceous glands, and their ducts.

The *epidermis,* or *cuticle,* is an epithelial structure consisting of four layers:—

1. *Rete Malpighii,* the deepest layer, in contact with the corium, is composed of several layers of round or polyhedral epithelial cells. This layer is pigmented in the negro and other dark races.

2. *Granular layer,* is a single layer of compressed, spindle-shaped cells.

3. *Stratum lucidum,* is still more compressed into scales.

4. *Stratum corneum,* several layers of horny scales.

The *derma,* corium, or true skin, has two layers, the reticular or deeper, and the papillary or superficial.

Reticular layer (*stratum reticulare*) is composed of interlacing bands of white fibrous tissue, mixed with yellow elastic fibers, and some unstriated muscular fibers where hairs are found, together with blood vessels, lymphatics and nerves.

Papillary layer (*stratum papillare*) is covered with minute, vascular, highly sensitive elevations—the papillæ—from one-one-hundredth to one-two-hundred-and-fiftieth of an inch in

diameter. These papillæ are in places arranged into parallel curved ridges, and have in the most sensitive situations some one of the peripheral end organs (already described) added to their structure.

Nails (*ungues*) are horny plaques of modified epidermis, firmly adapted to the derma on the dorsal surfaces of the terminal phalanges. Each nail is firmly implanted by its root (*radix unguis*) into a fold of skin.

The matrix (*matrix unguis*) is the derma beneath the body, which is vascular and highly sensitive.

The *lunula*, on account of its crescentic shape, is the white, less vascular portion of the matrix near the root.

Hairs (*pili*) are a cylindrical modification of the epidermis, and consist of a root imbedded in the skin, a shaft and a point.

Root (*radix pili*) is lodged in a pouch-like involution of epidermis—the hair follicle (*folliculus pili*). This is composed of an inner or cuticular and an outer or dermic layer, and presents at the bottom a vascular papilla, on which the hair rests, and from which it grows.

Shaft (*scapus pili*) consists of a pith or medulla (*substantia medullaris pili*) in the center, surrounded by a fibrous part containing pigment, and covered with a layer of scaly epithelium.

Point contains the two latter elements, but has no medulla.

Sebaceous glands (*glandulæ sebaceæ*) are minute, glandular bodies, situated in the substance of the corium, and each opening by a single duct into a hair follicle, or upon the surface of the skin. They are most abundant where hairs are found. The Meibomian glands in the eyelids are the largest.

Sudoriferous or sweat glands (*glandulæ sudoriferæ*) are minute, reddish, glandular bodies, situated usually in the subcutaneous connective tissue, each consisting of a single convoluted tube. Each gland opens on the surface of the skin.

SURGICAL ANATOMY.

THE TRIANGLES OF THE NECK.

THE general outline of the neck is somewhat quadrilateral. *Bounded* in front by the median line, behind by the trapezius muscle, above by the lower border of the body of the maxilla and below by the clavicle. It is divided by the sternomastoid muscle running obliquely through it into two large triangles, an anterior and a posterior triangle. These are again subdivided by the crossing of the omohyoid muscle into two smaller triangles each. The anterior into the superior and inferior carotid triangles, and the posterior into the occipital and subclavian triangles. The digastric muscle, at the upper part of the anterior triangle, separates a triangular space called the submaxillary triangle.

The *anterior triangle* of the neck is *bounded* as follows:—

Front, median line of the neck;

Behind, anterior border of the sternomastoid muscle;

Above, lower border of the body of the lower jaw and a line from its angle to the mastoid process, forming the base of the triangle;

Below, the top of the sternum, forming the apex.

The *floor* is formed by the sternohyoideus, sternothyriodeus, thyrohyoideus, inferior and middle constrictors of the pharynx, the anterior belly of the digastricus, the mylohyoideus, stylohyoideus, and hyoglossus muscles. The *roof* is formed by the skin, superficial fascia, platysma myoides, and deep fascia.

The *inferior carotid triangle* is the most inferior subdivision of the anterior triangle, and is *bounded* as follows:—

Front, median line of the neck;

Behind, anterior border of the sternomastoideus;

Above, anterior belly of the omohyoideus;

Below, the apex of the anterior triangle.

It *contains* the following structures:—

Thyroid gland and lower part of the trachea and larynx;

Inferior thyroid and common carotid arteries;

Inferior thyroid and internal jugular veins;

Pneumogastric, recurrent laryngeal, descendens noni, communicans noni and sympathetic nerves.

The *superior carotid triangle* is the middle subdivision of the anterior triangle of the neck, and has the following boundaries:—

Above, posterior belly of the digastricus;

Below, anterior belly of the omohyoideus;

Behind, anterior border of the sternomastoideus.

It *contains* the following structures:—

Termination of the common carotid;

The internal carotid;

The external carotid, and the following branches:—

Superior thyroid, lingual, facial, ascending pharyngeal and occipital;

The internal jugular vein, and the following tributaries:—

Lingual, facial, superior thyroid, pharyngeal and occasionally the occipital;

The pneumogastric, superior laryngeal, external laryngeal, descendens noni, spinal accessory, hypoglossal and sympathetic nerves.

The *submaxillary triangle* is the most superior of the subdivisions of the anterior triangle, and has the following boundaries:—

Above, the lower border of the body of the jaw and the imaginary line behind;

In front, the median line of the neck;

Behind, the posterior belly of the digastricus.

It *contains* the following structures:—

External carotid, internal carotid, facial, submental, mylohyoidean arteries;

The internal jugular, the commencement of the external jugular, branches of the anterior jugular and the facial vein and its branches;

The inframaxillary branches of the facial nerve, the ascending branches of the superficial cervical nerve, and the pneumogastric and glossopharyngeal and mylohyoid nerves;

Portions of the parotid and submaxillary glands, and also submaxillary lymphatic glands and vessels.

The *posterior triangle* of the neck occupies the space behind the posterior border of the sternomastoideus, and is *bounded* as follows:—

Front, posterior border of the sternomastoideus;

Behind, anterior border of the trapezius;

Below, upper border of the middle third of the clavicle, forming its base;

Above, the occiput, forming the apex.

Its *floor* is formed from above downward, by the following muscles:—

Splenius capitis, levator anguli scapuli, scalenus medius, scalenus posticus, and the upper portion of the serratus magnus.

Its *roof* is formed by the superficial and deep fascia and below by the platysma myoides.

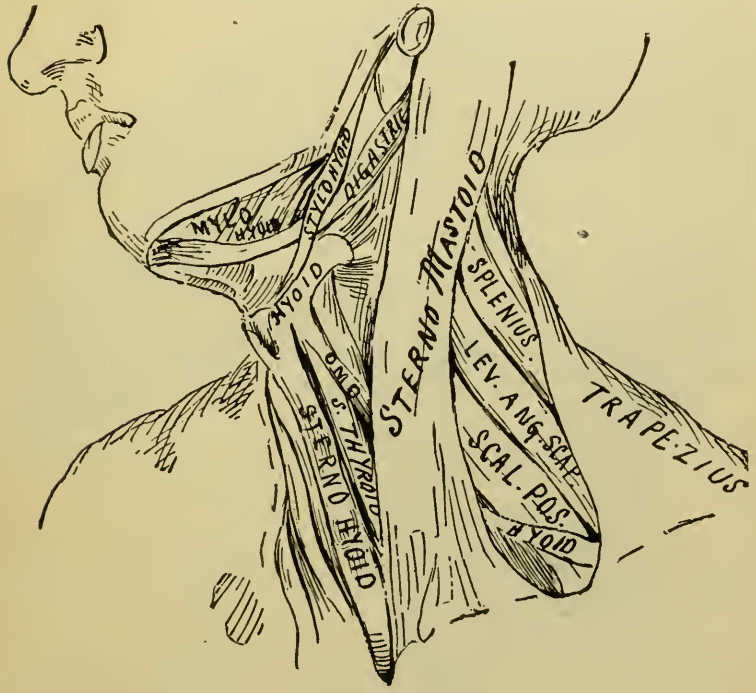

FIG. 139.

Triangles of the neck. (*Boenning.*)

It *contains* the following structures:—

The transversalis colli artery and vein;

Spinal accessory and superficial plexus of the cervical nerve;

Lymphatic glands and vessels.

The *subclavian triangle*, or the inferior division of the posterior triangle, is *bounded*—

In front by the margin of the sternomastoideus, behind by the posterior belly of the omohyoideus, below by the clavicle.

It *contains* the following structures:—

The subclavian, transversalis colli and transversalis humeri or suprascapular arteries;

The transversalis colli, suprascapular and external jugular veins;

The descending branches of the superficial cervical plexus and the brachial plexus of nerves;

Lymphatic nerves and vessels.

Triangle in Front of the Elbow-joint.

Bounded—

Externally, by supinator longus;

Internally, by pronator radii teres;

Base, above, by a line (imaginary) drawn through the condyles;

Apex, below, by crossing of supinator longus and pronator radii teres.

It is *covered in* by skin, superficial fascia and bicipital fascia; the *floor* is formed by oblique fibers of the supinator brevis and lower part of brachialis anticus muscles.

It *contains:*—

From within outward, median nerve, brachial artery, venæ comites, biceps tendon and musculospiral nerve.

Scarpa's Triangle (*trigonum femorale*)

is a large triangular space situated in the upper part of the anterior surface of the thigh, through which the femoral vessels descend. It is *bounded—*

Externally by sartorius, internally by adductor longus, above by Poupart's ligament; below, apex is formed by crossing of bounding muscles.

It is *covered in* by skin, superficial fascia, cribriform fascia and fascia lata, and its *floor* is formed by the following from without inward: iliacus, psoas, pectineus and portion of adductor brevis muscles.

It *contains:*—

The femoral artery (with its profunda and cutaneous branches), inclosed in the femoral sheath, femoral vein (joined by profunda and long saphenous veins), anterior crural nerve and its branches [from within outward being vein, artery and nerve], deep lymphatic glands and vessels and adipose tissue.

Axilla.

This is a pyramidal space between the upper and lateral part of the chest and the inner side of the arm. It is *bounded*—

In front, by the pectoralis major and minor muscles; be-

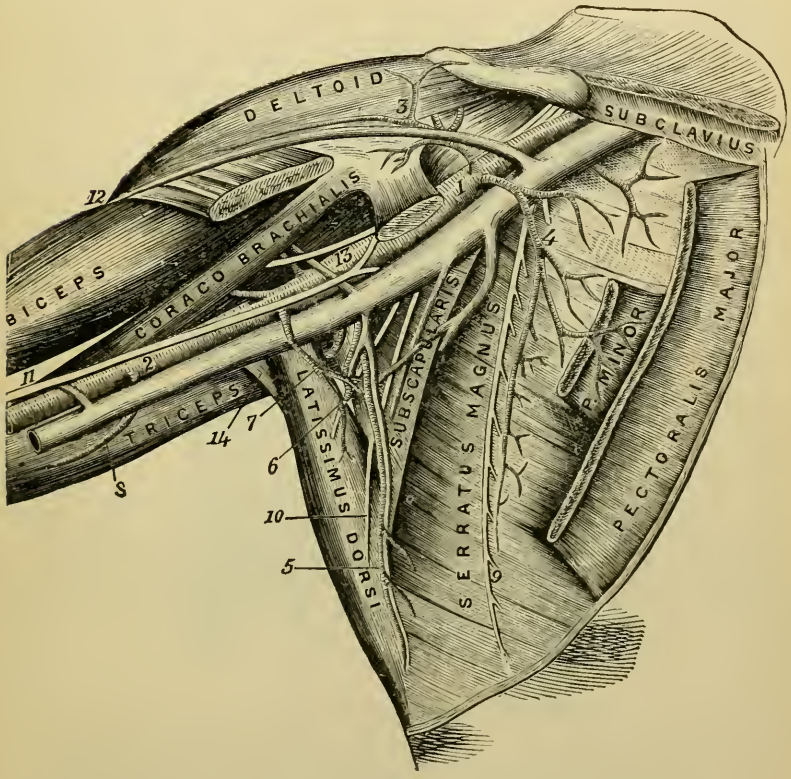

FIG. 140.

The axilla. 1, axillary artery; 2, brachial artery; 3, acromiothoracic artery; 4, superior thoracic artery; 5, subscapular artery; 6, dorsalis scapulæ artery; 7, posterior circumflex atery; 8, superior profunda artery; 9, posterior thoracic nerve; 10, long subscapular nerve; 11, median nerve; 12, cephalic vein; 13, musculocutaneous nerve; 14, teres major muscle. (*Bocnning.*)

hind, by latissimus dorsi, teres major and subscapularis; internally, by the upper four ribs and intercostal and upper part of serratus magnus muscles, and its apex is directed upward, and

is formed by the space between the first rib, clavicle and upper border of the scapula, and its base by the skin and axillary fascia stretched across between the lower borders of the pectoralis major and latissimus dorsi muscles.

It *contains:*—

The axillary artery and vein and their branches; the brachial plexus of nerves and the branches given off below the clavicle; branches of the intercostal nerves; ten or twelve lymphatic glands and a quantity of loose adipose and areolar tissue.

Popliteal Space.

The popliteal space is a lozenge-shaped space situated at the back of the knee, and forms the *ham.* It is *bounded*—

Externally, above the joint, by the biceps; below the joint, by outer head of gastrocnemius and plantaris; internally, above the joint, semitendinosus, semimembranosus, gracilis and sartorius; below the joint, by inner head of the gastrocnemius.

It is *covered in* by the skin, superficial fascia and fascia lata.

Its *floor* is formed by the lower part of the posterior surface of the femur, the ligamentum posticum Winslowi and the popliteus muscle and its fascia.

It *contains:*—

The popliteal artery and branches; popliteal vein receiving the external saphenous vein (vein to the outer side); internal and external popliteal nerves and branches; articular branch of obturator nerve; branch of small sciatic nerve; four or six lymphatic glands and a quantity of adipose and areolar tissue.

ANATOMY OF HERNIA.

Hernia is the protrusion of any part of a viscus from its natural cavity through the inclosing walls of the cavity. As usually understood, it refers to the protrusion of the intestine or mesentery, or both, from the abdominal cavity. The most common forms are:—

External or oblique inguinal hernia;
Internal or direct inguinal hernia;
Femoral hernia;
Umbilical hernia.

1. OBLIQUE INGUINAL HERNIA escapes from abdominal cavity at the internal abdominal ring, carrying before it a pouch

of peritoneum, descends along the inguinal canal in front of the cord, and emerges at the external opening. The anatomical parts concerned are the inguinal canal, with its internal and external abdominal rings, the transversalis fascia (*vide* Fascia), the peritoneum (*vide* Peritoneum) and Poupart's ligament.

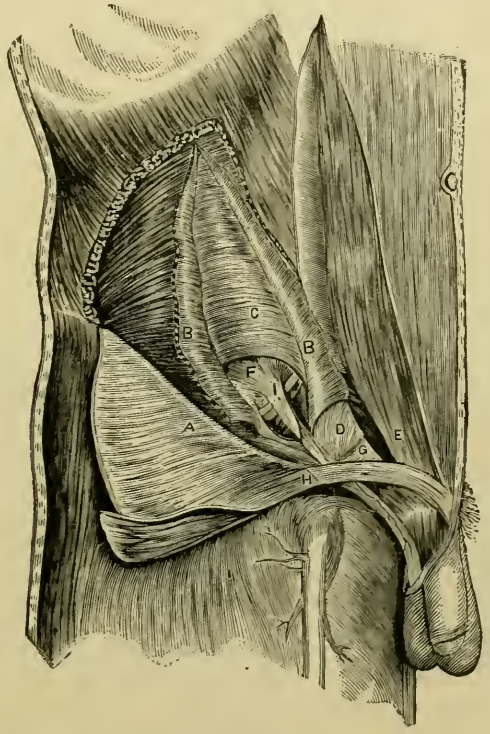

FIG. 141.

Dissection of the inguinal canal: *A*, external oblique; *B*, *B*, internal oblique; *C*, transversalis; *D*, conjoined tendon; *E*, rectus abdominis with sheath opened; *G*, fascia transversalis; *H*, cremaster; *I*, infundibular fascia.

The *inguinal* or *spermatic canal* is about one and a half inches in length, extending from the internal abdominal ring to the external abdominal ring. It serves for the passage of the spermatic cord in the male, and the round ligament with its vessels in the female. Its *boundaries* are:—

In front, skin, superficial fascia, the aponeurosis of the external oblique muscle, the lower border of the internal oblique, and a small portion of the cremaster muscle;

Behind, the fascia transversalis, the conjoined tendon of the transversalis and internal oblique muscles, the transversalis fascia, and subperitoneal fat and peritoneum;

Above, by the arched border of the internal oblique and transversalis muscles;

Below, by the connection between Poupart's ligament and the transversalis fascia.

The internal abdominal ring (*annulus inguinalis abdominalis*) is an oval opening in the transversalis fascia about half an inch above Poupart's ligament, midway between the symphysis pubis and the anterior superior spinous process of the ilium. It is *bounded*—

Above and externally by the arched fibers of the transversalis muscle; below and internally by the deep epigastric vessels.

It transmits a funnel-shaped fascia from its margins, the *infundibuliform fascia.*

The external abdominal ring (*annulus inguinalis subcutaneus*) is a triangular opening between the two pillars in the aponeurosis of the external oblique muscle, to the outer side and just above the spine of the pubes. It is about half an inch wide and one inch long, and is *bounded*—

Above, by the intercolumnar fascia; below, by the spine and crest of the os pubis, and on either side by the pillars or columns of the ring formed by the free margins of the aponeurosis of the external oblique.

From the margins of the external abdominal ring arises the intercolumnar fascia.

Poupart's ligament, or the femoral arch (*ligamentum inguinale*), is the rounded lower fibrous margin of the external oblique muscle, extending between the anterior superior spine of the ilium and the spine of the pubes. The portion of the aponeurosis which is inserted into the pectineal line has received the name of Gimbernat's ligament (*ligamentum lacunare*).

The triangular ligament or ligament of Colles (*ligamentum inguinal reflexum*) is the reflected inner portions of Gimbernat's and Poupart's ligaments attached to the sheath of the rectus.

The epigastric artery (*a. epigastrica inferior*) holds a very important anatomical relation to the inguinal canal and internal abdominal ring. It ascends between the peritoneum and transversalis fascia to reach the sheath of the rectus muscle

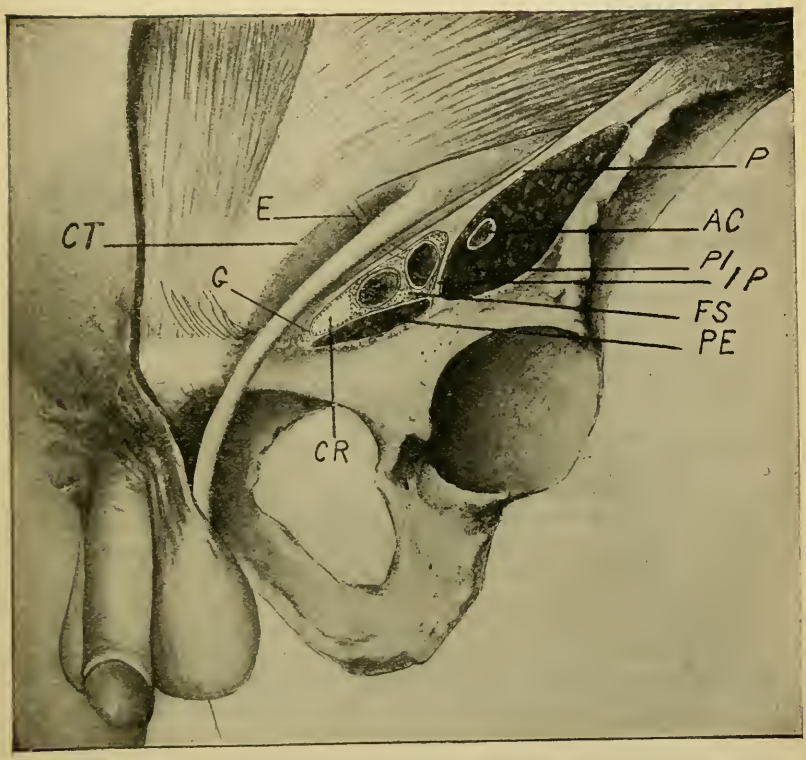

FIG. 142.

Deep Femoral Region—the Femoral Vessels, etc., cut across as they emerge under Poupart's ligament. *AC*, anterior crural nerve; *CT*, edge of the conjoined tendon; *CR*, crural ring; *E*, dotted line indicates the course of the deep epigastric artery; *FS*, femoral sheath; *G*, Gimbernat's ligament; *IP*, ilio-pectineal ligament; *P*, Poupart's ligament; *PE*, pectineus muscle. This muscle rests upon the pubic bone and is covered by its fascia,—the pectineal fascia,—which is somewhat thickened immediately beneath Poupart's ligament, where it is known as the pubic ligament of Cooper. It will be noticed that the femoral sheath is divided into three compartments: the outer for the femoral artery; the middle for the femoral vein; the inner (*CR*) is the crural ring, the mouth of the crural canal. (*McGrath.*)

along the inner and lower margin of the internal ring and beneath the spermatic cord.

The coverings of oblique inguinal hernia are:—

(1) Skin; (2) superficial fascia; (3) intercolumnar fascia; (4) cremaster muscle and fascia; (5) fascia transversalis, or infundibuliform fascia; (6) subserous connective tissue; (7) peritoneal sac.

2. Direct inguinal hernia escapes through the abdominal wall, within Hesselbach's triangle, internal to the epigastric artery, and through the external abdominal ring, pushing before it a pouch of peritoneum.

Hesselbach's triangle is a space situated at the lower anterior part of the abdominal wall on either side. It is bounded as follows:—

Externally, epigastric artery;

Internally, the outer margin of the rectus abdominis muscle;

Below, Poupart's ligament, forming its base. The structures forming the abdominal wall at this cavity are, from without inward:—

1. Skin;
2. Superficial fascia;
3. Intercolumnar fascia;
4. Conjoined tendon of the transversalis and internal oblique;
5. Fascia transversalis;
6. Subserous tissue;
7. Peritoneum.

The anatomical parts concerned in direct inguinal hernia are the same as those in the indirect, already given. The coverings of direct inguinal hernia are those just enumerated.

3. Femoral hernia escapes through the femoral ring, carrying before it a pouch of peritoneum, descends through the femoral canal and emerges through the saphenous opening in the fascia lata. The anatomical parts concerned in this hernia are:—

The femoral ring, the femoral or crural canal, the septum crurale, crural sheath, deep crural arch and the saphenous opening.

The femoral, or crural ring (*annulus femoralis*), is an oval opening, about an inch and a half in diameter, larger in the female and situated below Poupart's ligament, between the inner side of the femoral vein and the margin of Gimbernat's ligament. It is the abdominal opening of the femoral canal

(*canalis femoralis*), and it is closed in the recent state by the septum crurale and a small lymphatic gland. It is *bounded*—

In front, by the deep femoral arch and Poupart's ligament;

Behind, by the pubes, covered by the pubic portion of the fascia lata and the pectineus muscle;

Externally, by the femoral vein, from which it is separated by a fibrous septum;

Internally, by the deep femoral arch, Gimbernat's ligament, the transversalis fascia and the conjoined tendon.

The femoral canal (*canalis femoralis*) is a space from a quarter to half an inch in length, extending from Gimbernat's ligament to the upper margin of the saphenous opening. Bounded above by the femoral ring and below by the saphenous opening. It is the innermost compartment of the femoral sheath.

Anterior wall—transversalis fascia, separated by the falciform process (*margo falciformis*) of the fascia lata;

Posterior wall—iliac fascia and pubic portion of the fascia lata;

External wall—fibrous septum of the femoral vein;

Internal wall—Gimbernat's ligament, deep crural arch and the junction of the iliac and tranversalis fascia.

The septum crurale (*septum femorale musculus*) is a layer of dense areolar tissue, supporting small lymphatic glands and closing in the femoral ring. It is perforated by numerous lymphatic vessels, and forms a barrier to the escape of hernia at this point.

The crural or femoral sheath (*fascia cruris*) is a prolongation downward of the fascia lining the abdomen (transversalis fascia in front, iliac fascia behind the vessels), closely adhering to the femoral vessels to about an inch below the saphenous opening (*fossa ovalis*). Its upper part is funnel-shaped and its lower part continuous with the sheath of the vessel. It is divided by septa into three compartments; in the outer is lodged the femoral artery; the middle is occupied by the femoral vein; and the innermost, the *femoral canal,* is empty, or occupied by a lymphatic gland. Its outer border is pierced by the genito-crural nerve, its inner by the internal saphenous vein.

The *deep femoral arch* is a fibrous thickening of the transversalis fascia which forms the anterior wall of the femoral sheath. It is also known as the deep crural arch.

The *saphenous opening* is an oval aperture of half an inch in width, an inch and a half in length in the upper and inner part of the fascia lata, between its two divisions, the iliac and

pubic portions. It is bounded externally by the falciform process of Burns, internally by the pubic portion of the fascia lata, which curves upward behind the saphenous vein. The opening is covered externally by the cribriform fascia (*fascia cribrosa*) and the skin.

The coverings of femoral hernia are:—

1. Skin;
2. Superficial fascia;
3. Cribriform fascia;

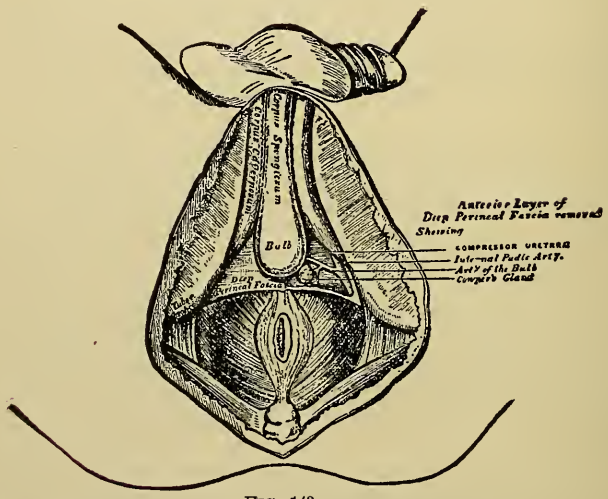

FIG. 143.

Male perineum, superficial dissection. (*Lydston.*)

4. Femoral sheath, crural sheath, or fascia propria;
5. Septum crurale;
6. Subserous connective tissue;
7. Peritoneal sac.

ISCHIORECTAL REGION AND PERINEUM.

The outlet of the pelvis is a lozenge-shaped space divided by an imaginary line drawn in front of the anus, transversely between the anterior margin of the tuber ischii, into two parts, the ischiorectal region behind and the perineum in front.

The *ischiorectal region* contains the external (*m. sphincter ani externus*) and internal sphincters (*m. sphincter ani inter-*

nus), the corrugator cutis ani and the ischiorectal fossa (*fossa ischiorectalis*). The latter is a pyramidal cavity, its apex reaching to the junction of the obturator and anal fascia and its base formed by the skin. It is *bounded*—.

Behind, by the edge of the great sacrosciatic ligament and gluteus maximus muscle; internally, by the levator ani, covered by the anal fascia, sphincter ani and coccygeus muscle; externally, by the tuber ischii and obturator fascia.

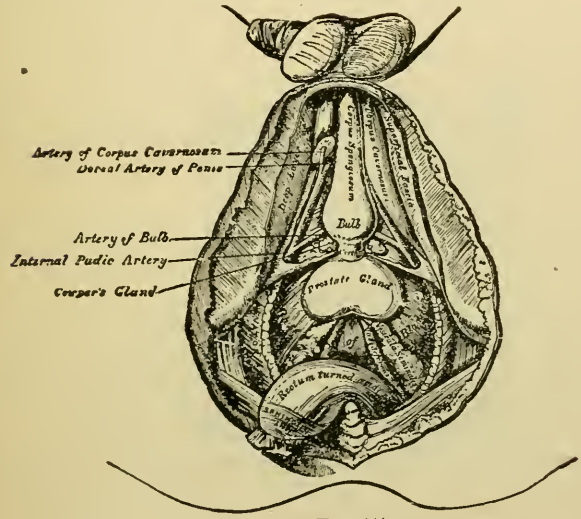

FIG. 144.

Male perineum, deep dissection. (*Lydston.*)

It *contains*:—

The internal pudic artery, nerve and veins inclosed in the fascial canal or canal of Alcock;

The inferior hemorrhoidal vessels and nerves;

The perineal and fourth sacral nerves; and

A mass of areolar tissue.

PERINEUM.

The perineum is the triangular space between the anus and scrotum in the male, and between the anus and vulva in the female. The skin is dark, thin, and supplied with sebaceous and sudoriferous glands and is marked by middle line or *raphé*.

Fasciæ of the Perineum.

The pelvic fascia (*fascia pelvis*) at the brim of the pelvis is continuous with the transverse and iliac fascia; covers sacrum, pyriformis muscle, external iliac artery and sacral nerves. It forms the lateral true ligaments of the bladder (*ligamenta puboprostatica lateralia*) in the male, and (*ligamenta pubovesicalia lateralia*) in the female. It also forms the anterior true ligament of the bladder (*ligamentum puboprostaticum medium*) in the male (*ligamentum pubovesicale medium*) in the female. It forms arcus tendineæ (*arcus tendineus fasciæ pelvis*), or white line, corresponding to division of pelvic fascia into two layers, the obturator and rectovesical (*fascia diaphragmatis pelvis superior*), extending from pubis to spine of ischium, from which originates the levator ani muscle, with rectovesical and ischiorectal or anal fasciæ above and below the muscle respectively.

The obturator fascia (*fascia obturatoria*), the continuation of the pelvic fascia, incloses the pudic vessels and nerve in a sheath, covers the internal obturator muscle and forms the posterior layer of the triangular ligament.

Rectovesical or *visceral layer* of the *pelvic fascia,* the continuation of the pelvic fascia, descends into the pelvis investing the prostate gland and the vesicoprostatic plexus of veins, the bladder (forming the anterior and lateral true ligaments) and the rectum. It is perforated in the female by the vagina.

Superficial perineal fascia (*fascia superficialis perinei*) consists of superficial fat layer and deep membranous layer, the fascia of Colles. The former is continuous with subcutaneous layer of buttocks, thigh, and labia, and posterior to anus become continuous with tissue of ischiorectal fossa. The *superior layer* passes from rami of pubis and ischium to the tuberosity of ischia, covering ischiocavernous and bulbourethral muscles, and becomes continuous with the deep perineal fascia.

The deep perineal fascia (triangular ligament of the perineum—*trigonum urogenitale* or *diaphragma urogenitale*) is a strong triangular membrane extending between the rami ischii et pubis, its apex attached to the under surface of the symphysis. It is often described as consisting of two layers, the superior, deep or posterior layer (*fascia trigoni urogenitalis superior*), and inferior, anterior or superficial layer (*fascia trigoni urogenitalis inferior*). It is pierced by the membranous urethra, and sends a fascia surrounding the urethral glands to the spongy body. In the female it is weaker, the urethra also pierces it, and it is continuous with the fascia of the vagina.

Muscles of the Perineum.

Ischiocavernosus (erector penis) arises in the inner surface of the tuberosity of the ischium, and is inserted into the side and under surface of the crus penis. In the female there is a similar insertion into the clitoris. It serves to maintain the organ erect. *Nerve,* perineal.

Erector clitoridis (*m. ischiocavernosus*) corresponds to erector penis muscle in the male, but smaller.

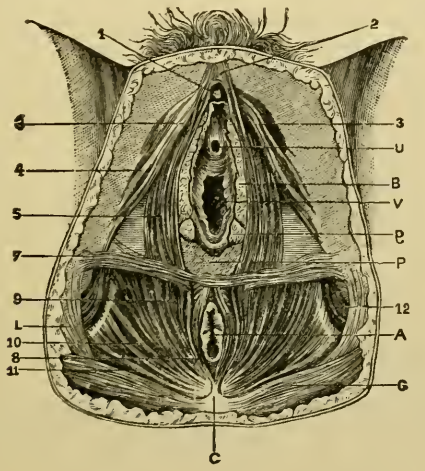

Fig. 145.

Female perineum: *A*, anus; *B*, bulbo-vaginal; *C*, coccyx; *G*, gluteus maximus; *P*, perineal body; *U*, urethra; *V*, vagina; *G*, vulvo-vaginal gland; 1, clitoris; 2, its suspensory ligament; 3, crura clitoridis; 4, erector clitoridis; 5, bulbo-cavernosus; 7, transversus perinæi; 8, sphincter ani; 9 and 10, levator ani; 11, coccygeus; 12, obturator externus.

Accelerator urinæ or ejaculator seminis (*m. bulbo-cavernosus*) arises from central tendon of perineum and from median *raphé* in front. It spreads out and is inserted from behind forward to anterior surface of triangular ligament, bulb and adjacent part of corpus spongiosum, to join fibers of opposite side, and to sides of corpora cavernosa; anterior to erector penis and in fibrous expansion over dorsal blood vessels of penis.

It accelerates the flow of urine and semen and contributes to erection of the penis. *Nerve,* perineal.

Vaginal constrictor or sphincter vaginæ (*m. bulbocavernosus*), analogous to foregoing muscle, surrounds the orifice of vagina. It arises from the central tendon and passes forward on either side of vagina to be inserted into the corpora cavernosa and body of clitoris. It compresses the dorsal vein of the clitoris.

Transversus perinæi (*superficialis*) arises from inner part of ramus of ischium, and is inserted into perineal center in male, into the side of sphincter vaginæ in the female. It steadies the perineal center. *Nerve,* perineal.

Compressor urethræ (*m. constrictor urethræ*) arises from the rami of pubis and ischium, passes inward and with its fellow of the other side, unites above and below the urethra, surrounding it from the bulbous portion to the prostate gland in the male. In the female it is inserted into the vaginal walls.

External sphincter ani (*m. sphincter ani externus*) muscle arises from the apex of the coccyx and the superficial fascia, and is inserted into the perineal center, blending with the levator ani, accelerator urinæ and transversus perinæi. It closes the anus. *Nerve,* fourth sacral.

Internal sphincter ani (*m. sphincter ani internus*) is an aggregation of circular fibers of the intestine, forming a muscular ring one inch in breadth, surrounding the lower portion of the rectum.

The external sphincter ani, the two bulbocavernosi and the two transversus perinæi unite one-half inch in front of the anus in the median line in the so-called *central tendon of the perineum.*

Anal elevator (*levator ani*) arises in front from body and ramus of pubis and symphysis, posteriorly from spine of ischium, and on either side from angle of *arcus tendineæ* (white line). It is inserted by posterior fibers into coccyx, and anterior fibers into the muscle of opposite side in a median *raphé* extending from coccyx to anus; middle fibers into rectum, joining with sphincter; anterior to prostate, blending with external sphincter and transverse fascia. In the female it is inserted into the vagina instead of the prostate.

It helps with its fellow to form the floor of the pelvis, and supports the vagina, rectum and pelvic viscera. *Nerves,* inferior hemorrhoidal and fourth sacral.

Coccygeus muscle (*coccygei*), from the spine of the ischium and lesser sacrosciatic ligament, and is inserted into the margin of coccyx and side of lower two segments of sacrum.

It raises the coccyx and forms the posterior part of the pelvic floor. *Nerve,* anterior division of the fourth and fifth sacral.

The muscles of the female perineum are:—

Superficial Set.

Sphincter vaginæ, or bulbocavernosus;
Erector clitoridis;
Transversus perinæi superficial;
Sphincter ani;
Levator ani;
Coccygeus.

Deep Set.

Transversus perinæi (profundus);
Constrictor vaginæ;
Compressor urethræ.

The structures beneath the deep layer of the superficial fascia are:—

Erector penis muscle;
Accelerator urinæ muscle;
Transversus perinæi muscle and arteries;
Superficial perineal vessels.

The structures between the two layers of the deep perineal fascia are:—

Compressor urethræ muscle;
Membranous urethra;
Subpubic ligament;
Dorsal vein of penis;
Pudic vessels and nerves;
Venous plexus;
Cowper's glands and ducts;
Arteries and nerves of bulb.

ANATOMY OF LATERAL LITHOTOMY.

The incision is made through a triangular interval formed by the transversus perinæi, accelerator urinæ and erector penis muscles, and divides the following structures in the order named:—

Skin and superficial fascia;
Inferior hemorrhoidal vessels and nerves;
Accelerator urinæ muscle;
Superficial perineal vessels and nerve (sometimes);

Transversus perinæi artery and muscle;
Deep perineal fascia;
Anterior part of levator ani;
Part of compressor urethræ and accelerator urinæ muscles;
Membranous and prostatic portions of urethra;
Left lobe of prostate gland.
The structures to be avoided are:—
In median line, rectum and bulb of corpus spongiosum;
Externally, internal pudic artery;
Forward, artery of the bulb;
Backward, posterior part of prostatic gland and neck of the bladder.

DENTAL ANATOMY.

Embryologically the oral cavity is formed by the first visceral and the frontonasal process. *The first arch* distad branches dichotomously. The superior arm is the maxillary process, the inferior arm the mandibular process. The latter joins with its fellow of the opposite side in the midline (*symphysis mandibularis*) to form the lower jaw. Between the right

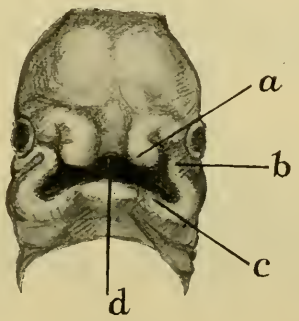

Fig. 146.

Maxillary and mandibular process of first visceral arch and frontonasal process. *a*, frontonasal process; *b*, superior arm (maxillary process) of first arch; *c*, inferior arm (mandibular process) of first arch; *d*, primitive oral cavity.

and left maxillary processes is interpolated the frontonasal process. This marks a place of weakness, pathologically indicated by congenital cleft palate and harelip.

The bony framework of the adult oral cavity consists of the hard palate above and the mandible (Fig. 148) and hyoid (Fig. 25) bones below. The bones entering into the formation of the hard palate, from before backward, are: (1) two premaxillaries (distinguishable only in very young specimens), (2) two maxillaries, and (3) two palate bones. The hard palate presents four sutures: (1) median, (2) premaxillary-maxillary (poorly marked in the adult), (3) maxillary-palatine, and (4) palatine-sphenoid. The foramina of the hard palate are: (1) anterior palatine, at the point where the premaxillary-maxillary

suture crosses the median, subdivided into four openings, (2) two posterior palatine, and (3) two accessory. These last four foramina transmit the posterior descending palatine nerves and vessels.

The alveolar process for the implantation of the teeth is a ridge of bone superimposed peripherally, in the upper jaw, upon the premaxillary and maxillary bones. When fully functioning it is not demarcated from these bones, but before the teeth come and after they go it does not exist. Its body is spongy. Its cortex is dense, and surrounding each tooth root-socket it is somewhat condensed (*lamina dura*, of some significance radiographically for the prognosis of pyorrhea alveolaris). In cross-section

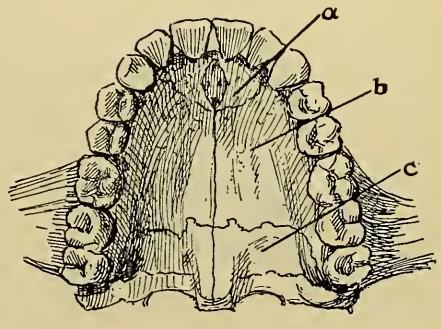

FIG. 147.

Sutures of the hard palate. *a*, premaxillary bone; *b*, maxillary bone; *c*, palatine bone.

it is somewhat U-shaped. It has two free surfaces, the internal and external alveolar plates. Of these the external is much the thinner, which fact is taken advantage of in extraction.

The mandible (Fig. 148) exhibits an alveolar process essentially similar to that of the maxillary. In cross-section the mandible is U-shaped. The cortex is dense, the interior cancellated. Within its body runs the inferior dental nerve and blood-vessels inclosed in a *cribriform tube* in close proximity to the roots of the teeth. In most cases the mental canal points forward into the body of the bone, and hence it is a recurrent canal. There are two foramina in the mandible: (1) *inferior dental*, situated in the midvertical axis of the ramus at the intersection of a line continuous with the free edge of the alveolar process; (2) *mental*, situated about in the midhorizontal line of the body at the intersection of a vertical line dropped from the second

premolar or between the first and second premolars. The mental foramen marks one of the favorite lines of fracture of the mandible.

Over this bony scaffolding the soft tissues of the mouth are molded. The hard palate is covered by a mucoperiosteum. Its pitted surface is due to many small mucous glands which it shelters. The gums covering the alveolar processes are also of a mucoperiosteal nature. Normally between the teeth is a little cushion of gum-tissue, serving to keep out food *débris*. Around each tooth the gum is attached at the neck (enamel-cementum

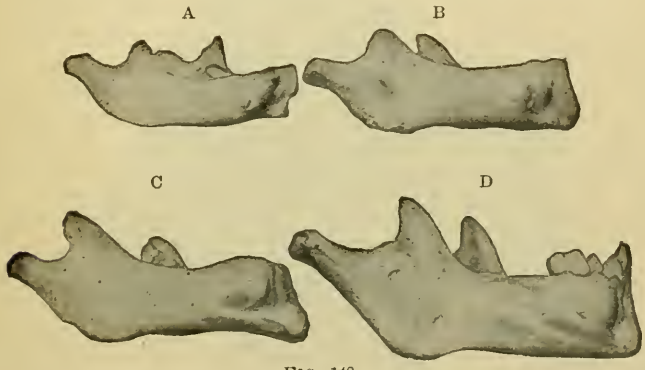

FIG. 148.

Four mandibles ranging from birth to eighteen months. *A*, at birth; *B*, at three months; *C*, at six months; *D*, at eighteen months. ("Internal Anatomy of the Face," *M. H. Cryer, M.D., D.D.S.*)

junction), but a little free edge exists leaving around each tooth a *gingival trough*.

The soft tissues over the anterior part of the hard palate and the palatine side of the alveolar ridge is raised into a number of transverse ridges (rugæ), and, in the midline, an incisal pad.

The soft palate is a backward continuation of the soft tissues covering the hard palate, inclosing in their substance muscle fibers. The anterior pillars of the fauces arbitrarily mark the posterior limit of the oral cavity. In their substance run the palatoglossus muscles.

Laterally and anteriorly the cheeks and lips form the walls of the oral cavity. The slit between the external alveolar plate and teeth on the one side, and the cheeks and lips on the other is known as the *preoral cavity* or *vestibule*. The *frenum labii* is

a delicate fold of tissue in the midline between the gum of the external alveolar plate and the upper lip. In artificial dentures room has to be provided for its free movement.

The body of the cheeks and lips is composed of the muscles of expression (Fig. 149). Internally they are covered by mucosa, externally by the skin.

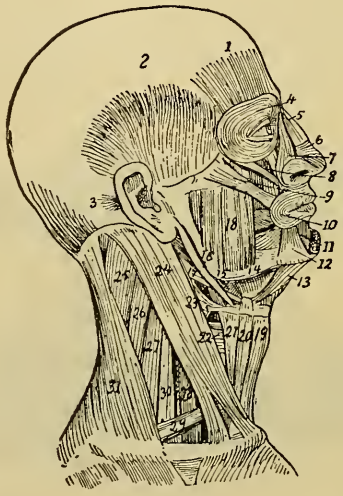

FIG. 149.

Muscles of expression. Muscles of the right side of the head and neck. 1, frontalis; 2, superior auricular; 3, posterior auricular; 4, orbicularis palpebarum; 5, pyramidalis nasi; 6, compressor naris; 7, levator labii superioris, alæque nasi; 8, levator labii superioris; 9, zygomaticus major; 10, orbicularis oris; 11, depressor labii inferioris; 12, depressor anguli oris; 13, anterior belly of digestric; 14, mylohyoid; 15, hyoglossus; 16, stylohyoid; 17, posterior belly of digastric; 18, masseter; 19, sternohyoid; 20, anterior belly of omohyoid; 21, thyrohyoid; 22, 23, lower and middle constrictors of the pharynx; 24, sternomastoid; 25, 26, splenius; 27, levator scapulæ; 28, anterior scalenus; 29, posterior belly of omohyoid; 30, middle and posterior scalenus; 31, trapezius. ("Applied Anatomy and Oral Surgery," *Robert H. Ivy.*)

The anterior orifice of the oral cavity (rima oris) is a transverse slit bounded by the projecting lips. The orbicularis oris (page 132) has no separate existence. The sphincter action of the lips is accomplished by a complicated interlacing of the muscle fibers from buccinator, depressor labii inferioris, depressor anguli oris, zygomaticus and risorius. The buccinator forms the muscular body of the cheek. Its attachment to the maxilla has to be considered in outlining upper artificial dentures.

The masseter, temporal, external and internal pterygoids all innervated by the fifth nerve, are the "muscles of mastication" (pages 132 and 133). Between the right and left halves of the body of the mandible is the muscular floor of the mouth—digastric, geniohyoid and mylohyoid (page 134).

The floor of the oral cavity presents the tongue, with its frenum; on each side of this an elevation indicating the position of the sublingual glands, and anteriorly to the frenum, a papilla for the orifices of the sublingual and submaxillary ducts. For the description of the tongue see pages 135 and 388.

For the salivary glands see pages 229-230.

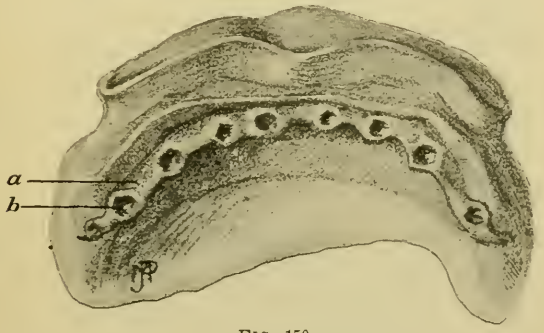

FIG. 150.

Tooth development. *a*, dental ledge or lamina; *b*, tooth germs of deciduous teeth.

For the temporomandibular articulation see pages 105 and 106.

The cranial nerves of direct interest for the dentist are fifth nerve, seventh nerve, ninth nerve and twelfth nerve. (See pages 311-316 and Figs. 116 and 117). Especially fifth and seventh nerves must be thoroughly mastered. (Chart facing page 422.)

The external carotid artery (pages 180-185 and Figs. 79 and 81) is the most important artery for the dentist. See also table on pages 200-204. For the venous system of special interest to the dentist see pages 210-213.

The nasal cavity and its accessory sinuses not infrequently have relations of dental interest (Figs. 125, 126 and 127 and pages 355 and 356). The relations of the roots of the upper second premolar, first and second molars to the floor of the maxillary sinus (antrum of Highmore) is very intimate and

important. The roots of the two last-named teeth always indent the floor of this sinus.

The mandible is raised by the masseter, temporal, external and internal pterygoids; depressed by the anterior belly of the digastric and geniohyoid when the hyoid bone is fixed; protruded by external and internal pterygoids as well as slightly by the

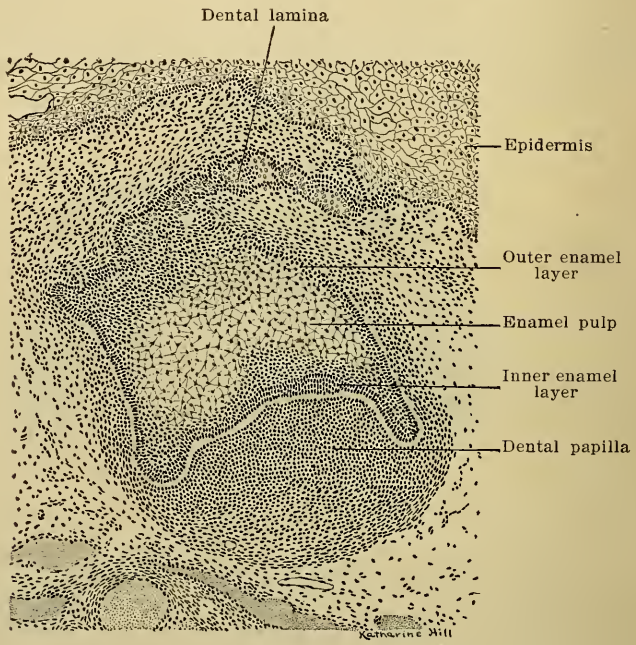

FIG. 151.

Tooth development. ("A Laboratory Manual and Textbook of Embryology." *Prentiss.*)

superior portion of the masseter; retracted by the posterior fibers of the temporal; and rotated by the fixation of one external pterygoid with synchronous contraction of the other (the internal pterygoid assists in rotation).

The teeth are inserted by a gomphosis joint in the alveolar processes of the lower and upper jaws. In man there is a deciduous and a permanent set. There are twenty deciduous teeth; five in each quarter of the jaw apparatus: 2 incisors, 1 canine and 2 molars (Fig. 86, page 226).

There are thirty-two permanent teeth; eight in each quarter of the jaw apparatus: 2 incisors, 1 canine, 2 premolars, 3 molars (Fig. 87, page 227).

The human tooth presents a crown and a root. The crown is outside of the gum, and is covered with enamel. The root is for the insertion of the tooth, and is covered with cementum. At the junction of the crown and root is a constriction, the neck or cervix. The body of the tooth is formed of dentine. Within the dentine is the pulp which in the crown is contained in a relatively large chamber, sending out cornua roughly corresponding to the cusps of the tooth; in the root the pulp is restricted to the narrow canal terminating outwardly at the root apex through one or several foramina.

In the seventh fetal week the oral epithelium thickens along a line roughly corresponding to the future dental arch, protruding into the underlying jaw-mesenchyme. In each jaw at ten points in this dental ledge, on its deep free edge, localized thickenings become noticeable. These are the first signs of the tooth-germs of the deciduous teeth. Each of these knobs becomes invaginated, the cavity filled with vascular mesenchymal tissue, the dental papilla. By progressive development the part derived from the oral epithelium becomes the enamel-organ of the future tooth. From the enamel-organ are formed enamel and Nasmyth's membrane; from the dental papilla, dentine and pulp. The dental ledge connecting the tooth-germs with the oral epithelium becomes fenestrated and eventually disappears.

Linguad and distad to each of the deciduous tooth-germs arises, from the same dental ledge, the enamel-organ of the corresponding permanent tooth. The three permanent molars are derived from a free prolongation of the dental band, extending distad to the second deciduous molar.

Eruption of Deciduous Teeth.

Mandibular first incisors	6	to	8	months.
Maxillary first and second incisors	8	"	10	"
Mandibular second incisors; Maxillary and mandibular first molars	12	"	14	"
" " " canines	18	"	20	"
" " " second molars	28	"	32	"

Eruption of Permanent Teeth.

Maxillary	and	mandibular	first molars	6	years.
"	"	"	" incisors	7	"
"	"	"	second incisors.....	8	"
"	"	"	first premolars	9	"
"	"	"	second premolars ...	10	"
"	"	"	canines	11	"
"	"	"	second molars	12	"
"	"	"	third molars	17-25	"

HISTOGENESIS OF THE DENTAL TISSUES.

Enamel.—A delicate cuticular zone appears at the inner end of the ameloblast. This, with its fellows of adjoining cells, becomes differentiated into rod-like segments (enamel-processes or processes of Tomes) : these develop into the enamel prisms and interprismatic substance. The enamel-processes gradually become calcified by the deposition of granules and spherules, first appearing in the axis of the prism and later extending to its periphery. These spherules are, in chemical nature, calcoglobulin; and morphologically, are known as calcospherites. The same ameloblasts suffice for the deposition of the entire mass of enamel. This is formed from within outward, *i.e.,* in the reversed direction followed by the growth of dentin. It is as yet undecided whether enamel is a secretion or a conversion of the ameloblasts, but the balance of opinion would seem to be in favor of the latter view.

Dentin.—In the formation of dentin the odontoblasts play much the same rôle that is played by the osteoblasts in producing the matrix of bone. A thin homogeneous layer—*membrana præformativa*—overlying the odontoblasts is the earliest trace. This, however, is only part of the general dentinal ground-substance—matrix—which for a time is without fibrous structure and uncalcified.

Hopewell-Smith does not agree with the above description, which is the one generally accepted. According to him the classical "odontoblasts" have nothing to do with the formation of dentin-matrix, which is formed by a calcification proceeding from certain cells of the pulp. The walls and contents of the tubuli are manufactured probably by the classical "odontoblasts."

Cementum.—This is a product of the osteoblasts (cementoblasts) of the periodontal (alveolo-dental) ligament. The process is almost identical with the development of subperiosteal bone. Cementum is distinguished by the unusual number of

transversely placed bundles of fibrillæ—or Sharpey's fibers. Many of these are imperfectly calcified. The cementum appears first in the vicinity of the neck of the tooth and advances towards the apex of the root as the radicular dentin is layed down.

The knowledge of root-formation is important. The extent of root-growth at various ages is graphically illustrated by Fig. 152.

The dental tissues are: (1) Nasmyth's membrane, (2) enamel, (3) dentine, (4) cementum, (5) pulp. Nasmyth's membrane is a pellicle 9 to 18μ thick) covering the enamel, long persisting, of high organic content, resistant to the action of acids. It is two-layered: (1) outer, of cornified remnants of enamel-organ; (2) inner, structureless, consisting of the last

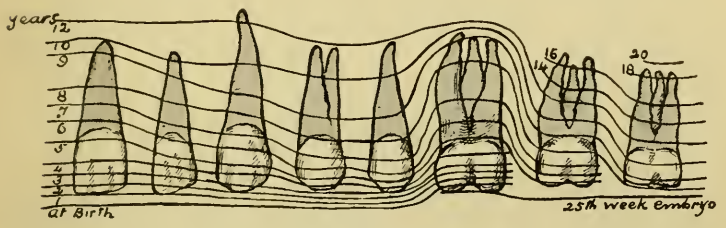

FIG. 152.

Root growth.

formed, imperfectly calcified portion of the enamel-prisms. The enamel is the hardest tissue of the human body (containing 97 per cent. of inorganic salts). It consists of prisms (3.4-4.5μ in diameter) running approximately at right angles to the external surface of the tooth, in a slightly spiral course to the dentine. Between these prisms is a cementing substance. In the outer portions of the enamel, intercalated or accessory prisms have been described. The margin of each enamel-rod is straight and smooth, but may optically appear varicose, due to the beaded nature of its more highly calcified central portion. The brown striæ of Retzius are pigment zones running in the general direction of the contour of the tooth. The prism-stripes of Schreger are alternate dark and light bands at right angles to the striæ of Retzius in the enamel, cut in axial longitudinal section and examined by reflected light.

The dentine contains about 72 per cent. of inorganic salts. Its histologic character is principaly due to the dentinal tubuli

(1.3-2μ in diameter), which, running sinuously from the pulp to the enamel, contain the dentinal fibers, the odontoblastic processes. These tubuli branch and anastomose, some of them ending in the enamel in the form of enamel-spindles. The sheath of Newman is a delicate membranous wall of the dentinal tubule. The dentinal substance between the tubuli is similar to the matrix of bone. Imperfections in the calcification of the dentine are indicated by the interglobular spaces and contour lines of Owen in the coronal portion, and the granular layer of Tomes at the dentine-cementum junction in the root portion. Schreger's lines in the dentine "are merely markings, which, running parallel to the external edge of dentine, are produced by the coincidence of primary curvatures of the tubules."

The cementum is usually described as being composed of relatively amorphous concentric lamellae with lacunae. There is, however, good authority (Hopewell-Smith) for considering the lacunae indicative of some pathological process. The cementum increases in thickness from the gum-margin to the root-apex and also with age. The relation between the enamel and cementum is variable; in most cases these two tissues just touch each other.

The pulp shows connective tissue of an embryonal type. There are very few or no elastic fibers in it. Its nerve- and blood-supply is abundant. Lymphatics are generally denied, but recent work indicates their presence. The peripheral cells are differentiated into a more or less stratified columnar elements, the odontoblasts, which send their processes into the dentinal tubuli. The nerves accompany the blood-vessels and from a peripheral plexus beneath the odontoblasts, sending fibrillae between these cells. Any further extension of these nerves, *e.g.,* into dentine, has as yet not been proved.

The periodontal ligament is a collection of fibrous tissue stretching from the dentine to the lamina dura of the alveolar socket. The arrangement of the fibers is adjusted in general to meet the strain of occlusion. This ligament is normally, in youth, relatively thick in diameter, decreasing with age and pathological conditions. It contains cell-nests or "rests," remnants of the epithelial sheath of Hertwig, once described as glands.

The deciduous teeth (Fig. 86, page 226) are smaller than, and show a more marked cevical construction than, the permanent teeth. Also the roots of the milk-molars exhibit a more marked flaring. The first and second deciduous incisors resemble in close detail the corresponding permanent teeth. The

second milk-molar bears a great resemblance to the first permanent molar. The occlusal surface of the maxillary (upper) first deciduous molar is irregularly quadrangular in outline, and presents three cusps; two buccally and one lingually. It has three roots. The occlusal surface of the mandibular (lower) first deciduous molar is quadritubercular (two buccal and two lingual cusps). It has two roots, one mesial, one distal.

The Permanent Teeth.

Maxillary first (central) incisor, chisel-shaped; labial surface somewhat convex; lingual, concave; incisal edge curves over into distal surface; incisal-mesial angle sharp; root conical. Implanted in premaxillary bone (Fig. 87, page 227).

Maxillary second (lateral) incisor closely resembles upper first incisor. It is about two-thirds the size of this latter tooth. Implanted in premaxillary bone.

Maxillary canine; convex labial surface presents a cutting edge with a mesial and a distal slant; latter the longer; lingual surface almost flat or slightly convex; near gingival border is a small protuberance or cingulum; root longest in human mouth, irregularly conical in shape, tapering from neck to apex.

Maxillary first premolar; bicuspid crown (one lingual, one buccal cusp); latter the larger; buccal surface presents a free margin with mesial and distal slant, former generally the longer; root generally flattened and grooved on its mesial and distal sides, or separated into a buccal and a lingual root (Fig. 153).

Maxillary second premolar; closely resembles above tooth; slightly smaller; its crown is lower; distal slant on free margin of its buccal surface slightly the longer; root slightly the longer, rarely divided, much flattened mesiodistally.

Maxillary first molar; occlusal surface irregular rhombic in outline with four cusps (two buccal, two lingual); mesiobuccal cusp largest; distolingual cusp distinctly marked off from the other cusps by a deep groove; three roots (1) mesial or mesiobuccal, (2) distal or distobuccal, (3) lingual; (3) largest, conical in form, circular in cross-section; mesial root larger than distal, oval in cross-section, with buccolingual axis the longer; distal root also has the same cross-section (Fig. 154).

Maxillary second molar; smaller than above tooth; otherwise great similarity; distolingual cusp noticeably reduced; three roots, closely resembling those of above tooth.

Maxillary third molar; same structural form as the two above teeth, but many variations; cusps more poorly marked; distolingual cusp often absent; smallest tooth of the molar

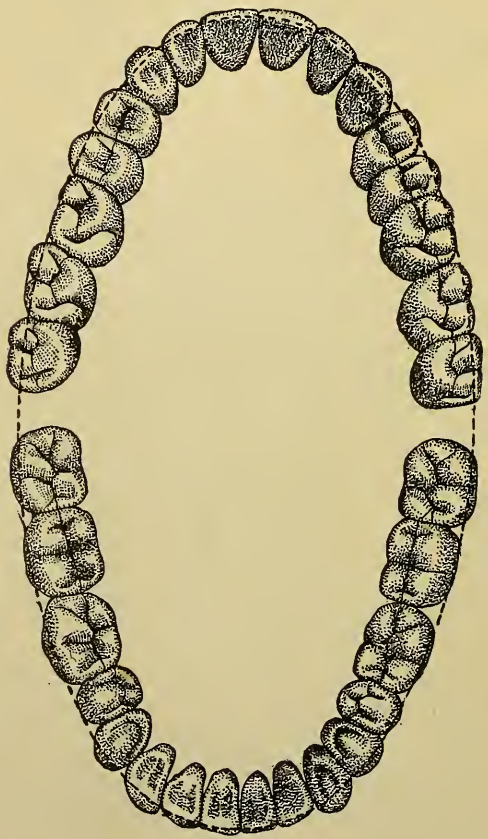

FIG. 153.

Occlusal surfaces of teeth. ("Descriptive Anatomy of the Human Teeth," *G. V. Black, M.D., D.D.S., Sc.D.*)

series; roots may be the typical three, or these may be fused more or less completely into one, or there may be supernumerary roots.

Mandibular (lower) first and second incisors; very similar to maxillary second incisor, but more slender; incisal edge of first incisor is almost at a right angle to the long axis of the

tooth: its mesio- and disto-incisal angles are sharp; second incisor differs from the first by possessing an incisal edge curving at the distal angle and sharp at the mesial: roots, slender, flattended mesiodistally, oval in cross-section, with long axis labiolingually.

Mandibular canine; markedly similar to maxillary canine, slightly smaller, crown a little longer; root shorter, somewhat flattened mesiodistally, nearly straight.

Mandibular first premolar; smallest of the premolars; buccal and lingual cusps, latter almost absent, neck much constricted.

FIG. 154.

Cross sections through roots of teeth *in situ*. Actual size. ("Descriptive Anatomy of the Human Teeth," *G. V. Black, M.D., D.D.S., Sc.D.*)

Mandibular second premolar; very similar to above tooth; slightly longer; lingual cusp more marked; root, longer, larger, generally straight.

Mandibular first molar; next to maxillary first molar the largest; outline of occlusal surface trapezoidal; buccal margin the longest; five-cusped (three buccally, two lingually); mesiobuccal cusp largest; two roots, one mesial, one distal; former the larger, oval in cross-section, contains two root canals; distal root, oval in cross-section, one root canal.

Mandibular second molar; strikingly different from the first in absence of distal (distobuccal) cusp; in all other respects great similarity.

Mandibular third molar; two typical forms: (1) four-cusped, similar to mandibular second molar (the more common

form); (2) five-cusped, similar to mandibular first molar. From these types great variation in size and form. On the whole smaller than the two teeth immediately mesial to it; typically two roots, relatively smaller than other molar roots, single root also common; three roots not infrequent; however, always three root-canals, two mesial and one distal.

The anatomy of the teeth, apart from their occlusal topography, may be epitomized as follows: Incisors, canines and premolars; all one root with exception of maxillary first premolar, which has two. Maxillary molars; three roots. Mandibular molars; two roots. Incisors have a straight cutting edge; canines and premolars have a mesial and a distal slant; mesial slant the shorter, except that the mesial slant of first maxillary premolar is the longer. Mesiobuccal angle, acute. Roots bend distally; mesial root the longer.

Occlusion.—Maxillary teeth bite to the outside of the mandibular teeth; the buccal cusps of the mandibular premolars and molars fit into the mesiodistal groove of the corresponding maxillary teeth; maxillary canine locks between mandibular canine and first premolar. Every tooth in the human denture opposes two teeth of the occluding set, except the mandibular first incisor and maxillary third molar.

The point, or, better, the *surface,* of proximate contact is that area on the mesial and distal surface of a tooth which apposes a corresponding surface of the adjoining tooth. Each tooth thereby receives mutual support from two adjoining teeth, except the four third molars, which have only on their mesial sides these surfaces of proximate contact.

Distribution	Termination and Function

CRANIAL NERVES.

Sömmering	Superficial Origin	Deep Origin	Exit	Divisions	Distribution	Termination & Function
1. Olfactory.	Three roots { Short, Middle, Long.	Short, anterior lobe. Middle— gray { caruncula. mamillaris. white, corpus striatum. Long, anterior commissure and exterior white substance of the optic thalamus.	**Foramina of the cribriform plate of ethmoid bone.**	The bulbus olfactorius sends off three groups of filaments. { Inner, Middle, Outer.	Inner group—nasal septum. Middle group—roof of nasal fossa. Outer group—superior and middle turbinated bones.	Schneiderian mucous membrane of the nose. Nerve of special sense of smell.
2. Optic.	Optic commissure, formed by the tracti optici. These portions are connected with the crus and tuber cinereum.	Optic thalami, corpora geniculata, corpora quadrigemina.	**Optic foramen.**	Passes as single trunk through the sclerotic and choroid coats, a little to nasal side of centre.	**Expands to form the inner layer of the retina of the eye.**	In the retina after receiving a sheath from the dura mater at the optic foramen. Nerve of special sense of sight.
3. Motor oculi.	Inner side of crus close to the pons Varolii.	Nucleus in floor of aqueduct of Sylvius.	**Sphenoidal between two heads of rectus externus muscle.**	In the external wall of the cavernous sinus divides into two branches—superior, and inferior.	**Superior—to the superior rectus and levator palpebræ muscles.** **Inferior** { **1st branch—to inferior rectus muscles.** **2d branch—to internal rectus muscles.** **3d branch—to the lenticular ganglion and inferior oblique muscle.**	In the muscles mentioned. Nerve of motion
4. Pathetici (trochleares).	Valve of Vieussens around the outer side of crus cerebri.	Aqueduct of Sylvius, floor of fourth ventricle.	Sphenoidal fissure.	**In the cavernous sinus it sends branches to ophthalmic nerves, cavernous plexus of sympathetic and a recurrent branch to the tentorium cerebelli.**	To the superior oblique or trochlearis muscle. Enters muscle on its *orbital* side.	In the superior oblique muscle. Nerve of motion (*smallest* cranial nerve).
5. Trifacial (trigemini).	From sides of pons Varolii by two roots—anterior or motor, posterior or sensory. Opposite the internal auditory meatus the sensory root enters the Gasserian ganglion. The motor root passes beneath and, later, joins a branch of the ganglion.	Sensory root, from lateral tract of the medulla oblongata. Motor root, from the pyramidal body.	Ophthalmic division through sphenoidal fissure. Superior maxillary division through foramen rotundum. Inferior maxillary division through foramen ovale.	Ophthalmic— Branches { Lachrymal. Frontal { Supratrochlear. Supraorbital. Nasal. Nasal { Ganglionic. Ciliary. Infratrochlear. Superior maxillary, three groups— Spheno-max. fossa { Orbital { Temporal. Malar. Spheno-palatine. Posterior deotal. Infraorbital canal—Ant. dental. On the face { Palpebral. Nasal. Labial. Inferior maxillary, two divisions— Anterior, principally motor fibres. Posterior, principally sensory fibres. Auriculo-temporal { Communicating branches. Two auricular. Gustatory { Communicating branches. Branches of distribution. Inferior deotal { Mylo-hyoid. Dental.	Lachrymal gland, conjunctiva, integument of upper eyelid. Corrugator supercilii, occipito-frontalis, integument of forehead. [cranium. Corrugator supercilii, orbicularis palpebrarum, occipito-frontalis, integument of cranium, peri- Mucous membrane of nose, integument of wings and tip of nose. Ciliary ganglion. Ciliary muscle and iris. Integument of eyelids and nose, orbicularis palpebrarum, caruncula lachrymalis, lachrymal sac, conjunctiva. Integument of temple and side of forehead. Joins facial nerve. Two branches to spheno-palatine ganglion. Anterior branch to gums and bucinator muscle; posterior branch to molar and second bicuspid teeth, antrum, and gums. Incisor, canine, and first bicuspid teeth and inferior meatus Orbicularis palpebrarum, conjunctiva and integument of lower eyelids. Muscles and integument of inner side of nose. Labial glands, muscles, integument, and mucous membrane of upper lip. To the muscles of mastication the branches are: temporal (deep), buccal, masseteric, pterygoid. Facial nerve and otic ganglion—two branches to the meatus, branches to parotid gland. To integument of the ear, temporo-maxillary articulation. Communicating with submaxillary ganglion and hypoglossal nerve. Supply the papillæ and mucous membrane of tongue, mucous membrane of mouth, gums, communicating at tip of tongue with the hypoglossal nerve. Upper surface of the mylo-hyoid muscle, anterior belly of the digastric muscle. Molar and bicuspid teeth.	In muscles. Nerve of motion. (The trifacial is the largest of the cranial nerves.) Nerve of special sense of taste Nerve of motion. Nerve of common sensation.
6. Abducentes.	Pyramidal body and pons Varolii.	Posterior part of medulla and floor of fourth ventricle.	Sphenoidal fissure.	Passes in one trunk to—	The external rectus muscle.	In external rectus muscle. Nerve of motion.
7. Facial.	Lateral tract, medulla, and pons Varolii.	Floor of fourth ventricle.	Internal auditory meatus, facial canal, and stylomastoid foramen.	Branches *before* its exit are— Tympanic, Chorda tympani. Branches *at* its exit— Posterior auricular, Digastric, Stylo-hyoid. Branches *after* its exit— Temporo-facial { Temporal, Malar, Infraorbital. Cervico-facial { Buccal, Supramaxillary, Inframaxillary.	To the stapedius and laxator-tympani muscles. Communicates with and accompanies the gustatory nerve to the submaxillary gland. Joins submaxillary ganglion. To muscles of tongue. Retractens aurem, occipito-frontalis (occipital portion). Posterior belly of digastric, filament to glosso-pharyngeal nerve. Stylo-hyoid muscle, communicates with sympathetic or carotida. Attrahens aurem, occipito-frontalis (frontal portion), orbicularis palpebrarum. Orbicularis, corrugator supercilii, lower eyelid. Superficial branches to skin and muscles of face, up branches levator muscles of mouth. Buccinator and orbicularis oris muscles. Platysma, muscles of chin and lip, depressors of angle of mouth. Platysma. One branch joins the superficial cervical nerve.	In muscles. Nerve of motion. Nerve of facial expression.
8. Auditory.	Winds around the restiform body.	White striæ in floor of fourth ventricle.	Internal auditory meatus.	{ Cochlear. { Vestibular.	Cochlea. Vestibule and semicircular canals.	Internal ear. Nerve of special sense of hearing.
9. Glosso-pharyngeal.	Three or four filaments from the medulla posterior to the olivary body.	Gray nucleus in floor of fourth ventricle.	Jugular foramen in a sheath of its own and in front of the pneumogastric and spinal accessory. Two ganglia—ganglion of the root, ganglion of nerve.	Tympanic (Jacobson's), Carotid, Pharyngeal, Muscular, Tonsillar, Lingual.	Distributed to fenestra rotundum, fenestra ovalis, tympanum, Eustachian tube, communicating with greater superficial petrosal, carotid plexus, otic ganglion. Trunk of internal carotid artery, communicates with pneumogastric and sympathetic. Mucous membrane of pharynx. Stylo-pharyngeus muscle. Tonsil, soft palate, and fauces. One branch to mucous membrane surface and base of tongue; one branch to mucous membrane and papillæ of sides of tongue.	In mucous membrane and muscle. Nerve of special sense of taste. Nerve of motion. Nerve of common sensation.
10. Pneumogastric (vagus).	About a dozen filaments immediately *below* the origin of the glosso-pharyngeal.	Gray nucleus in floor of fourth ventricle.	Jugular foramen in a common sheath, with the spinal accessory. Two ganglia—ganglion of the root, ganglion of nerve.	In jugular fossa—Auricular. In neck { Pharyngeal, Superior laryngeal, Recurrent laryngeal, Cervical cardiac. In thorax { Thoracic cardiac, Anterior pulmonary, Posterior pulmonary. Œsophageal. In abdomen—Gastric.	(Arnold's) communicates with auricular branch of facial. To integument of Pinna. With a filament from spinal accessory to pharyngeal plexus on middle constrictor. Mucous membrane of interior of larynx and arytenoideus muscle. Exterior laryngeal nerve, to superior constrictor, crico-thyroid muscles, branch pharyngeal plexus. To all muscles of larynx except the crico-thyroid. Two or three branches to cardiac plexuses; inferior cardiac branch to deep plexus on right; superficial cardiac plexus on left. To deep cardiac plexus. Anterior pulmonary plexus. Posterior pulmonary plexus. Plexus gulæ, around the œsophagus. Stomach, communicating with solar, splenic, and hepatic plexuses.	In muscles, mucous membrane, vessels, gland (thyroid). Nerves of motion, sensation, and sympathy.
11. Spinal accessory.	By filaments from spinal cord as low as sixth cervical vertebræ; accessory portion from lateral tract.	Accessory portion from gray nucleus in floor of fourth ventricle.	Enters skull by foramen magnum; exit by jugular foramen in sheath with pneumogastric.	Accessory portion. Spinal portion.	Sends communicating branches to pharyngeal and superior laryngeal branches of the pneumogastric. To sterno-mastoid, trapezius, cervical plexus, occasionally great auricular nerve.	In muscles. Nerve of motion.
12. Hypoglossal.	About a dozen filaments from the space between the pyramidal and olivary bodies.	Gray nucleus in floor of fourth ventricle.	Anterior condyloid foramen.	{ Descendens noni, Thyro-hyoid, Muscular, Communicating.	Omo-hyoid (both bellies), sterno-hyoid, sterno-thyroid. Thyro-hyoid muscle. Styeloglossus, hyoglossus, genio-hyoid, genio-hyoglossus. With pneumogastric, sympathetic, first and second cervical and gustatory nerves.	In muscles. Nerve of motion.

INDEX.

Abdomen, 232
  muscles of, 143
  regions of, 234
Acervulus cerebri, 315
Acetabulum, 81
Alveoli of lower jaw, 36
  of upper jaw, 31
Amphiarthrosis, 105
Anastomoses, 174
Anatomy, descriptive, 1
  dental, 409
  general, 1
  of hernia, 396
  of lateral lithotomy, 407
  of teeth, 422
  surgical, 391
Angle of jaw, 37
Anterior perforated space, 306
Annulus ovalis, 171
  of subscapular fossa, 65
Antrum of Highmore, 29, 413
  relation of roots of teeth to, 413
Anus, 244
Aorta, 178, 193
Appendicies epiploicæ, 244
Appendix auriculæ, 170, 172
  ensiform, 52
  vermiformis, 243
Aponeuroses, 129
  pharyngeal, 230
Apophysis, 4
Aqueduct of Sylvius (iter e tertio, etc.), 299
Aqueductus cochleæ, 18
  fallopii, 18, 328
  vestibule, 18
Arachnoid, of brain, 297
  of spinal cord, 331
Arbor vitæ, 290, 285
Arch, deep palmar, 192
  plantar, 202
Areola of mammæ, 292
Arm, 63
Arnold's ganglion, 352
Arteriæ propriæ renales, 268
Arterial anastomoses, 174
  system, table of, 202
Arteries, helicine, 280
  hepatic, 194, 249
  lingual, 180
  pharyngeal, 183
  sublingual, 180, 181
Arteries of the ankle-joint, 125
  auditory canal, 361, 376
  auricle, 376
  bone, 5
  choroid, 363
  elbow-joint, 123
  Eustachian tube, 379
  eye, 371
  eyelids, 372
  hip-joint, 120
Arteries of the iris, 364
  kidney, 268
  knee-joint, 121
  labyrinth, 382
  larynx, 259
  lung, 263
  mammæ, 292
  membrana tympani, 380
  nasal fossæ, 356
  nose, 355
  œsophagus, 193
  ovaries, 284
  pancreas, 246
  penis, 280
  pharynx, 230
  retina, 368
  shoulder-joint, 116
  spleen, 251
  stomach, 240
  suprarenal capsules, 253
  testicle, 278
  thymus gland, 252
  thyroid gland, 252
  tympanum, 380
  uterus, 284
  wrist-joint, 118
Artery, anastomotica magna, 191, 200
  aorta, 178, 193
  arteria receptaculi, 185
  auricular, posterior, 183
  axillary, 190
  basilar, 188
  brachial, 191
  carotid, common, 179
    external, 180
    internal, 185
  carotid (external), 180
  (internal), 185
  cerebral, anterior, 186
    middle, anterior, 186
    posterior, 186
  choroid, anterior, 186
  circumflex, anterior, 189, 191
    posterior, 191
  communicating, anterior, 186
    posterior, 186
  coronary, 178, 179
  dental, inferior, 184
  digital, 193, 202
  dorsalis, hallucis, 201
    pedis, 201
  epigastric, deep, 198
    superficial, 199
  facial, 181
  gastric, 194
  femoral, 199
  gluteal, 198
  hæmorrhoidal, inferior, 197
    middle, 197
    superior, 195
  hepatic, 194
  Iliac, circumflex, deep, 198

Artery, iliac, common, 196
external, 196, 198
internal, 194, 196
superficial, 199
ilio-lumbar, 198
infraorbital, 185
innominate, 179
intercostal, 189
lingual, 180
lumbar, 195
mammary, internal, 189
maxillary, internal, 183
meningeal, anterior, 185
middle, 184
posterior, 188
small, 184
mesenteric, superior, 194
inferior, 195
obturator, 197
occipital, 181
ophthalmic, 185
palmar arches, 192
peroneal, 202
pharyngeal, ascending, 183
phrenic, 194
plantar, external, 202
internal, 202
popliteal, 200
profunda femoris, 199
inferior, 191
superior, 191
pudic, deep external, 199
superficial external, 199
internal, 197
pulmonary, 208
radial, 191
renal, 195, 268
sacral, lateral, 198
middle, 196
sciatic, 197
spermatic, 195
splenic, 194
subclavian, 187
subscapular, 190
suprarenal, 195
suprascapular, 189
temporal, 183
thoracic, acromial, 190
alar, 190
long, 189, 190
superior, 190
thyroid, inferior, 187
superior, 180
thyroidea ima, 252
tibial, anterior, 200
posterior, 201
transveralis colli, 189
tympanic, 184
ulnar, 192
uterine, 198
vaginal, 198
vertebral, 188
vesical, 196
Arthrodial joints, 105
Articulations, 104
acromioclavicular, 115
atloaxoid, 107
carpal, 119
carpometacarpal, 119
costosternal, 108
costotransverse, 108
costovertebral, 108
glenohumeral, 116
occipitoatloid, 107
Articulations, occipitoaxoid, 107
phalangeal, of foot, 127
of hand, 120
radioulnar, 117
sacrococcygeal, 111
sacroiliac, 110
sacroischiatic, 110
sacrovertebral, 110
sternoclavicular, 114
tarsal, 125
tarsometatarsal, 126
temporomaxillary, 105
tibiofibular, 123
vertebral, 106
Arytenoid cartilages, 254
Atlas, 58
Auricle, 376
Axilla, 395
Axis, 44, 58
cerebrospinal, 296
celiac, 194
optic, 358
thyroid, 188
visual, 358
Aaxis cylinder, 295
Azygos veins, 215
uvulæ, 136

Bartholin, duct of, 230
glands of, 292
Bauhin, valve of, 243
Bell, external nerve of, 336
internal nerve of, 336
Bladder, 270
Bodies, Malpighian, 268
Pacchionian, 297
geniculate, 311
restiform, 299
Body, ciliary, 363
olivary, 299
pituitary, 306
restiform, 299
Bone, astragalus, 93
calcaneum, 93
clavicle, 63
coccyx, 63
cuboid, 93
cuneiform, 78, 94
ethmoid, 24
femur, 86
fibula, 92
frontal, 8
humerus, 70
ilium, 82
incus, 380
hyoid, 38
innominate, 81
ischium, 84
lachrymal, 26
malar, 27
malleus, 380
maxillary, inferior, 35
superior, 29
nasal, 27
occipital, 12
os calcis, 93
os magnum, 78
palate, 32
parietal, 10
patella, 89
peroneal, 92
phalanges of foot, 96
of hand, 79
pisiform, 78

Bone, pubic, 85
radius, 74
sacrum, 61
scaphoid, 77, 94
scapula, 65
semilunar, 78
sessamoid, 98
sphenoid, 20
stapes, 380
sternum, 52
structure, microscopic, 5
temporal, 15
tibia, 90
trapezium, 78
trapezoid, 78
turbinated, inferior, 34
middle, 25
superior, 25
ulna, 72
unciform, 78
vomer, 35
Bones of the body, 3
of the carpus, 76
of the cranium, 8
of the face, 26
of the foot, 93
of the hand, 76
of hard palate, 409
of the lower extremity, 81
of the metacarpus, 76
of the metatarsus, 96
of oral cavity, 409
of the tarsus, 93
of the trunk, 52
of the upper extremity, 63
Wormian, 40
Bonnet, capsule of, 360
Bowman, capsule of, 268
Brain, commissures of, 308
development, 298
divisions of, 298
ventricles, 308
weights, average, 298
Bronchi, 259
Brown stria of Retzius, 417
Brunner's gland, 242
Buccinator, 412
in artificial dentures, 412
Bulb of corpus cavernosum, 280
of corpus spongiosum, 280
Bulbi vestibuli, 291
Bulbs, olfactory, 323
Burns, process of, 402
Bursæ of hip, 121
of knee, 122

Cecum, 243
Calamus scriptorius, 313
Calices of kidney, 268
Canal, alimentary, 223
auditory external, 376
internal, 18, 387
carotid, 18
central, of the cord, 332
crural, 400
dental, 30
femoral, 400
for tensor tympani, 379
Hunter's, 199
hyaloid, 369
infraorbital, 30
inguinal, 396
nutrient, 5
of Huguier, 378
Canal of Nuck, 237
of Petit, 369
of Schlemm, 364
of Stilling, 269
of the modiolus, 384
palatine, 31
pterygopalatine, 24
sacral, 61
spiral, of the cochlea, 384
Vidian, 24
Canaliculi, 374
Canalis reuniens, 385
Canals, membranous, 385
semicircular, 383
Canthus, 373
Capillaries, 175
Capsule, external, 310
internal, 310
of Bonnet, 360
of Glisson, 246
of Tenon, 360
of the lens, 369
Capsules, suprareual, 252
Caput coli (cecum), 243
gallinaginis, 281
Carpus, 76
Cartilages of the larynx, 254
of Santorini, 255
of Wrisberg, 255
tarsal, 373
Cartilagotriticea, 255
Caruncula lachrymalis, 373
myrtiformes, 289
Cauda equina, 332
Cavity, cotyloid, 81
glenoid, of scapula, 68
orbital, 42
peritoneal, 235
preoral, 412
sigmoid, greater, 72
lesser, 74
of radius, 74
Cells, auditory, 387
ethmoid, 25
hepatic, 246
of Purkinje, 318
mastoid, 17, 378
Cement, 226
Cerebellum, 301, 318
Cerebrospinal system, 295
Cerebrum, 302, 320
convolutions of, 305
fissures of, 303
lobes of, 304
Cervix of penis, 279
of uterus, 293
Chordæ tendinæ, 173
Choroid plexus, 310
Cilia, 373
Circle of Willis, 186
Circulus arteriosus iridis, 364
venosus, 292
Cisterna basolis, 297
magna, 297
pontis, 297
Claustrum, 310
Clavicle, 63
Cleft palate, 409
Clinoid processes, 21
Clitoris, 290
Clivus Blumenbachii, 21
Cloquet, canal of, 369
Coccyx, 63
Cochlea, membranous, 386

Cochlea, osseous, 383
Cœliac axis, 194
Collar-bone, 63
Colon, 243
  flexures of, 243
Columnæ carneæ, 173
  papillares, 173
Columns of spinal cord, 332
Commissures, cerebral, 308
  anterior, 308
  middle, 308
  posterior, 308
Concha, 376
Condyles of femur, 88
  of humerus, 71
Coni vasculosi, 274
Conjunctiva, 373
Conus arteriosus, 172
  medullaris, 332
Convolutions of cerebrum, 305
Coracoid process, 68
Corium, 389
Cornea, 361
Cornicula laryngis, 255
Cornua of thyroid cartilage, 254
  of ventricles, 308
Corona glandis, 279
Coronoid process, 37
Corpora albicantia, 306
  cavernosa, 280
  quadrigemina, 314
  mammillaria, 306
  striata, 310
Corpus Arantii, 172
  callosum, 305
  dentatum of cerebellum, 316
  fimbriatum, 311
  Highborianum, 274
  luteum, 286
  spongiosum, 280
  striatum, 310
Corpuscles, Malpighian, 251, 268
  of the blood, 175
  tactile, 296
Corti, organ of, 387
Cortical substance of kidney, 267
Cotyloid cavity, 81
Coverings of the testicle, 273
Cowper's glands, 282
Crest, lachrymal, 26
  nasal, 31
  of the ilium, 82
  of the pubes, 85
  of the tibia, 90
  turbinated, 31
Cribriform tube, 410
Cricoid cartilage, 254
Crista galli, 24
  terminalis, 170
Crown, 415
Crura, anterior, 311
  cerebri, 306
  of clitoris, 290
  of penis, 280
  posterior, 311
Crusta petrosa, 226
  pontis, 316
Crypts of Lieberkühn, 242
Cuneiform cartilages, 255
Cuneus, 305
Cupola of cochlea, 386
Cuticle, 389
Dartos, 273
Declivity, 21
Deciduous teeth, 414, 415, 418
Dental anatomy, 409
  papillæ, 415
  ledge, 415
Dentine, 226, 415
Derma, 389
Descemet, membrane, 362
Diaphragm, 146
Diaphragma, sella, 296
Diaphysis, 3
Diarthrosis, 105
Digestion, orgaus of, 223
Discus proligerus, 286
Disk, optic, 367
Dorsum of scapula, 49, 65
  sellæ, 21
Douglas cul-de-sac, 237, 284
Duct, cystic, 250
  hepatic, 250
  lymphatic, 219
  nasal, 375
Duct of Bartholin, 230
  of Müller, 276, 288
  of Rivini, 230
  of Steno, 229
  of Wharton, 229
  of Wirsung, 246
  paucreatic, 246
  thoracic, 219
Ducts, biliary, 250
  ejaculatory, 278
Ductus cochlearis, 373
  communis choledochus, 250
Duodenum, 240
Dura mater of cerebrum, 296
  of spinal cord, 332

Ear, 375
  internal, 382
Earstones, 386
Embryology of oral cavity, 409
  of teeth, 415
  of lower jaw, 409
Eminentia articularis, 15
  collateralis (pes accessorius), 312
Enamel, 226, 416
Enarthrosis, 105
Encephalon, 298
Endocardium, 173
Endolymph, 356
Endosteum, 5
Epidermis, 389
Epididymis, 273, 274
Epigastric region, 234
Epiglottis, 254
Epiphysis, 3, 4
Epethelial sheath of Hertwig, 418
Equator of eyeball, 358
Eruption of deciduous teeth, 415
  of permanent teeth, 416
Eustachian tube, 379
Eye, 356
  appendages of, 372
Eyebrows, 372
Eyelashes, 372
Eyelids, 373

Fallopian tubes, 287
Fallopius, aqueduct of, 18
  hiatus of, 18
Falx cerebelli, 296
  cerebri, 296

Fascia, abdominal, 166
cremasteric, 274
cribiform, 168
denta, 312
iliac, 167
intercolumnar, 274
lata, 168
lumbar, 166
obturator, 404
of Colles, 404
of the head and face, 166
of the lower extremity, 168
of the neck, 166
of the trunk, 166
of the upper extremity, 167
palmar, 167
pelvic, 167
perineal, 404
plantar, 169
rectovesical, 404
Fasciæ, 165
Fauces, 228
Femus, 86
Fenestra ovalis, 378
rotunda, 378
Ferrein, pyramids of, 268
Fibrocartilage, 101, 106, 124, 254
Fibula, 92
Fillet, decussation of, 320
mesial, 320
lateral, 320
Fimbriæ, 288
Fimbriated extremity, 288
Fissure, auricular, 19
calcarine, 304
callosomarginal, 304
collateral, 304
dentate, 304
Glaserian, 16
of Rolando, 304
of Sylvius, 304, 306
palpebral, 375
paracentral, 304
parieto-occipital, 304
pterygomaxillary, 41
sphenomaxillary, 40
sphenoidal, 23, 43
transverse, 304
Fissures of cerebellum, 301
of cerebrum, 303
of liver, 247
of spinal cord, 332
Floor of the mouth, 413
Fetal circulation, 176
Folds, palpebral, 375
Fontanelles, 59
Foot, 93
Foramen for Arnold's nerve, 19
cæcum, 9
condyloid, 13, 48
ethmoidal, 21, 46
for Jacobson's nerve, 19
infraorbital, 24, 46
inferior dental, 410
intervertebral, 56
lacerum anterius, 24, 44
magnum, 13, 50
mastoid, 16
medium, 46
mental, 36, 410
malar, 41
nutrient, 5
obturator, 81
of Monro, 312
Foramen of Scarpa, 31
of Stenson, 31
of Winslow, 235
olfactory, 46
orbital, 24
ovale, 23
palatine, 31
posterius, 13
pterygopalatine, 22
rotundum, 23
sacral, 62
sphenopalatine, 32
spinal, 57
spinosum, 23
stylomastoid, 19
supraorbital, 8, 46
suprascapular, 67
thyroid, 81
Vesalii, 23
Foramina at the base of the skull 46
of hard palate, 409
of mandible, 410
Thebesii, 171
Forearm, 72, 149
Formatio reticularis, 316
Fornix, 311
Fossa, canine, 29
caronoid, 71
digastric, 17
digital, 88
glenoid, 16, 68
hyaloid, 369
incisive, 29
infraspinous, 66
ischorectal, 402
jugular, 18
lachrymal, 9
navicularis of penis, 281
of vulvo, 289
oleeranon, 71
ovalis, 171
pituitary, 21
pterygoid, 24
scaphoid, 24
sphenomaxillary, 44
sublingual, 36
submaxillary, 36
subscapular, 66
supraspinous, 66
temporal, 40
zygomatic, 40
Fossæ, nasal, 45
of the skull, 40
Fourchette, 290
Fovea centralis, 367
hemispherica, 383
semielliptica, 383
Frenulum, 314
Frenum lobii, 411
in relation to artificial dentures, 412
preputii, 280

Gall-bladder, 250
Gall-duct, 250
Ganglia, 295
basic, 311
cervical, 352
cranial, 350
lumbar, 353
of fifth nerve, 350
of the sympathetic, 350
sacral, 353
thoracic, 353

Ganglion, Arnold's, 352
Gasserian, 350
impar, 350
Meckel's, 350
of Ribes, 350
ophthalmic, 350
otic, 352
sphenopalatine, 350
spirale, 385
submaxillary, 352
Gasser, ganglion of, 350
Geniculate bodies, 311
Ginglymus, 105
Gingival trough, 411
Gladiolus, 52
Gland, lachrymal, 374
mammary, 292
parotid, 229
pineal, 315
prostate, 282
sublingual, 230
submaxillary, 229
thymoid, 252
thymus, 252
Glandula coccygea, 253
Glandula intercarotica, 253
Glands, Brunner's, 242
Cowper's, 282
ductless, 250
gastric, 239
intestinal, 242
lachrymal, 373
lymphatic, 219
Meibomian, 373
of Bartholine, 292
of Tyson, 279, 292
peptic, 240
salivary, 229
sebaceous, 390
solitary, 242
sweat, 390
Glans clitoridis, 290
penis, 278
Glenoid, 16, 68
Glisson's capsule, 246
Glottis, 255
Gomphosis, 105, 414
Graafian vesicle, 286
Groove, bicipital, 70
carotid, 21
cavernous, 21
infraorbital, 31
musculospiral, 70
mylohyoid, 36
nasopalatine, 35
optic, 21
Gubernaculum testis, 274
Gums, 224, 411
Gyri of brain, 305

Hairs, 390
Hamstrings, 160
Hamular process, 26
Hand, 76
Hare-lip, 409
Hard palate, 409
sutures of, 409
foramina of, 409
bones of, 409
Haversian canals, 6
system, 6
Head of the femur, 86
of the humerus, 70
of the ulna, 72
Heart, 170
Helicotrema, 385
Helix, 376
Henle, tubes of, 268
Hernia, anatomy of, 396
femoral, 400
inguinal, 396
Hiatus Fallopii, 18
Hirlus of kidney, 266
Hippocampus major, 312; minor, 312
His, bundle of, 171
Histogenesis of dental tissues, 416
of enamel, 416
of dentin, 416
of cement, 416
Hasner, valve of, 375
Houston, valves of, 245
Huguier, canal of, 16
Humerus, 70
Humor, aqueous, 368
vitreous, 368
Humors of the eyeball, 368
Hunter's canal, 199
Hydatids of Morgagni, 276, 288
Hymen, 288
Hypochondrium, 234
Hypogastrium, 234

Ileum, 241
Ilium, 82
Incisura intertragica, 376
Incisal pad, 411
Infundibulum of brain, 306
Inguinal regions, 234
Intestine, large, 242
small, 240
Internal capsule, 310
Iris, 363
Ischium, 84
Iter chordæ anterius, 378
posterius, 378
e tertio ad quartum ventriculum 313
Ivory, 226

Jacob's membrane, 368
Jacobson's nerve, 3,16, 336, 365
Jejunum, 241
Joint, ankle-, 124
elbow-, 116
hip-, 120
rotators of the, 159
knee-, 121
shoulder-, 114
wrist-, 118
Joints, motions in, 105
structures of, 104

Kidneys, 266

Labia majora, 290
minora, 290
Labium tympanicum, 386
vestibulare, 386
Labyrinth, membranous, 385
osseous, 383
Lacteals, 219
Lacuna magna, 282
Lacunæ, 6
Lacus lachrymalis, 373
Lamellæ, 6
Lamina cinerea, 306
cribrosa (of sclerotic), 361
(of temporal bone), 18

Lamina fusca, 361
reticularis, 387
spiralis, 384
Laminæ of cornea, 361
Lancisi, nerves of, 308
Larynx, 254
Layer, dermoid, 389
ganglionic, 367
molecular, 367
Leg, 90
Lens, crystalline, 368
Lieberkühn, crypts or follicles of, 242
Ligament, annular, of foot, 168
of hand, 167
chondroxiphoid, 109
conoid, 115
coronary, 121
cotyloid, 121
crucial, of knee-joint, 122
deltoid, 124
falciform, 401
Gimbernat's, 143, 398, 400
glenoid, 116
ileofemoral or Y, 121
of Burns, 402
of Colles, 398
of Hey, 381
of Zina, 353, 369
orbicular, 118
Poupart's, 143, 146, 398, 400
periodontal, 418
rhomboid, 114
round, of the liver, 249
of the uterus, 285
sacrosciatic, 110
stellate, 108
stylomaxillary, 106
suspensory, of lens, 369
of liver, 249
of penis, 280
of spleen, 250
transverse, of hip-joint, 121
trapezoid, 115
triangular, of perineum, 404
Ligaments of the bladder, 271
broad, of uterus, 285
cheek, 107
of the knee-joint, 121
of the larynx, 255
of the liver, 248
of the ossicles, 381
of the ovaries, 285
of the sternum, 109
of the uterus, 284
peritoneal, 236-237
tarsal, 373
Ligamentum latum pulmonis, 264
mucosum, 128
nuchæ, 106
patellæ, 121
pectinatum iridis, 363
suspensorium, 108
teres, 121
Winslowii, 121
Limbus laminæ spiralis, 385
Line, intertrochanteric, 88
Linea-aspera, 86
iliopectinea, 84
quadrati, 88
Lingula, 21
Liquor Morgagni, 369
Lithotomy, structures affected, 407
Liver, fissures of, 247
ligaments, 249
Liver, lobes of, 248
structure of, 246
vessels of, 249
Lobes of the cerebellum, 301
of the cerebrum, 302
of the liver, 248
Lobule of the ear, 375
Lobules of the liver, 246
of the lung, 262
Lobulus caudatus, 246
quadratus, 246
Spigelii, 246
Lower, tubercle of, 171
Lumbar regions, 234
Lung, broad ligament of, 264
Lungs, 261
Lymphatics, 219
hepatic, 222, 249
of lung, 263
of penis, 281
of trachea and bronchi, 260
of uterus, 284
Lymph spaces of eyeball, 360
Lyra, 311

Macula acoustica, 385
cribrosa, 383
lutea, 367
Malleolus, 92
Malpighi, bodies of, 251
pyramids of, 267
Malpighian corpuscles, 251, 268
tuft, 268
Mammæ, 292
Mandible, 410
Mandibular, canine, 421
fifth cuspid, 422
first incisor, 420
first molar, 421
first premolar, 421
fourth cuspid, 421
second incisor, 420
second molar, 421
second premolar, 421
third molar, 421
Manubrium of the malleus, 380
of the sternum, 52
Marrow of bone, 5
Masses, lateral, of ethmoid, 24
Mastoid process, 16
Maxillary, canine, 419
first, 419
first molar, 419
first premolar, 419
second, 419
second molar, 419
second premolar, 419
third molar, 420
Meatus auditorius externus, 18
internus, 18, 387
nasi, 45
urinarius, 281, 291
Meckel's ganglion, 350
Mediastinum, 264
testis, 274
Medullar, 5
oblongata, 299, 315
Medullary sheath, 294
substance, 266
Membrana basillaris, 386
granulosa, 286
præformativa, 416
pupillaris, 364
Ruyschiana, 362

Membrana tectoria, 387
tympani, 380
secundaria, 362
Membrane, hyaloid, 369
interosseous, 119, 120, 124
Jacob's, 367
limiting, 367
of Descemet, 364
Nasmyth's, 415, 417
of Reissner, 387
Schneiderian, 356
Shrapnell's, 378
vitelline, 286
Membranes of brain, 296
of the spinal cord, 332
synovial, 104
tarsal synovial, 126
wrist synovial, 120
Meridians of eyeball, 359
Mesencephalon, 314
Mesenteries, 236
Metacarpus, 80
Metatarsus, 96
Midbrain, 318
Modiolus, 384
Monro, foramen of, 312
Mons veneris, 290
Montgomery, glands of, 292
Morgagni, hydatids of, 276, 288
liquor, 369
Mouth, 223
Müller, duct of, 276, 288
Muscle, ciliary, 364
cremaster, 274
dilator pupillæ, 364
levator glandulæ thyroideæ, 251
of the auricle, 376
sphincter pupillæ, 365
Muscles of the abdomen, 143
of Hilton, 258
of Houston, 405
of the arm, 148
of the back, 138
of the ear (external), 129
of the epiglottis, 258
of expression, 412
of the Eustachian tube, 379
of the eyeball, 369
of the face, 120
of the forearm, 149
of the foot, 163
of the hand, 153
of the head, 129
of the hip, 155
of the larynx, 257
of the leg, 160
of mandible, 414
of mastication, 413
of the neck, 133
of the palate, 135
of the perineum, 407
of the pharynx, 135
of the shoulder, 147
of the stomach, 239
of the thigh, 156
of the thorax, 145
of the tongue, 135
of the tympanum, 382
Muscular fiber, 128
floor of mouth, 413
Musculi pectinati, 172

Naboth ovules of, 284
Nasmyth's membrane, 415, 417
Nails, 390
Nares, 45
Nates of cerebrum, 314
Neck of femur, 88
of humerus, 70
muscles of, 133
triangles of, 391
Nerve, abducens, 326
Arnold's, 330
auditory, 328
Bell's external respiratory, 336
internal respiratory, 334
cells, 295
chorda tympani, 328
circumflex, 336
cochlear, 328
crural, anterior, 340
facial, 326
fibers, 295
genitocrural, 339
glossopharyngeal, 330
gluteal, superior, 340
hypoglossal, 331
iliohypogastric, 339
ilioinguinal, 339
intercostal, 339
intercostohumeral, 340
internal cutaneous, 337
interosseous, 337, 338
Jacobson's, 330, 382
laryngeal, 259, 330
maxillary inferior, 326
superior, 325
median, 337
motor oculi, 324
musculocutaneous, 337
musculospiral, 338
nouus or ninth pair, 330
obturator, 340
of Wrisburg, 337
olfactory, 323
ophthalmic division of fifth, 325
optic, 323
par vagum, 330
patheticus, 325
petrosal, external, 351
large deep, 351
large superficial, 351
small, 351
popliteal, 341
phrenic, 334
pneumogastric, 330
pterygopalatine, 351
pudic, 341
radial, 338
sciatic, great, 341
small, 341
spinal accessory, 331
subscapular, 336
suprascapular, 336
sympathetic, 350
tibial, anterior, 342
posterior, 341
thoracic, 336
trigeminus, 325
trochlear, 325
tympanic, 328
ulnar, 337
vestibular, 328
Vidian, 351
Nerve-fibers, optic, 323
tissue, 295
Nerves, 295
cranial, 323

Nerves, hepatic, 354
of ankle-joint, 125
of auditory canal, 377
of auricle, 376
of bladder, 273
of choroid, 363
of elbow-joint, 117
of Eustachian tube, 380
of eye, 372
of eyelids, 372
of eye-muscles, 369, 370, 371
of hip-joint, 121
of iris, 364
of Jacobson, 330
of kidney, 270
of knee-joint, 123
of Lancisi, 308
of larynx, 259, 330
of lung, 263
of membrana tympani, 380
of nasal fossæ, 356
of nose, 356
of pulp, 418
of ovaries, 287
of pancreas, 246
of pharynx, 230
of shoulder-joint, 115, 117
of spleen, 251
of stomach, 240
of suprarenal capsules, 253
of taste, 389
of testicles, 278
of thymus gland, 252
of tongue, 389
of trachea and bronchi, 260
of tympanum, 378
of uterus, 284
of wrist-joint, 119
petrosal, 351
popliteal, 341
sciatic, 341
spinal, 332
splanchnics, 353
table of, 343
thyroid, 252
Nervous system, 294
Newman, sheath of, 418
Neurilemma, 294
Neuroglia, 295
Neuron, 295
Nipple, 292
Nose, 355
Notch, cotyloid, 81
interclavicular, 41
intercondyloid, 71
popliteal, 60
Rivinus, 378
sacrosciatic, 84, 85
sigmoid, 37
supraorbital, 8
suprascapular, 67
Nuck, canal of, 237
Nucleus, red, 318
Nymphæ, 290

Occipital cross, 18
protuberance (external), 12
(internal), 14
Occulsion, 422
Odontoblasts, 225, 416
Odontoid ligaments, 107
process, 59
Œsophagus, 221
Omentum, 235
Opening saphenous, 168, 401
Optic thalami, 311
Ora serrata, 365
Orbital cavities, 49
Organ of Corti, 387
of hearing, 375
of Rosenmüller, 287
of sight, 356
of smell, 355
Organs of generation, female, 283
male, 273
of taste, 389
of voice and respiration, 254
urinary, 266
Os calcis, 93
orbiculare, 381
planum (orbital of ethnoid), 24
tincæ, 284
uteri, 284
Ossa innominata, 81
triquetra, 40
Ossification, 7
table of, 99
Ossicles of tympanum, 380
Osteology, 3
Otoliths, 386
Ovaries, 285
Oviducts, 286
Ovisacs, 286
Ovules of Naboth, 284
Ovum, 286

Pacchionian bodies, 297
Palate, 228
Palpebræ, 373
Pampinaform plexus, 277, 287
Pancreas, 245
lesser, 245
Papilla lachrymal, 374
Papillæ of skin, 389
Parovarium, 287
Pars cillaris retinæ, 367
intermedia, of vulva, 290
Peduncles of cerebellum, 302
of corpus callosum, 305, 306
Pelvic girdle, 81
Pelvis, 112
of the kidney, 267
Penis, 278
Perforated space, anterior, 306
posterior, 306
Pericardium, 170
Perilymph, 385
Perineum, 403
female, 407
central tendon of, 406
Periosteum, 5
Peridontal ligament, 418
Peritoneum, 235
Permanent teeth, 415, 416, 418
Peronei muscles, 163
Pes accessorius, 312
hippocampi, 312
Petit, canal of, 369
Peyer's patches, 242
Phalanges of ear, 370
of foot, 96
of hand, 80
Pharynx, 230
Pia mater of brain, 297
of spinal cord, 331
of the testes, 274
Pinna, or auricle, 376
Pituitary body, 253, 306

Plane, equatorial, 358
meridional, 358
Plantar arch, 169
Plate, cribriform, 24
perpendicular, 24
pterygoid, 24
Pleuræ, 264
Plexus, brachial, 336
cardiac, 353
carotid, 352
cavernous, 352
cervical, 334
choroid, 310
of fourth ventricle, 310
hypogastric, 354
lumbar, 339
pampiniform, 277, 287
pelvic, 354
sacral, 340
solar, 354
splenic, 354
tympanic, 380
Plexuses of the sympathetic, 353
Plica semilunaris, 373
Point, nodal, 358
Poles of the eyeball, 358
Pomum Adami, 254
Pons Varolii, 300, 316
Portal system, 193, 215, 249
Porus opticus, 361
Pouches of membrana tympani, 378
Poupart's ligament, 143, 398, 400
Prism stripes of Schreger, 417
Preoral cavity, 412
Prepuce of clitoris, 291
of penis, 279
Process, acromion, 68
alveolar, 31, 36, 410
angular, 8
articular, 104
auditory, 20
basilar, 14
clinoid, 21
condyloid, 37, 72
coracoid, 68
coronoid, 37, 72
enamel, 416
ethmoidal, 34
falciform, 401
hamular, of cochlea, 384
Ingrassias, 23
jugular, 13
lachrymal, 34
malar, 31
mastoid, 17
maxillary, 28, 33, 34
mental, 35
nasal, 31
odontoid, 59
of pterygoid plate of sphenoid, 23
olecranon, 71
olivary, 21
orbital, 28, 33
of Tomes, 416
palate, 30
pterygoid, 23, 33
sphenoidal, 33
spinous, 4, 23, 56
styloid, 19
transverse, 57
unciform, 25
vaginal, 19, 22
vermiform, 243
zygomatic, 15, 28
Processes, ciliary, 364
clinoid, 21
of Ingrassias, 23
Processus, cochleariformis, 20
a cerebello ad medullam (inferior peduncles), 302
ad potem (middle peduncles), 302
ad testes, 302, 315
gracilis, 380
Prominentia canalis facialis, 379
Promontory of sacrum, 61
of tympanum, 378
Prostate gland, 282
Prostatic sinus, 281
urethra, 281
Pterygoid processes, 23, 33
Pubes, 85
Punctum, lachrymale, 373
Pulp, 415, 418
arteries, nerves, lymphatics of, 418
Pupil, 363
Pylorus, 238
Ppramid, anterior, 299
posterior, 299
of tympanum, 378
Pyramids of Ferrein, 268
of Malpighi, 267
of Wistar, 22

Radius, 74
Rami of inferior maxillary, 36
Ramus of ischium, 85
of the pubes, 85
Receptaculum chyli, 220
Rectum, 244
Regions of abdomen, 234
Reil, island of, 304
Reissner, membrane of, 387
Renal vessels, 268
Retina, 365
Ribes, ganglion of, 350
Ribs, 52
Ridge, mylohyoid, 36
pterygoid, 23
superciliary, 8
Rima glottidis, 257
oris, 412
Ring, abdominal, 398
crural, 400
femoral, 400
Rivinus, duct of, 230
Rugae, 411
Rods and cones (Jacob's), 367
of Corti, 381
Rolando, fissure of, 304
Rosenmüller, organ of, 287
Rostrum of the sphenoid, 22

Sac, lachrymal, 375
Saccule, 385
Sacculus, laryngis, 257
Sacrum, 61
Sacs of the peritoneum, 235
Santorini, cartilages of (corniculo laryngis), 255
Scala media, 386
tympani, 385
vestibuli, 385
Scapula, 65
Scarpa, foramen of, 31
Schindelysis, 105
Schlemm, canal of, 364
Schwann, substance of, 294

Sclerotic, 361
Scrotum, 273
Scute, 379
Sella turcica, 21
Septum, crurale, 401
lucidum, 310
nasi, 45
pectiniforme, 280
Sheath, crural, 401
Schreger, prism stripes of, 417
Sharpey's fibers, 417
Sheath of Newman, 418
Shin, 90
Shoulder-joint, 116
blade, 65
girdle, 63
Sight, organs of, 356
Sigmoid flexure, 244
Sinus aortici or sinus of Valsalva, 173
circularis iridis, 364
of kidney, 267
of Morgagni (sacculus laryngis), 257
pocularis, 281
Sinuses, frontal, 10
of the dura mater, 210
of Valsalva, 173
sphenoidal, 22
Skin, 389
Smell, organ of, 355
Space, anterior perforated, 306
popliteal, 396
posterior perforated, 306
of Retzius, 271
subarachnoid, 297
subdural, 297
Spermatic cord, 276
Sphincter vesicæ, 271
Spinal cord, 332
nerves, table of, 343
Spine, ethmoidal, 21
nasal anterior, 27
of the ischium, 84
of the pubes, 85
of the scapula, 66
of the sphenoid, 23
of the tibia, 90
pharyngeal, 14
posterior, 32
Spines of the ilium, 84
Spinous processes, 4, 23, 56
Spleen, 250
Splenic flexure of colon, 244
Splenium, 306
Spot, blind, 347
germinal, 286
light, 365
yellow, 380, 365
Squamous, 15
Steno's ducts, 229
Stenson's foramina, 31
Sternum, 52
Stilling, canal of, 369
Stomach, 238
Styloid, 19
Substance, gray, 294
of Schwann, 294
medullary, 266
white, 294
Substantia gelatinosa Rolandi, 316
nigra, 318
Sulci, 303
Sulcus spiralis, 386
tympanicus, 377
Suprarenal capsules, 252
Surface, articular, 104
trochlear, 71
Sustentaculum tali, 93
Sutura, 39
Suture, basilar, 39
coronal, 39
intermaxillary, 39
lachrymoethmofrontal, 39
lambdoidal, 39
masto-occipital, 39
mastoparietal, 39
petro-occipital, 39
petrosphenoidal, 39
sagittal, 39
sphenoparietal, 39
squamoparietal, 39
squamosphenoidal, 39
zygomatic, 39
Sutures, facial, 39
of the orbit, 43
of the skull, 39
of hard palate, 409
Sylvius, fissure of, 304, 306
Sympathetic system, 335
Symphysis pubis, 85
of inferior maxillary, 29
Synarthrosis, 105
Synovial membranes, 104

Tarsus, 93
Taste, nerves of, 389
Taste goblets, 389
Tenit hippocampi, 311
semicircularis, 310
Teeth, 224, 415, 416
Tendo-oculi, 360
Tendons, 128
Tenon, capsule of, 360
Tentorium cerebelli, 296
Testes, 273
of the cerebrum, 315
descent of, 276
Thebesius, foramina of, 171
Thigh, 86
Thorax, 109
Thyroid axis, 188
cartilage, 254
gland, 251
Tongue, 388
Tonsils, 228
Trachea, 259
Tract, lateral, 388
optic, 306, 323
Tracts, olfactory, 306, 323
Tractus spiralis foraminulentus, 387
Tragus, 375
Triangle, Hesselbach's, 400
Trigonum urogenitale, 404
vesicæ, 272
Trochanters of femur, 88
Trochlea, 71
Tube, Eustachian, 379
Tuber annulare (pons Variolli), 287,303
cinereum, 306
Tubercle, 4
genial, 36
lachrymal, 31
of Lower, 171
of tibia, 90
Tuberosities, 4
of femur, 88
of humerus, 70
of ischium, 85

Tuberosities, maxillary, 31
Tubes of Henle (convoluted tubes), 268
spiral, of Schachowa, 268
Tubuli lactiferi, 292
seminiferi, 274
uriniferi, 268
Tuft, Malpighian, 268
Tunica adventitia, 174
albuginea, 274
intima, 174
media, 174
Ruyschiana, 362
vaginalis, 274
vasculosa, 274
Tunics of eyeball, 360
Tutamina oculi, 356
Tympanum, 378
Tyson, glands of, 279, 292

Ulna, 72
Umbilical region, 234
Umbilicus, 234
Umbo, 380
Urachus, 271
Ureters, 270
Urethra, 281, 291
bulb of, 281
Uterus, 283
masculinus, 281
Utricle, 281, 385
Uvea, 363
Uvula, 228
vesicæ, 272

Vagina, 288
Valley of cerebellum, 301
Valsalva, sinuses of, 173
Valve, Eustachian, 171
Hasner, 375
ileocecal, 243
mitral, 173
of Baulin, 243
of Vieussens, 313
pyloric, 239
semilunar, 173
tricuspid, 172
Valves of Kirkring (valvulæ conniventes), 241
semilunar, 172, 173
Valvulæ conniventes, 241
Vas aberrans, 276
deferens, 276
Vasa efferentia, 276
recta, 276
vasorum, 174
Vein, axillary, 214
basilic, 214
cephalic, 214
cerebral, 211
cerebellar, 211
femoral, 218
iliac, 217
median, 214
popliteal, 218
portal, 215
radial, 214
splenic, 215
subclavian, 213
suprarenal, 215
ulnar, 214
vertebral, 216
Veins, 174
azygos, 215
cardiac, 209
Veins, choroid, 211
hepatic, 215
iliac, 216, 217
innominate, 213
interlobular, 249
jugular, external, 212
internal, 210
of bone, 5
of Galen, 312
of head and neck, 211
of lower extremities, 218
of esophagus, 215
of suprarenal capsules, 215
of thymus, 252
of trachea and bronchi, 261
of the eye, 372
of the kidney, 268
of the larynx, 259
of the lung, 263
of the pancreas, 246
of the penis, 281
of the stomach, 240
of the thorax, 214
pulmonary, 218
saphenous, 218
spinal, 216
thyroid, 213
uterine, 284
without valves, 174
Velum, anterior medullary, 314
interpositum, 311
Vena cava, superior, 209
inferior, 215
Venæ comites, 174
propriæ renales, 268
rectæ, 268
vorticosæ, 337
Venter of the ilium, 84
of the scapula, 65
Ventricle of the cord, 332
fifth, 315
fourth, 313
of the larynx, 257
third, 312
Ventricles, lateral, 308
Vertebra prominens, 59
Vertebræ, 56
Verumontanum, 281
Vesalii, foramen, 23
Vesical, germinal, 286
Graafian, 286
Vesiculæ seminales, 278
Vestibule, 291
of the ear, 383
Vidian canal, 24
nerve, 351
Vieussens, valve of, 314
Villi, 241
Viscera, covered by peritoneum, 237
partially, 237
wholly, 238
Vitellus, 286
Vocal cords, 257
Vomer, 35
Vortex of heart, 173
Vulva, 290

Walls of the tympanum, 378
Wharton's ducts, 229
Whorl of heart, 173
Willis, circle of, 186
Wings of the sphenoid, 23
Winslow, foramen of, 235
ligament of, 121

Wirsung, duct of, 246
Wistar, pyramids of, 22
Wormian bones, 40
Wrisberg, cartilages of, 255
nerve of, 337

Zinn, zonula of, 369
Zona pellucida, 286
Zonula of Zinn, 369
Zygoma, 15, 28

Date Due

9/10/29			
2/1/30			
[illegible]			
11-10-53			

MAR 20 1918

QM28 Y8
Young 11917
cop. 1

Handbook of Electrons

5/2

H. F. Frosch

7/5

9/8

D. Kerman

M. Astrachan

1/10 1-15

DUPLICATE
HX00011410